



Is ultrasound diagnosis reliable in acute extensor tendon injuries of the knee ?

Girish N. SWAMY, Shashi K. NANJAYAN, Sachin YALLAPPA, Amit BISHNOI, Simon A.W. PICKERING

From Royal Derby Hospital, Derby, UK

Ruptures of the patellar and quadriceps tendon are rare injuries requiring immediate repair to re-establish knee extensor continuity and allow early motion. Ultrasound is extensively used as a diagnostic tool before surgery on acute traumatic tears of the patellar tendon and quadriceps tendons.

The aim of our study was to evaluate the role of sonography in diagnosing quadriceps and patellar tendon rupture and in differentiating partial from complete tears.

We conducted a retrospective review of 51 consecutive patients who had a surgical intervention for suspected acute quadriceps and patellar tendon rupture over a 5-year period. Intra-operative findings were compared with pre-operative clinical examination. Radiographs, ultrasound and MRI reports were reviewed.

On clinical examination, 22 patients had a suspected patellar tendon rupture and 29 patients had a suspected quadriceps tendon rupture.

Diagnosis was confirmed by clinical examination and plain radiographs alone in 13 patients, with additional ultrasound performed in 24 patients and MRI scan performed in 14 patients.

There were 8 false positives out of 24 [33.3%] in the ultrasound proven group and 1 false positive out of 13 [7.69%] in the clinical examination and radiographs only group. MRI was 100% accurate.

We conclude that ultrasonography is not a reliable method in establishing the diagnosis of acute injuries to the extensor mechanism of the knee, particularly the quadriceps tendon ruptures in the obese and the very muscular patients.

If there is clinical ambiguity, MRI scan is a better investigation tool before undertaking surgical treatment.

Keywords : quadriceps tendon : patellar tendon : ultrasonography : MRI : reliability ; false positive.

INTRODUCTION

Traumatic ruptures of the quadriceps and patellar tendon are rare injuries (10,11,14) and can be misdiagnosed (11,43). More commonly, complete or partial ruptures occur as a result of chronic degenerative changes or overuse injury (8). Numerous predisposing factors have been cited including gout, rheumatoid arthritis, diabetes mellitus and patellar spur (4,15,13). Also, these patients may be obese or muscular athletes with a history of steroid abuse.

-
- Girish N. Swamy, MRCS, Specialist Registrar in Orthopaedics.
 - Shashi K. Nanjayan, MRCS, Orthopaedic Registrar.
 - Sachin Yallappa MRCS, Clinical Fellow.
 - Amit Bishnoi MRCS, Orthopaedic Registrar.
 - Simon A.W. Pickering FRCS (Orth), MD, Consultant Orthopaedic Surgeon.
Orthopaedic department, Royal Derby Hospital, Derby, UK.
Correspondence : Girish N. Swamy, No 1, Courtway Crescent, Chellaston, Derby, DE73 5TS.
E-mail : girishjam@yahoo.com
© 2012, Acta Orthopædica Belgica.

Various diagnostic modalities including clinical examination and special tests (6), radiographic evidence (7,12), ultrasound (2,3) and Magnetic Resonance Imaging (MRI) have been used in establishing a diagnosis. In acute ruptures, ultrasonography has been relied upon as a fast and accurate diagnostic tool (5,10). Though MRI represents a highly sensitive method for visualisation of tendon ruptures, it is considered more expensive and less available (5).

Acutely treated ruptures offer a more favourable outcome and adequate end-to-end surgical repair is important for early mobilisation and prevention of residual deformity leading to loss of function (4,9, 11,12,16). After a number of anecdotal reports suggesting that ruptures had been over-diagnosed by ultrasonography, we looked at our experience over a 5 year period. The aim of this study was to evaluate the role of sonography in diagnosing quadriceps and patellar tendon rupture and in differentiating partial from complete tears.

PATIENTS AND METHODS

Fifty one consecutive patients who underwent surgical exploration for a suspected extensor mechanism injury of the knee between 2006 and 2011 were reviewed. The patient demographics (to include the age, body weight and BMI, medical co-morbidities), clinical history, radiological investigations and clinical findings at surgery were noted from the medical records. Patients underwent surgical exploration and repair. The diagnosis was based on clinical findings that included a palpable gap, absent straight leg raise and effusion, along with standard radiographic findings and in patients with a clinically ambiguous diagnosis, further investigation with ultrasonography or MRI scan was performed. The choice of further investigation was based on surgeon's preference and anecdotal experience.

Radiographic investigation included an antero-posterior (AP) and a lateral radiograph of the knee joint. Ultrasound examination was performed using a Logiq 9 machine (GE) with a 4D 16L transducer. All ultrasound examinations were performed and reported by a consultant radiologist with an interest in musculoskeletal radiology. All MRI scans were performed using a 1.5 T GE or Phillip scanner with extremity coil for the knee and reported by consultant radiologists. All the surgical

explorations were performed by consultant surgeons or a senior trainee under supervision.

We used binary logistic regression analysis to evaluate the relationship between age, gender, BMI and co-morbidities. All statistical tests were performed at a 0.05 alpha level of significance.

RESULTS

During the 5-year study period, 46 patients with 51 suspected quadriceps or patellar tendon ruptures underwent surgical treatment. All patients had acute injuries with a mode presentation of 3 days (range : 0-7 days) from the onset of injury. Football injury and knee giving way spontaneously were the commonest mechanism of injury.

Thirty five patients were males with 22 suspected patellar tendon ruptures and 29 suspected quadriceps tendon ruptures. The mean age was 41 years in the patellar tendon group and 56 years in the quadriceps tendon group (Table I). Surgical exploration with a view to repair the extensor tendon rupture was based on clinical examination and radiological findings only in 13 patients.

Ultrasound scan results in 24 patients and the MRI scan results in 14 patients were used as an adjunct to diagnosis before surgery.

There was no statistical significant difference between the three groups [clinical, ultrasound and MRI] in the demographic data.

In the clinical diagnosis group (n = 13), 7 patients had a suspected quadriceps tendon rupture and 6 patients had a suspected patellar tendon rupture. In one patient with a suspected quadriceps tendon rupture, surgical exploration revealed an intact tendon.

Out of 24 patients who had a positive ultrasound report, 16 patients were diagnosed with a quadriceps rupture preoperatively, but at surgery 7 patients (43.7%) had continuity of the quadriceps tendon. Eight patients were diagnosed with a patellar tendon rupture preoperatively, but at surgery one patient had an intact tendon (Fig. 1).

Overall, 8 (33.3%) out of 24 had an intact extensor mechanism noted at surgery in the ultrasound group. All 14 (100%) patients with an MRI diagnosis of rupture of the extensor tendon of the

Table I. — Demographic data of all patients with a clinical suspicion of an extensor tendon injury of the knee

Suspected rupture	Total number	Males	Age in years Range (mean)	Diabetes mellitus	Previous knee pain /surgery	Commonest mechanism of injury	Palpable gap	Active Straight Leg raise	Ultrasound	MRI
Quadriceps tendon	29	19	39-97 (56)	8	9	Knee gave way	7	4	16	6
Patellar tendon	22	16	20-83 (41)	3	14	Football injury	6	0	8	8

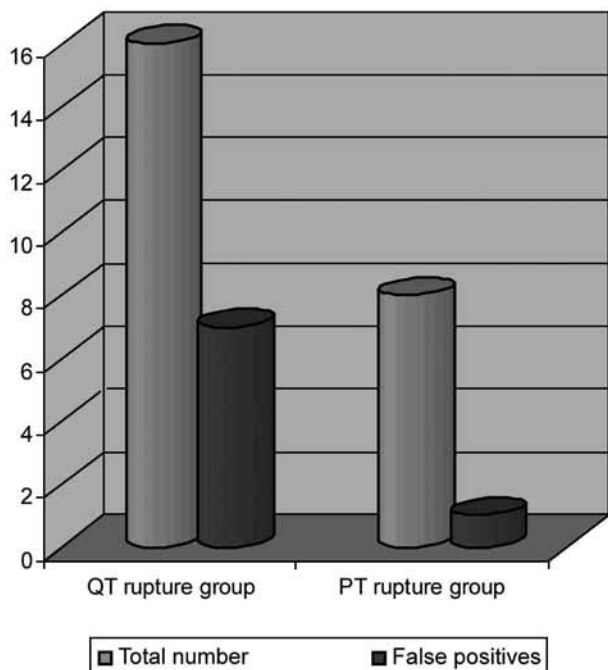


Fig. 1. — Cylinder column chart of the ultrasound group. Surgery demonstrated intact tendon continuity in 44% (7/16) with ultrasonography reported quadriceps tendon rupture and in 12.5% (1/8) with reported patellar tendon rupture.

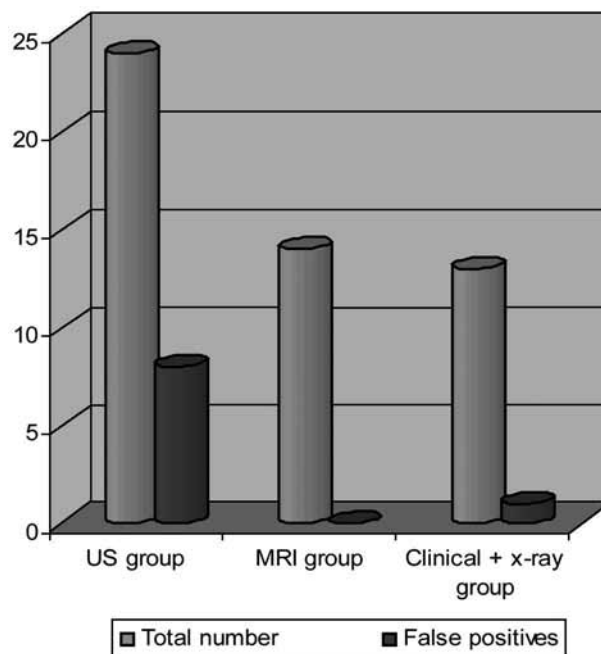


Fig. 2. — Cylinder column chart demonstrating different investigative modalities and number of false positive results at surgical exploration. Ultrasound group = 8/24; MRI group = 0/14 and clinical plus x-rays group = 1/13. Comparison between the groups showed a significant difference [$p < 0.005$].

knee showed similar intra-operative findings to that reported (Fig. 2) with a significant statistical difference compared to the ultrasound group.

DISCUSSION

In our retrospective study with 51 suspected extensor mechanism injuries of the knee, ultrasonography was the preferred diagnostic tool (47%)

followed by diagnosis based on MRI scans and clinical examination [with radiographs].

To our knowledge, this is the first study to directly question the reliability of ultrasonography in diagnosing acute extensor tendon ruptures of the knee.

Clinical examination is still widely used in establishing the diagnosis of these acute ruptures and some of the features include pain, impaired ability

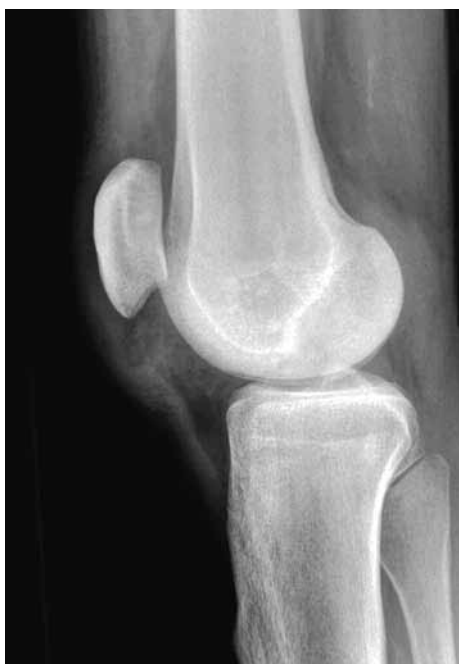

Fig. 3. — Lateral radiograph of a 34-year-old male presenting with hearing a pop in the knee while walking downhill. There is evidence of a large knee effusion with a high riding patella suggestive of a patellar tendon rupture but the diagnosis was missed in initial examination in the emergency department.

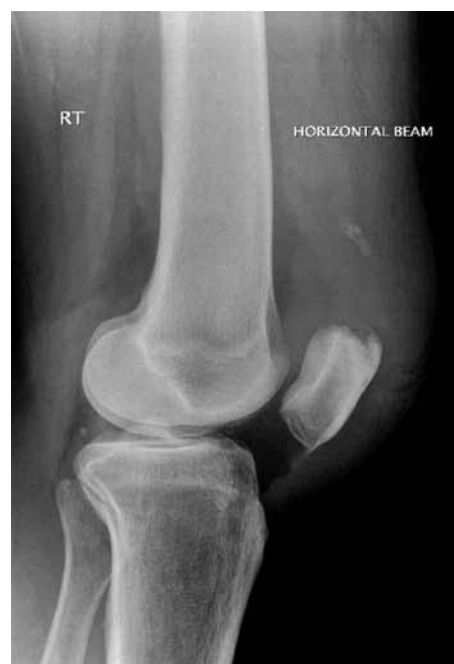

Fig. 4. — A 58-year-old male presented with tripping on ice. There is a very large suprapatellar joint effusion. Note was made of an area of calcification proximal to the patella. This was reported to be an osteochondral body within the suprapatellar joint capsule or an area of calcification within the quadriceps tendon as a result of previous injury. The calcification appears well rounded and may not represent an acute avulsion, but a subsequent MRI scan proved otherwise.

to actively extend the knee and a palpable gap. Despite the clinical signs, misdiagnosis is frequent and reported as ranging from 39% to 67% (7,17). Diagnostic examination may be limited by a large haemarthrosis, active inhibition of movements and preservation of a straight leg raise with use of intact medial and lateral retinaculum or the iliotibial band. As a result, the traumatic rupture of quadriceps tendon is often overlooked. After finding stable cruciate and collateral ligaments, and radiographic absence of a fracture, the patient may be diagnosed and treated as a knee sprain by an inexperienced examiner (15). In addition, partial tendon ruptures and chronic ruptures are more difficult to evaluate thoroughly on physical examination due to absence of palpable gap, and the extensor function, although uncomfortable, may be intact (18).

Plain radiograph is the most common initial investigation for knee injuries. Findings suggestive

of tendon rupture include joint effusion, a poorly defined suprapatellar mass, calcific densities and presence of a bony fragment in case of osseous tear-out of the tendon. The Insall-Salvati method for determining patella alta/inferior has also been used but these findings are not pathognomonic for the injury (Figs. 3, 4). They do not differentiate between complete and partial ruptures and these findings are frequently missed even by radiologists (7).

Ultrasound has been widely used as a diagnostic tool in extensor tendon ruptures around the knee (2). Criteria for rupture includes interruption of continuity, increased calibre of the proximal stump, hypo-echoic formation in the surrounding area as a sign of haematoma and no canalisation of the patella after contraction of the quadriceps muscle (Figs. 5, 6).

Among the limitations that diagnostic ultrasound has is its dependence on body habitus. Ultrasound

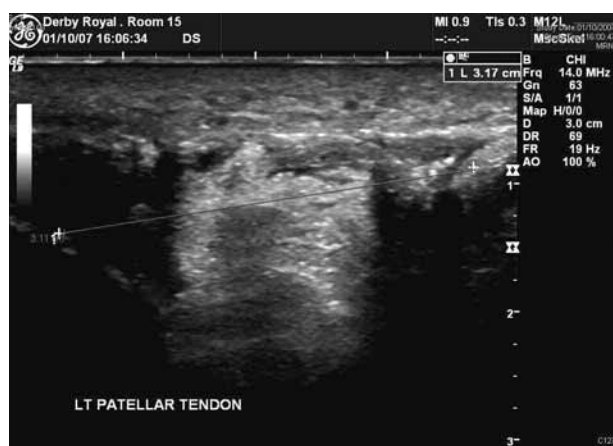

Fig. 5. — A 38-year-old male sustained a twisting injury while playing football. Longitudinal sonogram of the patellar tendon shows a detachment of the distal patellar tendon from the tibial tuberosity with a gap of approximately 3 cm. The arrow represents an artifact also referred to as anisotropy.

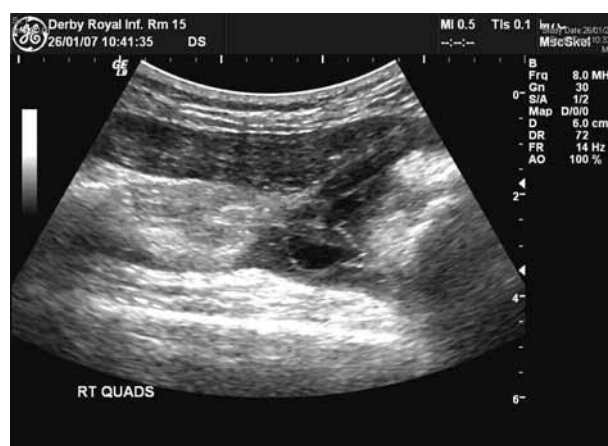

Fig. 6. — A 58-year-old male presented with his knee giving way. Longitudinal sonogram of the right quadriceps tendon shows a complete rupture as an anechoic defect of the quadriceps tendon with a large thigh haematoma extending up over vastus lateralis.

wave penetrance into tissue is inversely proportional to the wave frequency and with greater depth of penetrance, resolution can be sacrificed, limiting its use in obese or muscular patients.

Obesity and steroid abuse among athletes are well established risk factors for tendon injuries.

The accuracy of ultrasonography is also dependent on the experience of the investigator (5,10) and additional technical factors that affect ultrasound includes artefacts (referred to as anisotropy) that can mimic real pathology. Ultrasound relies on placing the transducer and hence the beam at a 90° angle to the structure being examined. Any deviance from this will result in the reflection of the beam away from the transducer, resulting in a reduction in the echogenicity (brightness) of the tissue being examined causing an artefact (Fig. 3). In addition, lack of joint movement due to pain may impede the ability to appreciate tendon translation across an area of abnormality and appearance of a tendon gap or retraction (Fig. 7).

MRI scan is now widely accepted as the method of choice for evaluation of tendons in other areas, particularly injured tendons (18). The quadriceps tendon is seen as a multi-layered structure showing a laminated configuration. Transection of all layers represents a complete rupture and partial ruptures are seen as focal disruptions of one or more layers,

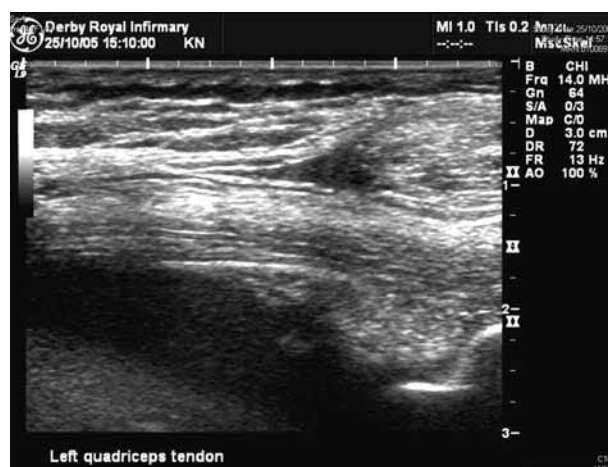

Fig. 7. — A 70-year-old female patient presented with knee giving way. This longitudinal sonogram was reported as follows : left quadriceps tendon appears deficient and lax at the superior pole of the patella. Some fluid is seen at the patella insertion and mixed sonoluent and turbid fluid is seen deep to the quadriceps tendon. This may represent a supra-patellar haematoma. The appearances were reported as indicative of a quadriceps tendon rupture but intra-operative findings showed intact tendon substance.

with other layers intact, also facilitating localisation to the specific tendon layer.

Assessment of quadriceps and patellar tendon is easily accomplished using sagittal images (Figs. 8,

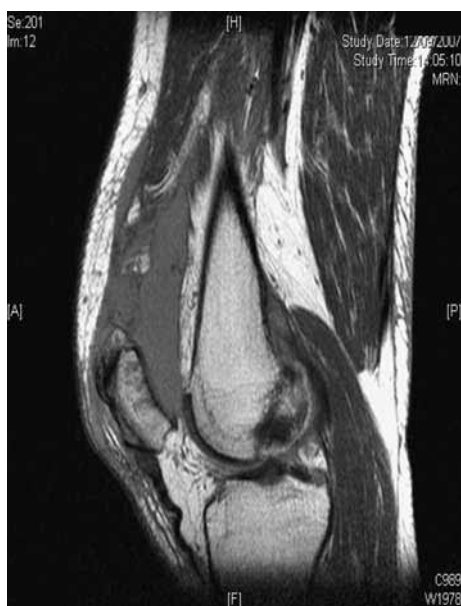

Fig. 8. — Proton density sagittal MR image of a 53-year-old male shows the three layered quadriceps tendon completely transected at the superior pole of the patella. The proximal tendon is completely retracted.

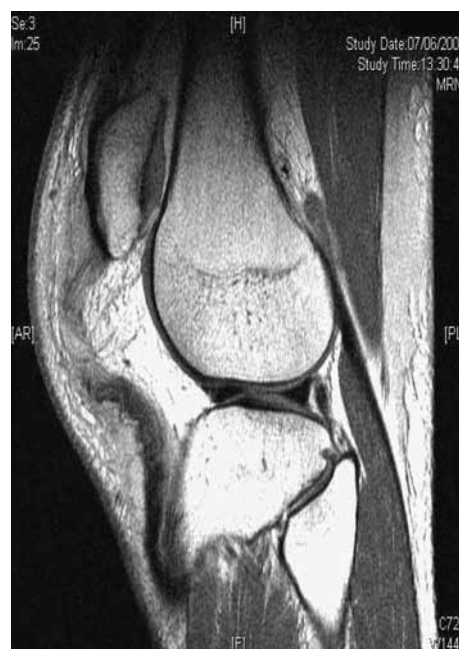

Fig. 9. — Proton density sagittal MR image of a 26-year-old footballer showing rupture of the patellar tendon from the lower border of the patella with displacement of the distal tendon and gross adjacent soft tissue swelling.

9). Classification of injuries can be accurately established with axial images or with GRE T2 sequences (1).

This is a retrospective study in a small cohort of patients. Nevertheless, several verbal reports from surgeons at different centres with a similar experience was echoed in clinical meetings. Extensor mechanism injuries of the knee are too rare and infrequent to contemplate prospective randomised studies. Surgical exploration in patients can lead to both clinical and legal complications. Multi-centre studies could be useful in evaluating the role of ultrasonography in diagnosing tendon injuries.

To conclude, ultrasonography may not be a reliable method in establishing the diagnosis of acute injuries to the extensor mechanism of the knee, particularly the quadriceps tendon ruptures in the obese and the very muscular patients.

It offers low specificity in quadriceps tendon ruptures. If there is clinical ambiguity, MRI scan may be a better investigative tool before undertaking surgical treatment.

REFERENCES

1. **Berquist TH.** *MRI of the Musculoskeletal System, 5th ed.* 2005 Lippincott Williams & Wilkins, Philadelphia, PA ISBN 0-7817-5502-6 ; p 259-260.
2. **Bianchi S, Zwass A, Abdelwahab IF, Banderali A.** Diagnosis of tears of the quadriceps tendon of the knee : value of sonography. *Am J Roentgenol* 1994 ; 162 : 1137-1140.
3. **Chung KL, Wong TT, Yuen MK, Kam CW.** Sonography of the quadriceps tendon ruptures. *Hong Kong J Emerg Med* 2004 ; 11 : 169-172.
4. **Hardy JR, Chimutengwende-Gordon M, Bakar I.** Rupture of the quadriceps tendon : an association with a patellar spur. *J Bone Joint Surg* 2005 ; 87-B : 1361-1363.
5. **Heyde CE, Mahlfeld K, Stahel PF, Kayser R.** Ultrasonography as a reliable diagnostic tool in old quadriceps tendon ruptures : a prospective multicentre study. *Knee Surg Sports Traumatol Arthrosc* 2005 ; 13 : 564-568.
6. **Jolles BM, Garofalo R, Gillain L, Schizas C.** A new clinical test in diagnosing quadriceps tendon rupture. *Ann R Coll Surg Engl* 2007 ; 89 : 259-261.
7. **Kaneko K, DeMouy EH, Brunet ME, Benzian J.** Radiographic diagnosis of quadriceps tendon rupture : analysis of diagnostic failure. *J Emerg Med* 1994 ; 12 : 225-229.

8. **Kelly DW, Carter VS, Jobe FW, Kerlan RK.** Patellar and Quadriceps tendon ruptures – Jumpers knee. *Am J Sports Med* 1984 ; 12 : 375-80.
9. **MacEachern AG, Plewes JL.** Bilateral simultaneous spontaneous rupture of the quadriceps tendons. Five case reports and a review of the literature. *J Bone Joint Surg* 1984 ; 66-B : 81-83.
10. **Mahlfeld K, Mahlfeld A, Kayser R, Franke J, Merk H.** Ultrasonography as a diagnostic tool in cases of quadriceps tendon rupture. *Ultraschall Med* 1999 ; 20 : 22-25.
11. **McGrory JE.** Disruption of the extensor mechanism of the knee. *J Emerg Med* 2003 ; 24 : 163-168.
12. **Neubauer T, Wagner M, Potschka T, Riedl M.** Bilateral, simultaneous rupture of the quadriceps tendon : a diagnostic pitfall ? Report of three cases and meta-analysis of the literature. *Knee Surg Sports Traumatol Arthrosc* 2007 ; 15 : 43-53.
13. **Newberg A, Wales L.** Radiographic diagnosis of quadriceps tendon rupture. *Radiology* 1977 ; 125 : 367-371.
14. **Ramseier LE, Werner CM, Heinzelmann M.** Quadriceps and patellar tendon rupture. *Injury* 2006 ; 37 : 516-519.
15. **Ramsey RH, Muller GE.** Quadriceps tendon rupture : a diagnostic trap. *Clin Orthop Relat Res* 1970 ; 70 : 161-164.
16. **Rougraff BT, Reeck CC, Essenmacher J.** Complete quadriceps tendon ruptures. *Orthopedics* 1996 ; 19 : 509-514.
17. **Siwek CW, Rao JP.** Ruptures of the extensor mechanism of the knee joint. *J Bone Joint Surg* 1981 ; 63-A : 932-937.
18. **Zeiss J, Saddemi SR, Ebraheim NA.** MR imaging of the quadriceps tendon : normal layered configuration and its importance in cases of tendon rupture. *Am J Roentgenol* 1992 ; 159 : 1031-1034.