



Beware the syndrome in neonatal hip instability : Follow up assessment is required after apparent resolution

Nick A. HEYWOOD, Robin W. PATON

From East Lancashire NHS Foundation Trust, UK

Developmental dysplasia of the hip is one of the most common congenital musculoskeletal disorders of childhood, affecting 1-3% of newborns. An early diagnosis and prompt treatment is essential to avoid complex treatments and achieve improved results. Since 1992, we have undertaken a screening programme for clinical instability and at risk patients. During this time, there have been only two cases which have been normal on both clinical, and, static and dynamic ultrasound assessment, that have subsequently deteriorated. In these two cases there was an underlying syndrome associated with hyperlaxity, which behaves unpredictably compared to 'true' developmental dysplasia of the hip.

In conclusion, if a hip has been referred as unstable but it is found to have a primary syndromal cause (especially if hyper lax) with sonographically normal hips at one to two weeks of age, it is best to review clinically and sonographically at 6 weeks and 3 months of age to confirm that the hip is maintaining stability.

Keywords : developmental hip dysplasia ; DDH ; syndromal cause.

INTRODUCTION

Developmental dysplasia of the hip (DDH) is one of the most common congenital musculoskeletal disorders of childhood affecting 1-3% of newborns (1). Those populations in which ultrasound (USS) examination has been used as a primary

screening test may see a prevalence between 34.0 and 60.3 per 1000. Most unstable hips will stabilise spontaneously within 3 weeks without treatment, however DDH underlies up to 9% of all primary hip replacements and up to 29% of those in people aged 60 years and younger (5). Delay in diagnosis means that more complex treatments with higher failure rates will be required, so early diagnosis and prompt, appropriate treatment are essential (15) with improved results seen in children under two years of age (17).

In the trust (Royal Blackburn Hospital), there are on average 3750 births per year with over 300 new neonates/infants diagnosed with clinically unstable hips (scanned between 1-2 weeks) or 'at risk' neonates (scanned between 6-9 weeks of age). All clinical examinations and USS in this screening programme have been undertaken by the senior orthopaedic surgeon since 1992 (12,13) and all cases are entered into a database. The following cases are

■ Nick Heywood, BMBS BMedSci, MRCS, Core Surgical Trainee.

■ Robin Paton, MBChB, PhD, FRCS (orthopaedic) Consultant Orthopaedic Surgeon & Honorary Senior Lecturer, University of Manchester.
East Lancashire Hospitals, NHN Trust.

Correspondence : Dr Nick Heywood, 71 Longfield, Fulwood, Preston, Lancashire, UK, PR2 9RN.

E-mail : nheywood@doctors.org.uk

© 2012, Acta Orthopædica Belgica.

*No benefits or funds were received in support of this study.
The authors report no conflict of interests.*

the only two which have been normal on both clinical, and static and dynamic ultrasound assessment, that have subsequently deteriorated since 1992. Although there were other cases of hip dysplasia requiring surgery the following cases were effectively the only false negatives and further investigation was warranted. The overall splintage rate (Pavlik harness) for hip instability or major hip dysplasia has been less than 0.4% (of the total birth population) over the last 20 years of screening.

CASE REPORTS

Case report 1

A female child born by emergency caesarean section for foetal bradycardia at 35 weeks and 5 days was referred by the neonatologist with a clinically unstable left hip (positive Ortolani manoeuvre) at birth. Antenatal ultrasound had demonstrated short limbs, and subsequent amniocentesis resulted in diagnosis of Turner's syndrome (mosaicism), with three abnormal cell lines, one of which had a single X chromosome with a small ring chromosome. The birth weight was 1650 grams (just above 0.4th centile), head circumference 29.1 cm (just above 0.4th centile) and length 38 cm (well below 0.4th centile) and examination revealed phenotypical features, with a small head, prominent ears, webbed neck and widely displaced nipples. She was admitted to the neonatal intensive care unit for 5 days due to transient tachypnoea and elevated haematocrit (73%) and required partial exchange transfusion. Initial echocardiogram revealed tricuspid regurgitation and a small functional patent ductus arteriosus had resolved in a subsequent follow-up scan a few weeks later.

On the one week initial review in the paediatric orthopaedic clinic, her hip was stable (negative Ortolani and Barlow manoeuvres) and ultrasound of the hips revealed an α -angle of 64° on the right and 67° on the left (Fig. 1) with no evidence of subluxation or dislocation on dynamic assessment. A further appointment was made 6 weeks later, but this was delayed until 10 weeks of age when the ultrasound demonstrated a subluxed left hip (α -angle of 66° on the right and 57° on the left (Fig. 2))

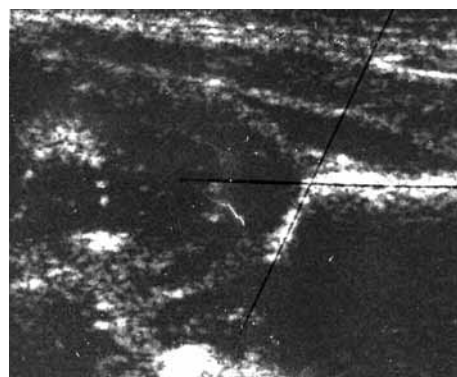


Fig. 1. — Case 1. Ultrasound scan of the left hip taken at one week of age showing no evidence of subluxation or dislocation on dynamic assessment and an alpha-angle of 67 degrees.

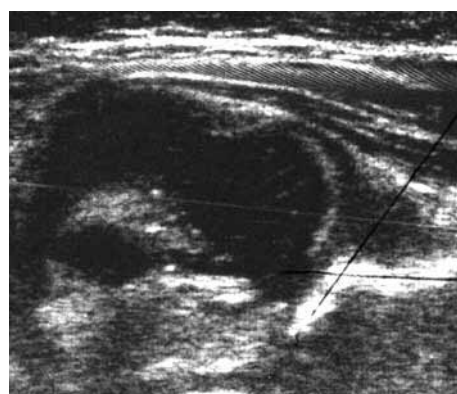


Fig. 2. — Case 1. Ultrasound scan of the left hip taken at 10 weeks old showing a subluxed left hip and an alpha-angle of 57 degrees.

with positive Ortolani and Barlow manoeuvres and confirmation on a radiograph of the pelvis. Treatment in a Pavlik harness was commenced with regular weekly reviews for 4 weeks. Despite this, the left hip failed to improve with a persistent clinically positive Ortolani manoeuvre with a subluxed hip on the ultrasound image of the hip and radiographs (acetabular index of 31° on the left and 25° on the right) (Fig. 3).

Examination under anaesthesia at 4 and a half months of age revealed negative Ortolani and Barlow manoeuvres, but plain radiograph confirmed a subluxed left hip. Subsequent arthrogram identified no barriers to reduction and a closed reduction was performed in a safe position of Ramsey with application of hip spica.

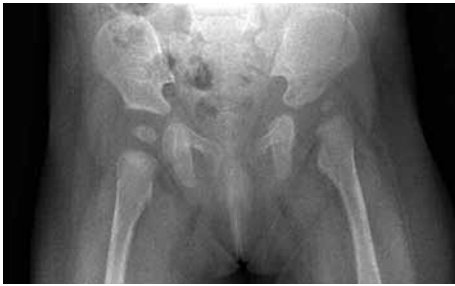

Fig. 3. — Case 1. Radiographs confirming subluxation of the left hip in the upper outer quadrant with an acetabular index of 31° on the left and 25° on the right.

Case report 2

A female child born by elective caesarean section was referred by the neonatologist due to breech presentation. The birth weight was 2880 grams (just below 25th centile) and head circumference was 33.5 cm (just below 25th centile). Examination was normal except for bright blue sclera, jaundice, secondary to ABO incompatibility and persisting for 4 weeks, and a left side torticollis which resolved after 4 months. There was a family history of blue sclera (mother and brother), phenylketonuria, cleft lip and palate, hearing loss and delayed dental eruption. There was no history of osteogenesis imperfecta, and chromosomal analysis showed normal female karyotype, 46XX.

On the 4 week review in the paediatric orthopaedic clinic, her hip was stable (negative Ortolani and Barlow manoeuvres) and ultrasound of the hips revealed an α -angle of 80° on the right (Fig. 4) and 71° on the left with no evidence of subluxation or dislocation on dynamic assessment, and she was discharged from the clinic. Over the subsequent year, she was extensively investigated by the paediatricians for motor developmental delay with a potential underlying syndrome. She was referred back to the paediatric orthopaedic clinic where examination demonstrated marked limitation of abduction in the right hip compared to the left, and a short right leg with a positive Galeazzi sign showing shortening in the femur. Her spine was normal. Radiographs at the time confirmed a dislocated right hip with an acetabular index of 25° on the left and 30° on the right.

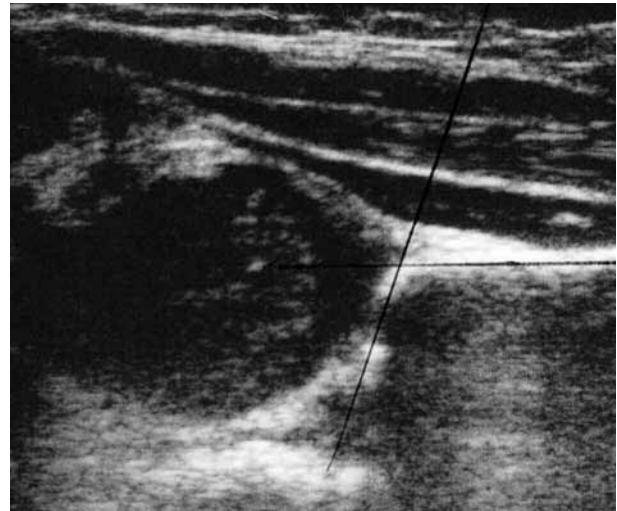


Fig. 4. — Case 2. Ultrasound of the right hip showing no evidence of subluxation or dislocation on dynamic assessment and an alpha-angle of 80 degrees.

An arthrogram revealed a dislocated right hip in external rotation and neutral positions with a large ligamentum teres. An open reduction was successfully performed. Follow-up radiographs at 1 year post-operatively showed an acetabular index of 18° on the left and 25° on the right. At 2 years post-operatively the acetabular index was 17° on the left and 20° on the right. Further Investigations by the paediatricians have suggested features consistent with the autosomal recessive condition, brittle cornea syndrome, which shows considerable overlap with Ehlers-Danlos Syndrome Type 6, but has a more distinct phenotype.

DISCUSSION

Developmental Dysplasia of the Hip (DDH) is defined as a spectrum of disorders of the hip ranging from dysplasia to irreducible hip dislocation. This is a dynamic condition in which the hip abnormality can resolve or deteriorate (10). It specifically excludes neurological, neuromuscular and syndromal conditions (2,4). The hip condition in these two case histories is by definition not DDH and therefore is less predictable. The natural history in the majority of clinically unstable hips (Ortolani and

Barlow manoeuvres positive) is spontaneous resolution, with between 71 and 88% resolving between 2 and 4 weeks of age (1,7). In general, a clinically and sonographically normal hip should not deteriorate, however in these two case histories there was an underlying syndrome, which behaves unpredictably compared to 'true' DDH. Females are thought to be more at risk than males in the development of irreducible or pathological DDH (3,6,12). This is thought to be due to their increased laxity compared with males (16).

There is a 'hyperlaxity' of the hip joints in Turner's syndrome which makes successful treatment in a Pavlik Harness less likely. This is similar to other hyperlaxity syndromes such as Ehlers-Danlos and Marfan's Syndrome, however Mosaic Turner's Syndrome is less phenotypical than pure XO and is therefore less obvious clinically.

In the literature, Jaiswal *et al* (9) and Gwynne Jones *et al* (8) have described case histories in which morphologically normal hips developed irreducible hip dislocation. However, in our opinion there are errors in the methodology, as in the series, the hips were sonographically dysplastic on discharge and the other dynamic assessment was not undertaken. These hips may not have been normal. It is known that minor sonographic abnormalities may deteriorate (14). In conclusion, if a hip has been referred as unstable but it is found to have a primary syndromal cause (especially if hyper lax) with sonographically normal hips at one to two weeks of age, it is best to review clinically and sonographically at 6 weeks and 3 months of age to confirm that the hip is maintaining stability, as there is a possibility that in these hyperlax conditions the hip can deteriorate. It is more likely that such hips will fail to settle with a Pavlik harness and may need more complex intervention.

REFERENCES

1. **Barlow TG.** Early diagnosis and treatment of congenital dislocation of the hip joint in the newborn. *J Bone Joint Surg* 1962 ; 44-B : 292-301.
2. **Bialik V, Bialik GM, Blazer S et al.** Developmental dysplasia of the hip : a new approach to incidence. *Pediatrics* 1999 ; 103 : 93-99.
3. **Chan A, McCaul KA, Cundy PJ, Haan EA, Byron-Scott R.** Perinatal risk factors for developmental dysplasia of the hip. *Arch Dis Child Fetal Neonatal Ed* 1997 ; 76 : F94-100.
4. **Committee on Quality Improvement, Subcommittee on Developmental Dysplasia of the Hip.** Clinical practice guideline : early detection of developmental dysplasia of the hip. *Pediatrics* 2000 ; 105 : 896-905.
5. **Dezateux C, Rosendahl K.** Developmental dysplasia of the hip. *Lancet* 2007 ; 369 : 1541-1552.
6. **Dunn PM.** The anatomy and pathology of congenital dislocation of the hip. *Clin Orthop Relat Res.* 1976 ; 119 : 23-27.
7. **Gardiner HM, Dunn PM.** Controlled trial of immediate splinting versus ultrasonographic surveillance in congenitally dislocatable hips. *Lancet* 1990 ; 336 : 1553-1556.
8. **Gwynne-Jones DP, Dunbar JD, Theis JC.** Late presenting dislocation of sonographically stable hips. *J Pediatr Orthop B.* 2006 ; 15 : 257-261.
9. **Jaiswal A, Starks I, Kiely NT.** Late dislocation of the hip following normal neonatal clinical and ultrasound examination. *J Bone Joint Surg* 2010 ; 92-B : 1449-1451.
10. **Kliscic PJ.** Congenital dislocation of the hip--a misleading term : brief report. *J Bone Joint Surg* 1989 ; 71-B : 136.
11. **Marks DS, Clegg J, Al-Chalabi AN.** Routine ultrasound screening for neonatal hip instability. Can it abolish late-presenting congenital dislocation of the hip ? *J Bone Joint Surg* 1994 ; 76-B : 534-538.
12. **Paton RW, Hinduja K, Thomas CD.** The significance of at-risk factors in ultrasound surveillance of developmental dysplasia of the hip. A ten-year prospective study. *J Bone Joint Surg* 2005 ; 87-B : 1264-1266.
13. **Paton RW, Srinivasan MS, Shah B, Hollis S.** Ultrasound screening for hips at risk in developmental dysplasia. Is it worth it ? *J Bone Joint Surg* 1999 ; 81-B : 255-258.
14. **Rosendahl K, Markestad T, Lie RT.** Developmental dysplasia of the hip. A population-based comparison of ultrasound and clinical findings. *Acta Paediatr* 1996 ; 85 : 64-69.
15. **Sewell MD, Rosendahl K, Eastwood DM.** Developmental dysplasia of the hip. *BMJ* 2009 ; 339 : b4454.
16. **Wynne-Davies R.** Acetabular dysplasia and familial joint laxity : two etiological factors in congenital dislocation of the hip. A review of 589 patients and their families. *J Bone Joint Surg* 1970 ; 52-B : 704-716.
17. **Zadeh HG, Catterall A, Hashemi-Nejad A, Perry RE.** Test of stability as an aid to decide the need for osteotomy in association with open reduction in developmental dysplasia of the hip. *J Bone Joint Surg* 2000 ; 82-B : 17-27.