



Multi-modality imaging of transient osteoporosis of the hip

Filip GEMMEL, Hugo C. VAN DER VEEN, Willem D. VAN SCHELVEN, James M. P. COLLINS,
Isabelle VANNEUVILLE, Paul C. RIJK

From AZ Alma, Campus Sijsele, Belgium, University of Groningen, Groningen, and Medisch Centrum Leeuwarden, Leeuwarden, The Netherlands

Transient osteoporosis of the hip (TOH), also referred to as bone marrow edema syndrome (BMES) of the femoral head and neck, is an uncommon and therefore underdiagnosed benign skeletal disorder, affecting primarily women, particularly in their last trimester of pregnancy, and middle-aged men. The disease is characterized by self-limiting hip pain and radiographically evident osteopenia, but these radiographic findings can sometimes be delayed. In the early phase, the main diagnostic dilemma lies in differentiating TOH from osteonecrosis of the femoral head (ONFH). Conventional radiographs, Tc-99m bone scans (multiphase, SPECT or SPECT/CT) and MRI scans from 10 male patients with 12 TOH episodes were retrospectively and independently reviewed by two nuclear medicine physicians and a musculoskeletal radiologist. The purpose was to identify a typical imaging pattern, and secondly, to reliably distinguish TOH from ONFH. In the early phase of TOH, conventional radiography of the hip could not sufficiently detect focal osteopenia. But in all 10 patients (mean age 45 years, range, 34-62), bone scans and MRI scans demonstrated a similar pattern of diffuse hyperaemia, bony uptake, and bone marrow edema in the femoral head and neck, extending to and ending with a sharp demarcation at the intertrochanteric region. Additionally, neither SPECT nor SPECT/CT nor MRI revealed any cold area or crescent-shaped subchondral defect in the femoral head, indicating ONFH. In some cases there was a joint effusion in varying degree. In 9 patients, an uneventful recovery was eventually observed. Scintigraphically diffuse hyperaemic and/or homoge-

neous osseous uptake in femoral head and neck extending to the intertrochanteric region, as well as the recently introduced term transient bone marrow edema syndrome (BMES) of the hip on MRI, are probably both expressions of the same pathophysiological mechanism, and pathognomonic for TOH. Hopefully, recognizing this highly specific imaging pattern will exclude in the future more aggressive skeletal diseases like ONFH, severe arthritis, osteomyelitis or even malignancy.

Keywords : transient osteoporosis hip ; bone marrow edema ; osteonecrosis of the femoral head ; bone scan ; SPECT ; MRI.

-
- Filip Gemmel, MD, Consultant Nuclear Medicine.
 - Isabelle Vanneuville, MD, Consultant Physical Medicine.
AZ Alma, Campus Sijsele, Sijsele, Belgium.
 - Hugo C. van der Veen, MD, Orthopaedic Resident.
University Groningen.
 - Willem D van Schelven, MD, Consultant Nuclear Medicine.
 - James M.P. Collins, MD, Consultant Radiology.
 - Paul C. Rijck, MD, PhD, Orthopaedic Surgeon.
Medisch Centrum Leeuwarden, Leeuwarden, The Netherlands.

Correspondence : Filip Gemmel, Department of Nuclear Medicine, AZ Alma, Campus Sijsele, Gentse Steenweg 132, 8340 Sijsele-Damme, Belgium.

E-mail : filip.gemmel@azalma.be
filip.gemmel@azoudenaarde.be

© 2012, Acta Orthopædica Belgica.

INTRODUCTION

Transient osteoporosis of the hip (TOH) is an idiopathic, self-limiting syndrome, clinically characterized by progressive or sudden onset of groin pain, slightly reduced mobility of the hip, nonspecific laboratory findings, localized radiographic evidence of osteopenia, and eventually spontaneous recovery, usually within two to nine months (4,7,15,19,22,23). Since Curtiss and Kincaid (7) first described “transitory demineralization of the hip in the third trimester of pregnancy” in the English literature in 1959, many new cases have been reported, mainly in the non-imaging literature. Other synonyms existing in the nuclear and radiologic imaging literature include “migratory osteolysis”, “regional or idiopathic transient osteoporosis”, “algodystrophy or reflex sympathetic dystrophy (RSD) of the hip”, and “transient bone marrow edema syndrome” (BMES) (15,19,22,23).

The aim of this retrospective series of TOH patients was to arouse the awareness of the clinician and imaging specialist regarding this uncommon skeletal condition, and to help recognize any typical imaging pattern, provided either by dedicated bone scintigraphy (BS) or MR imaging (MRI) (2,4,22).

PATIENTS AND METHODS

Patient selection

Ten male patients with TOH were seen between July 2003 and June 2010. Their mean age was 45 years (range: 34-62). Inclusion criteria: selection for this retrospective series by one of the involved orthopaedic surgeons and by one of the involved nuclear medicine specialists. The diagnosis of TOH was based on clinical picture, various imaging findings, and eventually spontaneous clinical recovery. This meant consensus among imaging specialist and orthopaedic surgeon. Exclusion criteria: 1. a high suspicion of degenerative hip joint disease or osteonecrosis of the femoral head (ONFH); 2. multiple lesions on the bone scan, pleading for malignancy; 3. inflammatory pathology, suggested by the biochemistry.

Imaging techniques

Conventional radiography: at least one anterior-posterior view of the pelvis, with special attention to

the hips, was obtained. It was interpreted by a single experienced musculoskeletal radiologist.

Bone scintigraphy (BS) was performed using a single- or double-headed gamma camera, equipped with low energy, high-resolution, parallel hole collimators. The energy peak was centred at 140 keV with a 15% window. Two-phase bone scintigrams were made after injection of approximately 925 MBq (25 mCi) of Tc-99m-HDP. Two minutes post-injection, selected blood pool images were obtained. Three to 4 hours post-injection, delayed whole-body imaging and/or planar images of the pelvis and/or lower body were made. Optionally, single photon emission tomography (SPECT) and/or hybrid bone imaging with SPECT-CT of the pelvis were performed. The acquisition parameters were as follows: the matrix size was 256 × 256, and a high-resolution, low-energy all purposes collimator was used. The image time was set on 3 minutes for each static view, or 12 cm/minute for a total body scan. SPECT acquisition and processing parameters were as follows: non-circular orbit, matrix size 128 × 128, 64 × 30 seconds, without attenuation correction, reconstructed with filtered back projection; SPECT/CT images were performed on a dedicated device with a two-slice CT component (Biograph, T2, equipped with CARE Dose 4D, Siemens Healthcare). Processing parameters were as follows: iterative reconstruction (8 iterations, 16 subsets, Flash 3-D, with attenuation correction). Low-dose CT was preferred in order to minimize the added radiation exposure for the patient. All planar and SPECT images were evaluated independently by two certified nuclear medicine physicians. A diffuse increased blood pool phase (or hyperemia) and/or delayed homogeneous osseous uptake localized in the entire femoral head and neck, especially sharply ending at the intertrochanteric region, was indicative of TOH (8,20).

MRI was performed using a 1.5 Tesla superconducting magnet (Philips), with T1- and T2- weighted images (T1WI and T2WI) and short tau inversion recovery (STIR or fat suppression) weighted images, obtained in the coronal and axial planes. No gadolinium contrast material was used. All MR images were interpreted by a single experienced musculoskeletal radiologist. MRI of transient osteoporosis of the hip typically gives a diffuse bone marrow edema (BME) pattern, of low-signal intensity on T1WI, and of high signal intensity on STIR or fat-suppressed T2WI, corresponding with increased interstitial water content. This MRI pattern is diffuse, namely involving the whole femoral head and neck; it often extends to the intertrochanteric line, where it is sharply demarcated (23). Hip effusion can be seen, but

clearly focal subchondral changes, especially a crescent-shaped low signal intensity area in the anterosuperior aspect of the femoral head, must be absent (22). Finally, the adjacent soft tissues must be normal.

RESULTS

The right hip was involved in 4 patients, the left hip in 6. Two patients (cases 7 and 8) had passed through a previous episode, but on the contralateral side, respectively 18 and 12 months before ; only the second episode was included in this study. Yet another patient (case 4) had suffered of transient osteoporosis in his right foot, 20 months before.

No patient had a history of recent trauma or related illness. One patient suffered from diabetes mellitus, but there were no other predisposing factors for the development of osteonecrosis of the femoral head (ONFH), such as prolonged use of steroids.

All patients presented initially with increasing groin pain, of sudden or progressive onset, particularly on weight-bearing, lasting from 3 weeks to 5 months. Most patients had little discomfort at rest. Over a time span of 3 to 8 months, all but one patient (see further : case 5) experienced progressive improvement and ultimately recovered spontaneously, without any invasive therapy. Surprisingly, in 2 patients (cases 2 and 10), the hip pain was already less at the time of the bone scan. In contrast, the hip pain of the oldest patient (case 5) was unbearable : he went for a total hip arthroplasty 2 months later, with a preliminary diagnosis of osteonecrosis. Retrospectively the diagnosis of TOH was made, based, among others, on the histological aspect of the femoral head (Fig. 4). In fact this was the only incorrect diagnosis. All the patients were in good health.

Range of motion : abduction, flexion and internal rotation were only slightly limited, which contrasted with the limping gait, the functional disability and the dependence on crutches (3 patients in the acute phase). Local tenderness was also quite limited. Trophic changes were absent.

Laboratory tests, such as C-reactive protein, erythrocyte sedimentation rate, white blood cell count, and rheumatology serology (when available)

were all unremarkable. Follow-up visits to the outpatient clinic (with repeat plain radiographs when considered necessary) were arranged. The treating physicians installed a symptomatic treatment with anti-inflammatory agents in addition to joint protection and gradual ambulation.

Imaging Findings

Plain radiographs

In all the patients at least one conventional radiograph was available at the time of inclusion (Table I). Initial radiographs showed focal osteopenia in 7 out of 10 patients, but it was subtle (Fig. 1a). Even repeat radiographs, available in 7 cases, showed no diffuse osteopenia, with one exception. Remarkably, in 2 patients conventional radiographs did not show any abnormal finding during the whole disease period (Fig. 2a). The hip joint space was preserved in all patients, and at no time was there osseous erosion or subchondral collapse (9).

Bone scintigraphy

There was a bone scintigraphy of one documented episode of TOH (Table I) in all the included patients. In seven patients there was a bloodpool phase performed. In 6 of them, it showed a diffuse increased hyperaemia with varying intensity (ranging from subtle to marked) in the proximal femoral region (Fig. 1b). Furthermore, in all patients the delayed bone scan revealed a homogeneously increased bony uptake, with varying intensity, in the affected femoral head, extending down into the femoral neck and intertrochanteric region (Fig. 1c, 2b). In one patient with a recurrence of TOH (case 7), the abnormal scintigraphic findings of the earlier involved hip had returned to normal. Moreover, bone-SPECT and/or hybrid bone SPECT/low dose CT was performed in 7 patients (SPECT n = 5, SPECT-CT n = 2). In none of these patients could SPECT imaging demonstrate a cold area in the femoral head (Fig. 3a). Additional co-registered low-dose CT imaging did reveal a diffuse osteopenia in the proximal femur but no crescent sign or collapse of the femoral head (Figs. 3b,c).

Table I. — Demographics, history, clinical examination and imaging

	1	2	3	4	5	6	7	8	9	10
Side	R	L	R	L	L	R	R	L	L	L
Age (yrs)	51	40	49	37	62	53	37	39	52	34
Co-morbidity	-	-	-	diabetes	-	-	-	-	-	-
Onset	progr.	sudden	progr.	progr.	sudden	progr.	sudden	sudden	progr.	progr.
Disability	+	+	+	+	+	+	+	+	+	+
Limp			crutches	crutches						crutches
Hip mobility slightly reduced	+	+	+	+	+	+	+	+	+	+
Plain radiographs :										
Initial	±	±	-	±	-	±	±	±	±	±
Repeat		NA	-	±	-	-	+	NA	NA	-
Bone scan										
Pool	+	NA	NA	+	+	+	+	+	NA	±
Delayed	+	+	+	+	+	+	+	+	+	+
Spect (-CT)	NA	NA	+	+	+	+	+	+	NA	+
MRI										
BMES	+	+	+	+	+	+	±	+	+	+
Effusion	±	+	±	-	-	+	-	+	+	±
Duration (months)	4	3	5	8	THA	4	4	4	7	6

BMES = bone marrow edema syndrome ; NA = not available ; THA = total hip arthroplasty.

Finally in the oldest patient (case 5), the incorrect diagnosis of ONFH was initially made (Fig. 4).

MRI findings

Dedicated MRI sequences were performed in all patients (Table I). There was no injection of intravenous gadolinium contrast material. MRI showed in all the included patients a pattern of diffuse bone marrow edema (BME) varying from subtle to marked, but in none of them were there clearly focal femoral head changes or a crescent line (Figs. 1d,e and 2c,d). Moreover, there was in all patients a relative preservation of the subchondral bone marrow on T1WI. Furthermore in 8 patients minor to significant joint effusion was seen (Fig. 2d). In another patient with a recurrence in his left hip, MRI signal of the involved right hip, 1 year before, had returned to normal. Furthermore, there was an intact articular surface, and neither focal osteonecrotic signs nor collapse of the femoral head were observed.

DISCUSSION

The most important finding of the present study was a typical scintigraphic and MRI image of a diffusely increased activity in the proximal femur, sharply ending at the intertrochanteric line : a remarkable congruent pattern.

Transient osteoporosis of the hip (TOH) with bone marrow edema (BME) is a rare cause of acute hip pain in pregnant women and young or middle-aged adults, and therefore it is a relatively unknown clinical entity which is under diagnosed (2,4,7,11,14, 18,23) The clinical hallmark which separates TOH from other, more aggressive hip conditions, is its self-limiting nature (4,6,9,14).

In this retrospective series, TOH typically presented in healthy young to middle-aged men, with an average age of 45 years (range, 34 to 62). Two patients had a documented episode of TOH in the opposite hip, approximately 1 year before. Another patient had suffered from a similar episode involving the right foot, with full recovery, approximately

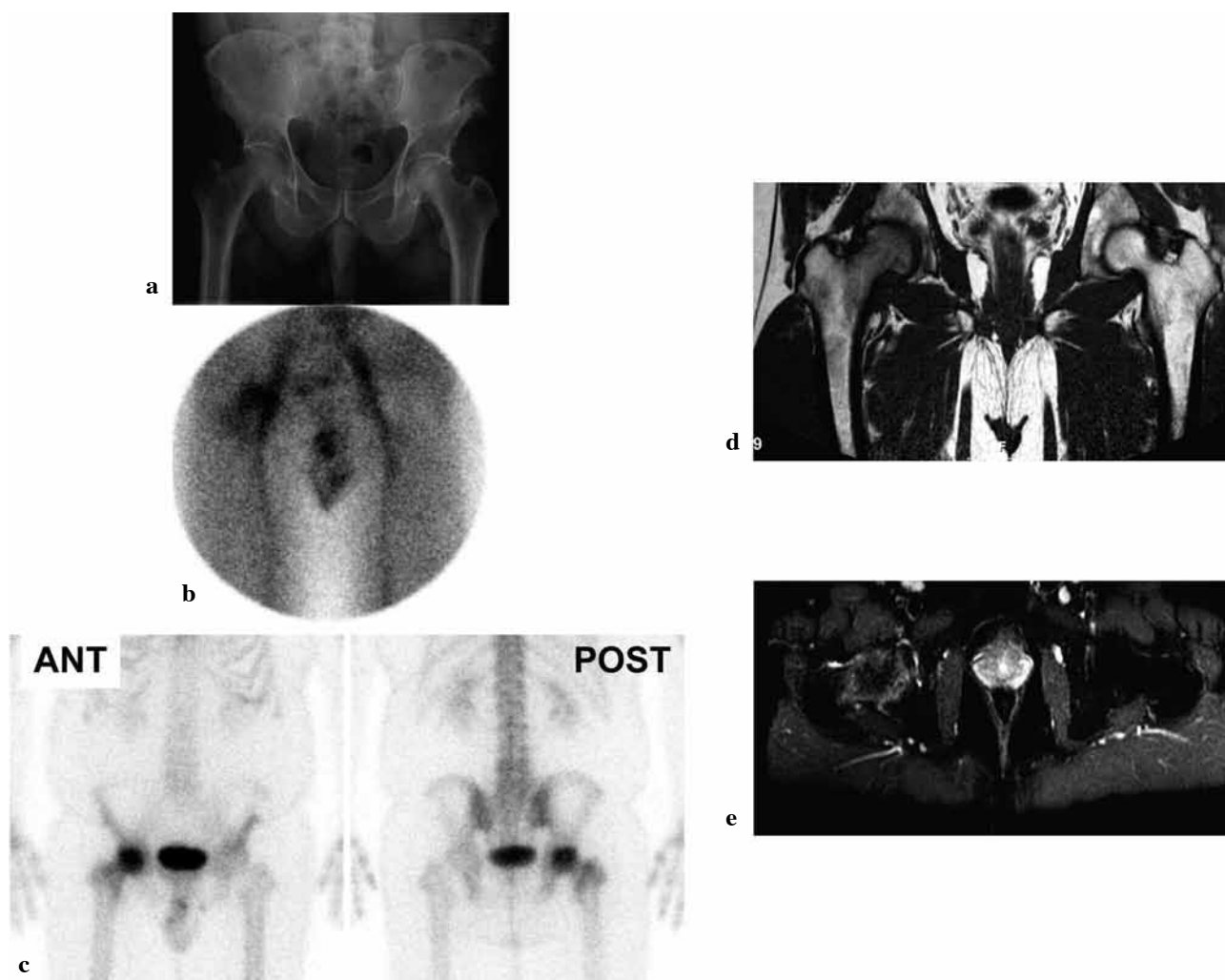


Fig. 1. — Case 1 : a : plain radiograph : subtle focal osteopenia right hip ; b : early blood pool : hyperemia ; c : delayed planar bone scan : increased uptake right hip as far as intertrochanteric line ; d and e : T1-weighted and fat suppressed T2-weighted MRI : respectively hypo- and hyperintensity.

2 years earlier. All the patients were in good general health. Although one patient suffered from diabetes, there were no other predisposing factors for the development of osteonecrosis of the femoral head (ONFH).

Minimal clinical findings in spite of pronounced pain

A striking feature, seen in the current series and similar to findings reported in the literature, was the

fact that during the period of maximum symptoms there was a disproportionate functional disability in the presence of only minimal physical findings at examination (3,6,9,14,15). Furthermore, no other joints were simultaneously involved, nor were systemic symptoms present. On the other hand, in accordance with the literature, two patients had suffered from a previous episode in the opposite hip, but no one had bilateral involvement or recurrence in the same hip (2,14,19). Finally, laboratory tests did not reveal any evidence of a systemic or rheumatologic disease (4,6,14).

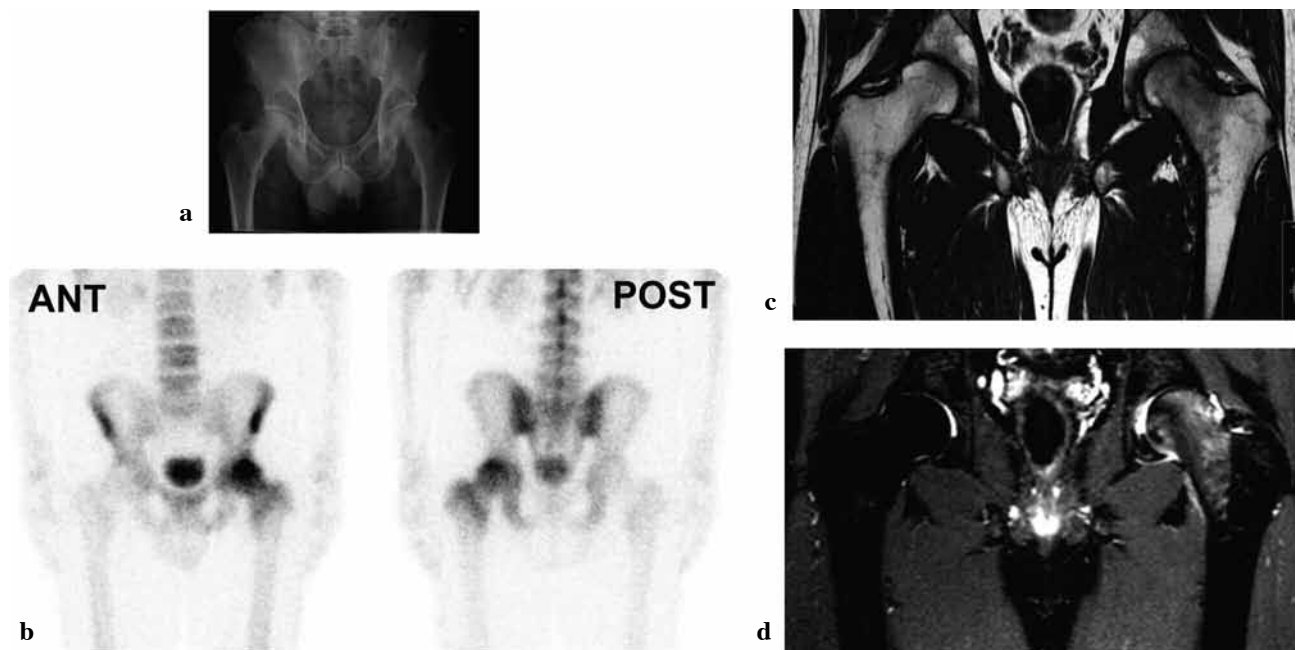


Fig. 2. — Case 2 : a : plain radiograph : no osteopenia left hip ; b : delayed planar bone scan : increased uptake left hip as far as intertrochanteric line ; c and d : T1-weighted and fat suppressed T2-weighted MRI : bone marrow edema as far as the intertrochanteric line ; hip joint effusion.

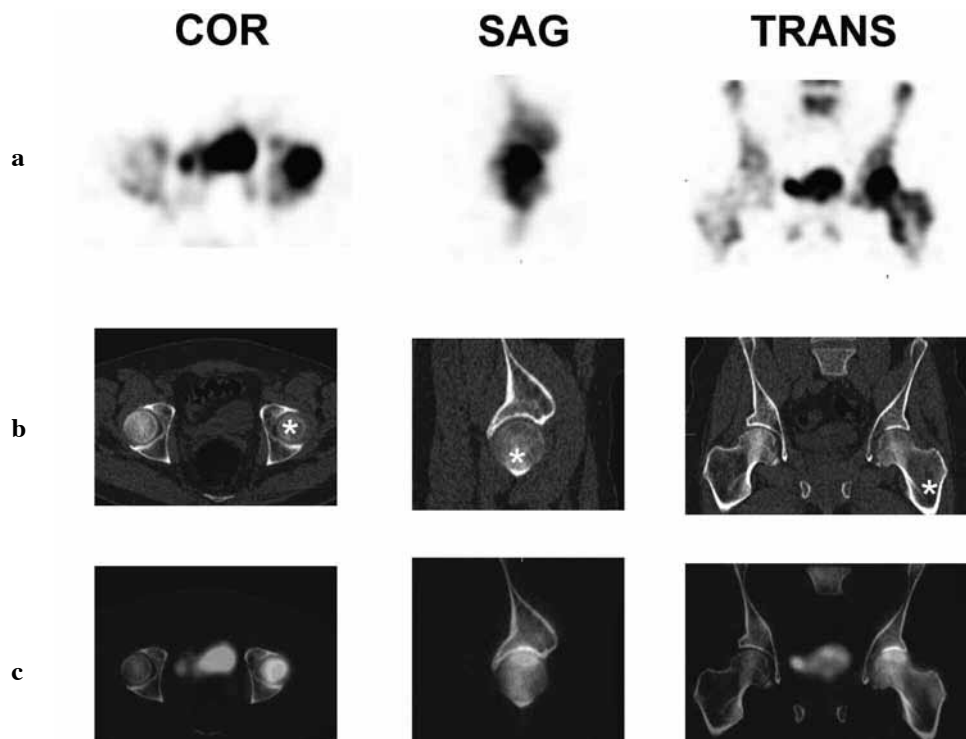


Fig. 3. — Case 4 : a : SPECT : increased uptake left hip, without cold zone ; b : low-dose CT : no collapse, no subchondral crescent line, but diffuse demineralization ; c : SPECT/CT : increased uptake, without collapse.

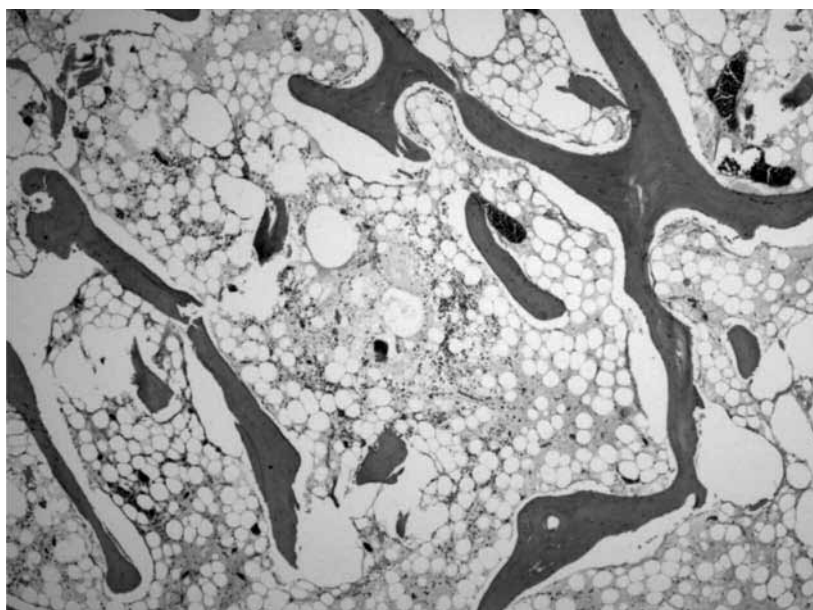


Fig. 4. — Case 5 : a prosthesis was inserted for so-called osteonecrosis, before the diagnosis of transient osteoporosis was made, so that a biopsy sample became available. High-power view, haematoxylin-eosin : serous exsudate, no osteonecrosis.

3 clinical phases

According to Schapira (18), 3 consecutive clinical phases can be identified during the whole disease process. An initial phase is characterized by increasing pain with functional disability, lasting approximately one to 2 months ; in this stage, the conventional radiography can be normal. During the next 2 to 3 months, the pain becomes maximal, while, in general, marked osteopenia appears on conventional radiographs. Finally, during the third, or healing phase (ranging from 6 to 12 months), spontaneous clinical regression takes place, concomitantly with gradual disappearance of the focal osteopenia, finally resulting in a complete cure in most patients (18). This sequence was also seen in the current series, but marked osteopenia on conventional radiographs was mostly absent. It is well-known that it can take 4 to 8 weeks to observe the typical osteopenia, since demineralization of bone is not apparent on plain radiographs until about 40 percent of trabecular bone has been lost.

Therefore bone scan and MRI can be positive at an earlier stage (12,22). Even a discordant condition of persistently negative radiograph versus positive bone scan has been reported in the literature (21), also observed twice in our series (cases 3 and 5). On the other hand, in 2 patients, imaged with the new hybrid SPECT-CT modality, the co-registered low-dose CT showed a diffuse demineralisation in the proximal femur (Fig. 3b, 3c).

Scintigraphy and MRI : typical boundary

Remarkably, all patients showed a similar pattern with hyperaemia, osseous uptake, and bone marrow edema, localized in the femoral head and neck, extending to and, specifically, sharply ending at the intertrochanteric region (3,6,14). Additionally, on dedicated tomographic images such as bone-SPECT, SPECT-CT and T2-STIR MR imaging, osteonecrosis of the femoral head could reliably be excluded by the absence of a cold defect and by the absence of any obvious subchondral changes or collapse (3,19).

In one patient (case 5), however, the diagnosis of ONFH was initially incorrectly made and the patient went for a hip arthroplasty. Histopathologic analysis of the femoral head (Fig. 4) revealed neither osteonecrosis nor osteomyelitis, confirming that ONFH was not the underlying aetiology.

Aetiology

The aetiology of BMES/TOH remains controversial and the pathophysiology of the condition is poorly understood. Several authors described histomorphological, scintigraphic and MRI changes in the synovium and in the bone marrow: interstitial marrow edema, trabecular bone abnormalities, and mild or nonspecific chronic inflammation such as fibrosis. Therefore, those histopathological findings of diffuse reactive bone and marrow changes could probably explain the quite similar imaging patterns observed on bone scan and MRI (3,8,10,12,16-18,20,23,24).

Treatment

The currently accepted treatment is supportive and symptomatic. This entails judicious use of analgesics, non-steroidal anti-inflammatory drugs, limited or protected weight bearing, and a graduated physiotherapy regime (3,4,6,14,19). The ultimate aim is to reduce the chance of developing microfractures and subsequently pathologic fractures in the weakened bone (14,19). Oral and intravenous bisphosphonates may be beneficial and may speed up recovery (13). Calcitonin, prednisolone, and the bone sparing steroid deflazacort have been used, but none of those products were well evaluated in randomized, prospective trials (1,5,14). Finally, due to the self-limiting course, reassurance and patience on the part of the clinician are perhaps the most important elements of the management of this syndrome (2,4,6,9).

Limitations

The retrospective character of this study made that the technical approach was not the same in all patients.

CONCLUSIONS

Transient osteoporosis of the hip is an uncommon and self-limiting condition, predominantly observed in young to middle-aged men, with an overall excellent prognosis. It is a challenging entity for the clinician and last but not least for the multimodality imaging physician (8,9,20). The diffuse hyperaemic bony uptake (bone scan) and bone marrow edema (MRI), localized in the proximal femur and sharply ending in the intertrochanteric region, possibly reflect the same pathophysiologic mechanism of increased bone turnover and hypervascularization (8,10,20,22,24).

Bone scintigraphy is an important screening adjunct before obvious radiographic changes are seen, as illustrated in the current retrospective series (3,21). Therefore scintigraphy appears quite useful and complementary in the early diagnosis and management of patients with TOH, especially when there are access problems and/or contraindications for MRI (4,6,19,20). Nevertheless, MRI remains the imaging modality of choice for the evaluation of bone marrow edema syndrome (22). Past history, clinical examination and evolution, biochemical evaluation, multi-phase bone scan (supplemented with SPECT or SPECT-CT), and dedicated MRI offer the solution to this under-recognized benign skeletal disorder (3,4,6,9,19,21,23). Those imaging modalities can help the image specialist to make the correct diagnosis and avoid invasive biopsy procedures (2,4,9). Finally, due to the self-limiting course, reassurance and patience are perhaps the most important elements for treatment (2,4,6,9).

Acknowledgements

The authors gratefully acknowledge the involved orthopaedic surgeons of Medical Center Leeuwarden. They also thank Carolien Bronkhorst, MD, Department of Pathology, who kindly offered the histological slide and assisted in the accompanying text. They are also grateful to Roland Boomsma, NMT, who prepared the figures.

REFERENCES

1. Arayssi TK, Tawbi HA, Usta IM, Hourani MH. Calcitonin in the treatment of transient osteoporosis of the hip. *Semin Arthritis Rheum* 2003; 32: 388-397.

2. **Balakrishnan A, Schemitsch EH, Pearce D, McKee MD.** Distinguishing transient osteoporosis of the hip from avascular necrosis. *Can J Surg* 2003 ; 46 : 187-192.
3. **Bramlett KW, Killian JT, Nasca RJ, Daniel WW.** Transient osteoporosis. *Clin Orthop Relat Res* 1987 ; 222 : 197-202.
4. **Bruinsma BJ, LaBan MM.** The ghost joint : transient osteoporosis of the hip. *Arch Phys Med Rehabil* 1990 ; 71 : 295-298.
5. **Carmona-Ortells L, Carvajal-Mendez I, Garcia-Vadillo JA et al.** Transient osteoporosis of the hip : successful response to deflazacort. *Clin Exp Rheumatol* 1995 ; 13 : 653-655.
6. **Crespo E, Sala D, Crespo R, Silvestre A.** Transient osteoporosis. *Acta Orthop Belg* 2001 ; 67 : 330-337.
7. **Curtiss Ph jr, Kincaid WE.** Transitory demineralization of the hip in pregnancy. A report of three cases. *J Bone Joint Surg* 1959 ; 41-A : 1327-1333.
8. **Gaucher A, Colomb JN, Naoun A, Faure G, Netter P.** The diagnostic value of 99m Tc-diphosphonate bone imaging in transient osteoporosis of the hip. *J Rheumatol* 1979 ; 6 : 574-583.
9. **Guerra JJ, Steinberg ME.** Distinguishing transient osteoporosis from avascular necrosis of the hip. *J Bone Joint Surg* 1995 ; 77-A : 616-624.
10. **Hayes CW, Conway WF, Daniel WW.** MR imaging of bone marrow edema pattern : transient osteoporosis, transient bone marrow edema syndrome, or osteonecrosis. *Radiographics* 1993 ; 13 : 1001-1011.
11. **Hunder GG, Kelly PJ.** Roentgenologic transient osteoporosis of the hip. A clinical syndrome ? *Ann Intern Med* 1968 ; 68 : 539-552.
12. **Hunder GG, Kelly PJ.** Bone scans in transient osteoporosis. *Ann Intern Med* 1971 ; 75 : 134.
13. **Kibbi L, Touma Z, Khoury N, Arayssi T.** Oral biphosphonates in treatment of transient osteoporosis. *Clin Rheumatol* 2008 ; 27 : 529-532.
14. **Lakhanpal S, Ginsburg WW, Luthra HS, Hunder GG.** Transient regional osteoporosis. A study of 56 cases and review of the literature. *Ann Intern Med* 1987 ; 106 : 444-450.
15. **Lequesne M.** Transient osteoporosis of the hip. A nontraumatic variety of Sudeck's atrophy. *Ann Rheum Dis* 1968 ; 27 : 463-471.
16. **McCarthy EF.** The pathology of transient regional osteoporosis. *Iowa Orthop J* 1998 ; 18 : 35-42.
17. **Plenk H Jr, Hofmann S, Eschberger J et al.** Histomorphology and bone morphometry of the bone marrow edema syndrome of the hip. *Clin Orthop Relat Res* 1997 ; 334 : 73-84.
18. **Schapira D.** Transient osteoporosis of the hip. *Semin Arthritis Rheum* 1992 ; 22 : 98-105.
19. **Shifrin LZ, Reis ND, Zinman H, Besser MI.** Idiopathic transient osteoporosis of the hip. *J Bone Joint Surg* 1987 ; 69-B : 769-773.
20. **Staudenherz A, Hofmann S, Breitenseher M et al.** Diagnostic patterns for bone marrow oedema syndrome and avascular necrosis of the femoral head in dynamic bone scintigraphy. *Nucl Med Commun* 1997 ; 18 : 1178-1188.
21. **Tan TX, Dardani M, Neal DJ et al.** Atypical findings of discordant bone scan and radiographs in transient osteoporosis of the hip : case report and review of the literature. *Clin Nucl Med* 1998 ; 23 : 160-162.
22. **Vande Berg BC, Lecouvet FE, Koutaissoff S et al.** Bone marrow edema of the femoral head and transient osteoporosis of the hip. *Eur J Radiol* 2008 ; 67 : 68-77.
23. **Wilson AJ, Murphy WA, Hardy DC, Totty WG.** Transient osteoporosis : transient bone marrow edema ? *Radiology* 1988 ; 167 : 757-760.
24. **Yamamoto T, Kubo T, Hirasawa Y et al.** A clinicopathologic study of transient osteoporosis of the hip. *Skeletal Radiol* 1999 ; 28 : 621-627.