



Concomitant alar and apical ligament avulsion in atlanto-axial rotatory fixation Case report and review of the literature

Maher KARRAY, Najla M'NIF, Mondher MESTIRI, Mondher KOOLI, Khelil EZZAOUIA, Mongi ZLITNI

The authors report a case of Fielding type II acute atlanto-axial rotatory fixation (AARF). The CT scan with coronal reconstruction showed an avulsion of the apical and right alar ligament. These findings are exceptionally reported in the literature, especially concerning the apical ligament which might be a stabiliser in flexion and extension of the occipito-cervical joint.

CASE REPORT

A 40-year-old man without any particular antecedents received a heavy load on the right side of the occiput with the head and trunk tilted forward. The trauma was accompanied with an audible crack and an electric shock that radiated throughout the whole body, but without loss of consciousness.

The head was held in a position of slight flexion and 20° of rotation to the left. Movement of the head and neck were severely restricted in all directions, and even slight attempts at rotation of the head caused a marked increase in the right occipital pain. The right occipital scalp was hyperalgaesic in the area of the greater occipital nerve, but no other neurological abnormalities were noted.

The open-mouth view showed an asymmetrical atlanto-odontoid interval with subluxation of the right atlanto-axial joint (fig 1). This suggested a rotatory fixation. Cinerentgenography in the lateral projection confirmed that the atlas and axis were moving as one unit during attempted neck rotation.

Computed Tomography showed rotation of C1 on C2 to the left, with an anterior displacement of

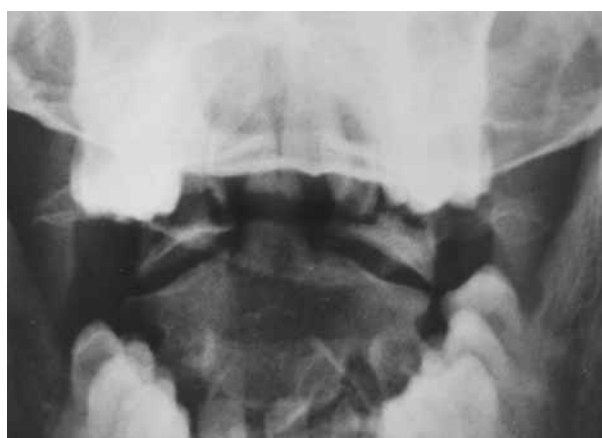

Fig. 1. — Open-mouth view shows asymmetrical atlanto-odontoid intervals with medial subluxation of the right mass of C1 and asymmetrical joint space which is increased on the right.

From "Charles Nicolle" Hospital, Tunis, Tunisia.

Maher Karray, Senior Registrar.

Mondher Mestiri, Professor.

Mondher Kooli, Professor.

Khelil Ezzaouia, Professor.

Mongi Zlitni, Professor and Chairman.

Department of Orthopaedic Surgery, Charles Nicolle Hospital, Tunis, Tunisia.

Najla M'nif, Senior Registrar.

Department of Radiology, Charles Nicolle Hospital, Tunis, Tunisia.

Correspondence : Maher Karray, Service d'Orthopédie et de Traumatologie, Hôpital Charles Nicolle, Boulevard 9 Avril, 1006 Tunis, Tunisie. E-mail : karray_maher@yahoo.fr.

© 2004, Acta Orthopædica Belgica.

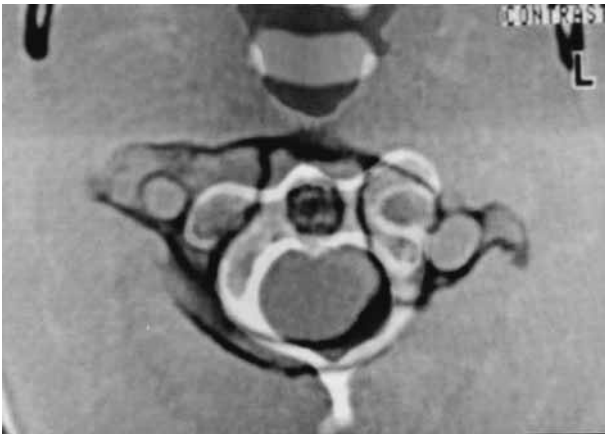


Fig. 2. — CT scan shows the right lateral mass of C1 lying anteriorly to the articular surface of C2, with normal left C1-C2 joint acting as the pivot of rotation. This is associated with a 4-mm anterior displacement of the anterior arch of C1.

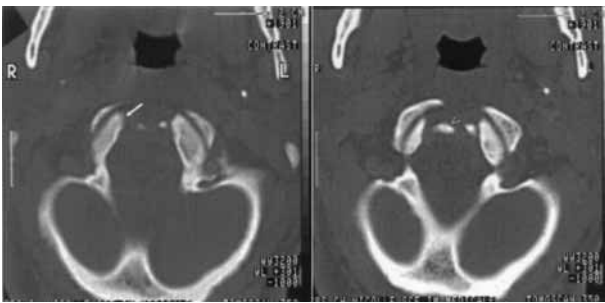


Fig. 3. — Axial CT at the level of foramen magnum. Left : two flake avulsions ; asymmetrical shape of occipital condyles due to right cortical defect (arrow). Right : this corresponds to bony avulsion of the right alar ligament (arrowhead).

4 mm (fig 2). According to the Fielding and Hawkins classification (8), this corresponded to an atlanto-axial rotatory fixation (AARF) type II. Moreover, computed tomography revealed two flake avulsions at the level of the foramen magnum (fig 3) which corresponded in coronal and sagittal reconstruction to the right alar ligament occipital insertion (type III of Anderson and Montesano classification) (2) and to the apical ligament insertion (type I of Anderson and D'Alonzo classification) (1) (fig 4). Cervical Halter traction was applied and after six days there was radiological normality. The traction was followed by bracing for 12 weeks. Afterwards the patient kept mild cervical pain, however with regression of right occipital paraes-

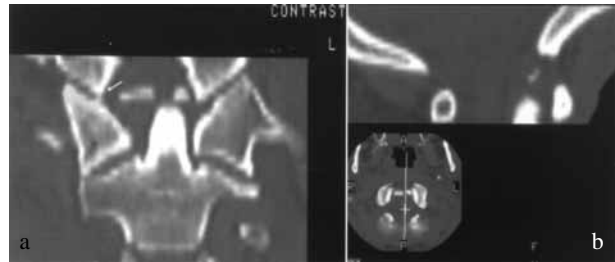


Fig. 4. — a. CT 2D coronal reconstruction shows : Left : Avulsion of the apex of odontoid process which is displaced to the left. Fracture of the medial side of the right occipital condyle which appears to be blunt (arrow) as compared to the left side. The avulsed fragment corresponds to the insertion of the right alar ligament. The right lateral mass of C1 appears to be thinner than the left because of its anterior displacement. Right upper corner : CT mid-sagittal reconstruction demonstrates avulsion of apical ligament. b. CT : Right lower corner : transverse CT shows two bone avulsions.

thesias. Active and passive cervical mobility was slightly diminished, mainly in flexion. Motor power and sensation were normal. Radiological control, consisting of open-mouth and lateral views, revealed a normal C1-C2 relationship. However, lateral dynamic roentgenograms showed an increased atlanto-odontoid interval of 5 mm in flexion, revealing a deficiency of the transverse ligament (fig 5). Coronal CT reformatting demonstrated nonunion of osteoperiosteal ligament avulsions.

A posterior fusion C1-C2 was proposed but was refused by the patient. At follow-up, five years after trauma, the patient complained of progressive weakness in his arms and legs. The neurological examination revealed worsening of the condition with brisk reflexes. Flexion-extension roentgenograms remained unchanged. The patient refused surgery.

DISCUSSION

Atlanto-axial rotatory fixation (AARF) is a rare condition which occurs more often in children than in adults (3). The diagnosis has become less difficult in recent years, also in the acute stage (15, 16). Even in cases where the mechanism of injury is not

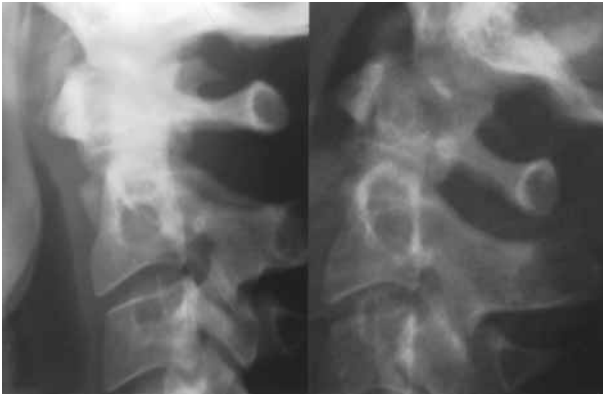

Fig. 5. — Flexion-extension lateral views, four months after injury, reveal an increased atlanto-odontoid interval in flexion (5 mm) with a bone fragment avulsed with the right alar ligament.

well defined, particularly in children, the persistent rotational, lateral flexion and flexion deformity of the neck (cock robin posture, like a robin listening for a worm) draws the attention (3). On a properly aligned open-mouth view the so called “wink sign” and the shift of the odontoid to one side are suggestive, and the diagnosis of rotatory fixation can then be confirmed using one of the following techniques :

- a. Open-mouth views taken in neutral position and with 15° of rotation to each side (18) showing a persistently asymmetrical relationship of the dens to the articular masses of the atlas.
- b. Cineradiography in the lateral projection in which the posterior arches of the atlas and the axis are seen to move as one unit during neck rotation (8, 16, 18).
- c. Functional CT scan through C1-C2 in which patients are scanned initially as they are presented with their heads fixed in the cock robin position, then with maximal voluntary contralateral rotation of the head. No motion at C1-C2 occurs during this manoeuvre (13, 9).

Whereas the diagnosis of AARF and its classification in one of the four Fielding types can be made with certainty, the aetiology of the fixation and the anatomical aspects of the injury remain obscure because of lack of pathological data.

Indeed, a thorough review of the literature did not reveal any study pertaining to the anatomic injuries corresponding to Fielding’s classification. Moreover, on reviewing the literature, we found contradictory anatomopathological descriptions. Opinions are diverging, even about the most benign type I. For some authors, this entity includes bilateral injury of the alar ligaments (10, 14), whereas for others, there is no ligament injury at all (15, 16).

Apical odontoid ligament

In addition, while the majority of authors agree on the role of the transverse ligament as primary stabiliser of the atlanto-axial complex to prevent forward subluxation of the atlas on the axis during neck flexion, and on the role of the alar ligament to prevent excessive rotation, the role of the apical odontoid ligament is still subject to debate. For Wortzman and Dewar (18) and Rinaldi *et al* (13), the apical odontoid ligament does not seem to have any significant effect during excessive shifts of the joints. However, for Levine and Edwards (11) and Fielding and Hawkins (8), the apical ligament significantly contributes to the stability in flexion and extension. The case we have reported here may reinforce this thesis. It could illustrate a perfect relationship between pathomechanics and radiological findings. The asymmetric force applied to the right side of the occiput involved not only a rotation of the atlanto-axial complex using the contralateral C1-C2 joint as a pivot (8), but also a hyperflexion of the occipito-atloid complex. The latter mechanism could then explain the avulsion of the apical ligament. The controversial opinions in the literature could be related to difficulties in visualising the ligaments which are the primordial stabilisers of the occipitocervical junction.

Alar ligaments

Whereas injuries of the transverse ligament are easy to diagnose, thanks to CT and MRI, exploration of the alar ligament remains difficult because of its variable orientation and thickness (7). In the literature, post-traumatic rupture of the alar ligament has been described only four times. Two

cases were mentioned by Bloom *et al* (5) : CT showed the avulsion of the occipital insertion, corresponding to type III fracture of Anderson and Montesano (2). A third case was reported by Bellis *et al* (4), concerning a 9-year-old girl presenting bilateral avulsion of its dens insertion, corresponding to a type I of Anderson and D'Alonzo (1). A fourth case was described by Niibayashi (12). It is the only case where a purely ligamentous lesion was diagnosed by MRI.

While the diagnosis of alar injuries with bone avulsion is possible with computed tomography, the diagnosis of purely ligamentous lesions is not so easy. In fact, according to the proponents of computed tomography (6, 5) these injuries can be visualised by means of thin slices and soft tissue windows. However, based on their *in vivo* and *in vitro* studies, Willauschus *et al* (17) think that MRI is the best method to visualise purely ligamentous lesions of the alar ligament, because of the excellent soft tissue contrast and the free choice of the imaging plane.

REFERENCES

1. **Anderson LD, D'Alonzo RT.** Fractures of the odontoid process of the axis. *J Bone Joint Surg* 1974 ; 56-A : 1663-74.
2. **Anderson PA, Montesano PX.** Morphology and treatment of occipital condyle fractures. *Spine* 1988 ; 13 : 731-736.
3. **Arlot V, Rigault P, Padovani JP, Finidori G, Touzet Ph, Janklevicz P.** Instabilités et luxations méconnues ou négligées du rachis cervical supérieur de l'enfant. *Rev Chir Orthop* 1992 ; 78 : 300-311.
4. **Bellis YM, Linnau KF, Mann FA.** A complex atlantoaxial fracture with craniocervical instability : a case with bilateral type I dens fractures. *Am J Roentgenol* 2001 ; 176 : 978.
5. **Bloom AI, Neeman Z, Slasky BS, Floman Y, Milgrom M, Rivkind A, Bar-ziv J.** Fracture of the occipital condyles and associated craniocervical ligament injury : incidence, CT imaging and implications. *Clin Radiol* 1997 ; 52 : 198-202.
6. **Dickman CA, Greene KA, Sonntag VKH.** Injuries involving the transverse atlantal ligament : classification and treatment guidelines based upon experience with 39 injuries. *Neurosurg* 1996 ; 38 : 44-50.
7. **Dvorak J, Schneider E, Saldinger P, Rahn B.** Biomechanics of the craniocervical region : the alar and transverse ligaments. *J Orthop Res* 1988 ; 6 : 452-461.
8. **Fielding JW, Hawkins RJ.** Atlanto-axial rotatory fixation (fixed rotatory subluxation of the atlanto-axial joint). *J Bone Joint Surg* 1977 ; 59-A : 37-44.
9. **Kowalski HM, Cohen WA, Cooper P, Wisoff JH.** Pitfalls in the CT diagnosis of atlantoaxial rotary subluxation. *Am J Roentgenol* 1987 ; 149 : 595-600.
10. **Lefebvre Y, Babin SR, Clavert P., Dosch J-C, Jobard D, Bonnomet F, Simon P.** Luxation rotatoire bilatérale traumatique C1-C2 de l'adulte. *Rev Chir Orthop* 2002 ; 88 : 613-619.
11. **Levine AM, Edwards CC.** Traumatic lesions of the occipitoatlanto-axial complex. *Clin Orthop* 1989 ; 239 : 53-68.
12. **Niibayashi H.** Atlantoaxial rotatory dislocation. A case report. *Spine* 1998 ; 23 : 1494-1496.
13. **Rinaldi I, Mullins WJ Jr, Delaney WF, Fitzer PM, Tornberg DN.** Computerized tomographic demonstration of rotational atlanto-axial fixation. *J Neurosurg* 1979 ; 50 : 115-119.
14. **Robertson PA, Swan HAP.** Traumatic bilateral rotatory facet dislocation of the atlas on the axis. *Spine* 1992 ; 17 : 1252-1254.
15. **Roche CJ, O'Malley M, Dorgan JC, Carty HM.** A pictorial review of atlanto-axial rotatory fixation : key points for the radiologist. *Clin Radiol* 2001 ; 56 : 947-958.
16. **Van Holsbeeck EMA, Mackay NNS.** Diagnosis of acute atlanto-axial rotatory fixation. *J Bone Joint Surg* 1989 ; 71-B : 90-91.
17. **Willauschus WG, Kladny B, Beyer WF, Glückert K, Arnold H, Scheithauer R.** Lesions of the alar ligaments. In vivo and in vitro studies with magnetic resonance imaging. *Spine* 1995 ; 20 : 2493-2498.
18. **Wortzman G, Dewar FP.** Rotary fixation of the atlanto-axial joint : rotational atlantoaxial subluxation. *Radiology* 1968 ; 90 : 479-487.