



Range of motion in femoroacetabular impingement

Emmanuel AUDENAERT, Jan VAN HOUCKE, Bastiaan MAES, Luc VANDEN BOSSCHE, Jan VICTOR, Christophe PATTYN

From Ghent University Hospital, Ghent, Belgium

Recent epidemiological studies have demonstrated that radiographic features specific to femoroacetabular impingement appear far more frequently in healthy and asymptomatic cohorts than previously anticipated. It remains unclear how incidental findings should be interpreted clinically. In addition, several authors have suggested that a decreased range of motion is part of the clinical presentation of femoroacetabular impingement. The purpose of the present study was to describe and analyze differences in range of motion between femoroacetabular impingement patients, asymptomatic individuals with incidental radiographic findings and healthy controls, using a validated electromagnetic tracking system. Furthermore, it was evaluated which motions were clinically relevant and could be used to differentiate between these three groups. We found all evaluated motions to differ significantly between patients and controls. The anterior impingement test showed a significant difference between patients and asymptomatic cases. In conclusion, functional evaluation of the range of motion appeared in this study as a useful tool in the diagnostic work-up of femoroacetabular impingement.

Keywords : femoroacetabular impingement ; hip joint ; range of motion.

INTRODUCTION

Femoroacetabular impingement (FAI) has increasingly been recognized as a cause of painful

and decreased range of motion (ROM) of the hip joint. In particular, motions requiring high flexion in combination with adduction and/or internal rotation are most frequently affected among symptomatic patients (10). The anterior impingement test is based upon this finding and has been found positive on clinical examination in 90% to 100% of hip impingement cases (8,16,20).

On imaging, FAI has been associated with abnormal coverage of the femoral head (pincer-type impingement) and/or decreased sphericity of the femoral head (cam-type impingement). Recent epidemiological studies have demonstrated that these radiographic features appear far more frequently in healthy and asymptomatic cohorts than previously anticipated, with reported incidences ranging from

-
- Emmanuel A. Audenaert, MD, Resident.
 - Jan Van Houcke, MS, Medical Student.
 - Bastiaan Maes, MS, Medical Student.
 - Jan Victor, MD, PhD, Head of Department.
 - Christophe Pattyn, MD, PhD, Head of Clinic.
Department of Orthopaedic Surgery and Traumatology, Ghent University Hospital.
 - Luc Vanden Bossche, MD, PhD, Head of Clinic.
Department of Physical and Rehabilitation Medicine, Ghent University Hospital,
Correspondence : Emmanuel Audenaert, Department of Orthopaedic Surgery and Traumatology, Ghent University Hospital, De Pintelaan 185, 9000 Ghent, Belgium.
E-mail : emmanuel.audenaert@ugent.be
© 2012, Acta Orthopædica Belgica.
-

30 up to 76% (12,14,18). To date, the diagnosis is usually based on the co-existence of radiologic features and clinical signs such as a painful impingement test.

Several authors have suggested that a decreased ROM is part of the clinical presentation of FAI. However, objective data concerning the ROM in FAI are scarce and historical data on normal ROM, especially in male subjects, might be questioned as in those days the concept of FAI was unknown. Furthermore, internal rotation in 90 degrees of flexion, probably the most relevant motion in FAI, was never included in these historical reports (1,5,19).

The purpose of the present study was to describe and analyze differences in ROM between FAI patients, asymptomatic cases and healthy controls and to evaluate whether decreased ROM is indeed a relevant parameter in the clinical evaluation of FAI.

MATERIAL AND METHODS

The study was approved by the local ethics committee and all participants signed an informed consent form. The study population consisted of 42 subjects, prospectively recruited between 1 January 2009 and 31 March 2011. All were male subjects aged between 18 and 35 years.

The population was composed of three subgroups: cam patients (18 subjects, 24 hips), asymptomatic volunteers (12 subjects; 24 hips) and healthy controls (12 subjects, 24 hips). A minimum sample size of 11 subjects was calculated as needed to be enrolled and analyzed to identify a clinically relevant difference in the primary outcome measure, the anterior impingement test. The power analysis was based on the following parameters: type II error rate ($\beta = 0.2$) and type I error rate ($\alpha = 0.05$, $d = 10^\circ$, $\sigma = 8^\circ$).

Patients were recruited from FAI patients scheduled for treatment. All presented with typical signs of FAI, a diagnosis that later was confirmed by standard diagnostic imaging (radiography and arthro MRI) and during the actual arthroscopic procedure.

Simultaneously, healthy controls and asymptomatic cases were recruited from a cohort of healthy volunteers. Criteria for inclusion were a negative history of groin pain, the absence of clinical signs on impingement testing, and bilaterally an alpha angle of either $< 50^\circ$ (healthy controls) or $> 55^\circ$ (asymptomatic cases) on anteroposterior imaging and Dunn views (45° hip flex-

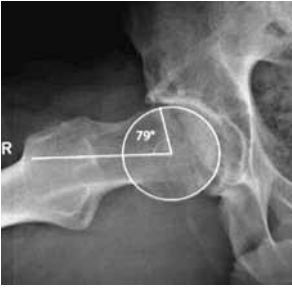


ion, neutral rotation and 20° abduction). Patients and controls with solitary pincer-type impingement (positive cross-over sign) or hip dysplasia (centre edge angle $< 28^\circ$) were excluded. An overview of the recruitment criteria is provided in table I. Different radiographic parameters describing FAI or parameters that might have an influence on the condition were measured in each subject in a standardized fashion: alpha angle, caput collum diaphyseal angle and lateral centre-edge angle.

Kinematic measurements were performed using the Fastrak electromagnetic tracking system (Polhemus, Colchester, Vt.). The system uses magnetic field pulses to track the position and orientation of individual sensors relative to a transmitter that is fixed in space. A micro-processor controls the transmitting and sensing signals and converts them into position and orientation data in 6 degrees of freedom relative to a global Cartesian coordinate system projected by the magnetic transmitter. The system specifications regarding measurement accuracy are 0.8 mm and 0.15 degrees for position and orientation, respectively. The system and applied protocol have previously been validated for use in the applied setting, i.e. the evaluation of end-range of motion positions in FAI (3).

Subjects were evaluated in supine position on a wooden investigation table, 1 m in height. No ferromagnetic materials were in significant proximity during the experiment. The transmitter was placed in close proximity to the specimen (< 0.2 m), parallel to the wooden investigation table. A femoral and pelvic sensor was simultaneously used for all experiments and data samples were obtained at a frequency of 40 Hz. The pelvic skin sensor was securely affixed over the opposite superior anterior iliac spine. The cables of the sensors were attached to the skin on the side of the trunk, so that they did not move the sensor inadvertently during the movement. To decrease measurement errors caused by skin movement, the femoral skin sensor was rigidly fixed to a specially designed distal femoral orthosis (Fig. 1).

A third receiver, equipped with a stylus, was used to digitize palpable bony landmarks on the pelvis and femur. These digitized points were used to define the local coordinate system for the pelvis and femur, which was then linked to the segment's individual receiver by means of coordinate transformations. Palpable landmarks consisted of the lateral and medial femoral epicondyles, and the anterior and posterior iliac spines. Femoral motion was then expressed in the pelvic frame, applying the segmental and joint coordinate system as advanced by the International Society of Biomechanics (21). We evaluated the range of external and

Table I. — Recruitment criteria for patients, asymptomatic cases and controls
(FAI : femoroacetabular impingement, CE-angle : Center edge angle)

Patients	Asymptomatic cases	Controls
		
Male	Male	Male
Age 18-35 years	Age 18-35 years	Age 18-35 years
History of groin pain	No history of groin pain	No history of groin pain
Painful impingement test	No pain on impingement testing	No pain on impingement testing
Alpha angle > 55°	Alpha angle > 55°	Alpha angle < 50°
CE angle between 28-40°	CE angle between 28-40°	CE angle between 28-40°
FAI confirmed on volumetric imaging and patient scheduled for treatment	Healthy volunteer	Healthy volunteer

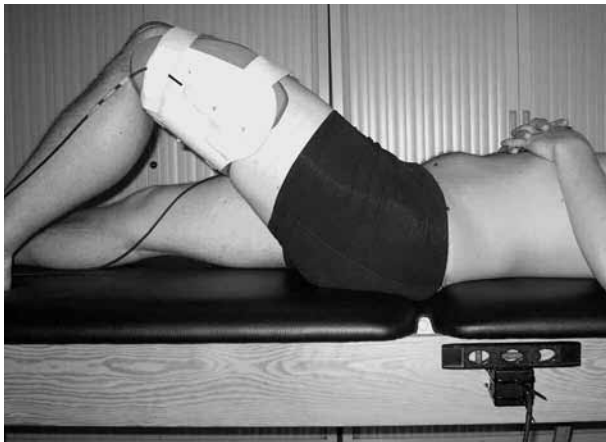


Fig. 1. — Measurement of passive femoral range of motion was performed using a distal femoral orthosis on which the femoral sensor was rigidly attached.

internal rotation, flexion, and internal rotation in 90 degrees of flexion in all cases. Each motion was repeated 10 times, the median value being retained for further analysis.

Statistical analysis was performed using the SPSS software package (SPSS 18, Chicago : SPSS Inc). To evaluate differences in kinematics between the three sub-

groups, one-way analysis of variance was performed. The necessary basic assumptions for the ANOVA analysis were evaluated by means of Levene's test for homogeneity of variances and the Kolmogorov-Smirnov test for normality of distribution. Where relevant, post-hoc evaluation was performed using Sheffe and Bonferonni tests. The level of significance was set at $p < 0.05$.

RESULTS

Demographic and radiographic data of the study population are summarized in table II.

Patients, asymptomatic cases and controls did not significantly differ in terms of height, weight and BMI. The parameter age was not normally distributed. However, analysis of variance by ranks using the Kruskal-Wallis one-way analysis demonstrated that age did not significantly differ between groups either.

When comparing ROM between patients, asymptomatic cases and controls, significant differences were found for the range of internal rotation during impingement testing as well as for the range of flexion, neutral internal and neutral external femoral rotation.

Table II. — Demographic and radiographic data of the study population (mean, standard deviation and 95% CI). CE angle : Center edge angle ; CCD angle : Caput-collum-diaphyseal angle

	Patients (n = 18 ; 24 hips)	Asymptomatic cases (n = 12 ; 24 hips)	Controls (n = 12 ; 24 hips)
Age (years)	24.7 (22.7-26.7)	22.6 (22.3-22.9)	23.1 (21.7-24.5)
Height (cm)	180 (177.1-182.9)	181.3 (179.2-183.4)	178.8 (175.7-181.9)
Weight (kg)	76.3 (72.8-79.8)	69.5 (65.9-73.1)	73.1 (68.7-77.5)
BMI (kgm-2)	23.5 (22.9-24.1)	21.1 (20.3-21.9)	22.8 (21.9-23.7)
CE angle (degrees)	33.7 (32.2-35.2)	31.9 (30.2-33.6)	33.8 (32.0-35.6)
CCD angle (degrees)	133.8 (131.8-135.8)	136.5 (133.7-139.3)	136.8 (135.4-138.2)
Alpha angle (degrees)	71.0 (68.1-73.9)	67.5 (62.9-72.1)	48.1 (46.9-49.3)**

** Difference with the patient group is significant at the 0.001 level.

Table III. — Differences between subgroups for the passive range of motion in the different motions analyzed. (Means and 95% confidence interval limits)

Motion	Patients (n = 18 ; 24 hips)	Asymptomatic cases (n = 12 ; 24 hips)	Controls (n = 12 ; 24 hips)
Neutral internal rotation	28.5 (25.7-31.3)	32.5 (30.1-34.9)	34.1(32.3-35.9)*
Neutral external rotation	28.9 (26.8-31)	38.0 (34.4-31.8)**	38.4 (34.6-42.2)**
Flexion	113.7 (109.7-117.7)	120.8 (117.2-124.4)	125.0 (120.6-129.4)**
Internal rotation In 90° of flexion	16.7 (13.5-19.8)	27.8 (25.0-30.6)**	28.0 (24.9-31.1)**

* Difference with the patient group is significant at the 0.05 level.

** Difference with the patient group is significant at the 0.001 level.

Post-hoc testing showed no significant differences in ROM between asymptomatic cases and controls.

However, compared to the control group, patients however showed significantly decreased flexion and internal rotation during impingement testing as well as decreased neutral internal and external femoral rotation ($p < 0.05$). Compared to the asymptomatic cases, they also showed significantly decreased internal rotation during impingement testing and external femoral rotation. Furthermore, there was a strong tendency towards significant differences in both flexion ($p = 0.05$) and neutral internal rotation ($p = 0.07$). Kinematic findings are summarized in table III.

DISCUSSION

FAI is a complex mechanical hip disorder defined as early and/or repetitive contact between

the acetabulum and the proximal femur. The typical osseous lesions associated with FAI can be observed on radiographs or volumetric imaging such as MRI and CT, but have been found to be also highly prevalent in asymptomatic cohorts. About a decade ago, when the concept of FAI was first introduced as a mechanical cause of osteoarthritis, the estimated prevalence was 10-15% in the general population (11,15). In recent epidemiologic studies, radiographic findings that were considered specific to the condition, appeared to have a much higher prevalence in healthy and asymptomatic study populations than previously anticipated. Kang *et al.* showed that 39% out of 100 asymptomatic hips had at least one morphological aspect predisposing to FAI (12). Laborie *et al* found cam-related radiographic features in 35% of the male participants and 10.2% of the female participants in a population-based cohort of 2,081 healthy young

adults (13). It remains unclear how the incidental finding of a cam lesion should be interpreted and whether it is indicative of prospective impingement.

Recent studies suggest that there is more to impingement than what just appears as a bump on imaging. Genetic influences have been postulated (17). The role of activity level and sports has been recognized since the earliest references to FAI in the literature and, more recently, researchers have started to focus more on general morphological conditions adding to the concept, e.g. femoral version and acetabular coverage (4). In general, one is trying to understand why some cam lesions present with impingement signs while others do not. The findings in the present study support the concept of asymptomatic cam lesions in terms of hip ROM. Kinematics in asymptomatic cases differed at no point from the control group, while clearly a number of motions were restricted in the patient group. The primary outcome measure, internal rotation at 90 degrees of flexion, was most significantly affected, supporting the hypothesis of the impingement test being the most relevant clinical measure in the diagnosis of FAI.

An intriguing finding, needing further investigation and confirmation from other research groups, is the decreased range of neutral (0 degrees of flexion) internal and external rotation in patients, compared to asymptomatic cases and controls. Using computer simulations, Audenaert *et al* previously showed both motions to be purely soft-tissue restrained, a finding consistent with anatomical literature (2,9). The results of the present study therefore potentially suggest that capsular retraction in the presence of pain and synovial irritation might be part of the clinical presentation and pathophysiology of FAI.

However, another explanation for the finding might be the occurrence of a selection bias, as the majority of patients were soccer players. Several studies have shown these athletes to commonly present with shortened hip muscles and limited joint rotation (6,7).

The present study obviously has the same limitations as those of any kinematic analysis. Measurements inaccuracy from palpation errors while defining the local reference frames and measurement errors induced by skin movements are

inevitable. On the femoral side, this is anticipated by using a specially designed femoral orthosis, but, this is not feasible for the pelvic sensor. However, previous validation of the measurement protocol showed that reliable results can be obtained up to a measurement error of 3-5°, depending on the motion under investigation.

In conclusion, the result of the present study confirm that a limited range of internal rotation during impingement testing is an important feature in the clinical presentation of hip impingement. The incidental finding of a cam lesion does not necessarily present with limited hip ROM. Neutral femoral rotation seems to be limited in FAI cases, a finding that needs further confirmation.

REFERENCES

1. **Ahlberg A, Moussa M, Al-Nahdi M.** On geographical variations in the normal range of joint motion. *Clin Orthop Relat Res* 1988 ; 234 : 229-231.
2. **Audenaert EA, Mahieu P, Pattyn C.** Three-dimensional assessment of cam engagement in femoroacetabular impingement. *Arthroscopy* 2011 ; 27 : 167-171.
3. **Audenaert EA, Vigneron L, Van Hoof T et al.** In vitro validation and reliability study of electromagnetic skin sensors for evaluation of end range of motion positions of the hip. *Med Biol Eng Comput* 2011 ; 49 : 1405-1412.
4. **Bedi A, Dolan M, Leunig M, Kelly BT.** Static and dynamic mechanical causes of hip pain. *Arthroscopy* 2011 ; 27 : 235-251.
5. **Boone DC, Azen SP.** Normal range of motion of joints in male subjects. *J Bone Joint Surg* 1979 ; 61-A : 756-759.
6. **Brophy RH, Chiaia TA, Maschi R et al.** The core and hip in soccer athletes compared by gender. *Int J Sports Med* 2009 ; 30 : 663-667.
7. **Chiaia TA, Maschi RA, Stuhr RM et al.** A musculoskeletal profile of elite female soccer players. *HSS J* 2009 ; 5 : 186-195.
8. **Clohisey JC, Knaus ER, Hunt DM et al.** Clinical presentation of patients with symptomatic anterior hip impingement. *Clin Orthop Relat Res* 2009 ; 467 : 638-644.
9. **Fuss FK, Bacher A.** New aspects of the morphology and function of the human hip joint ligaments. *Am J Anat* 1991 ; 192 : 1-13.
10. **Ganz R, Parvizi J, Beck M et al.** Femoroacetabular impingement : a cause for osteoarthritis of the hip. *Clin Orthop Relat Res* 2003 ; 417 : 112-120.
11. **Gosvig KK, Jacobsen S, Sonne-Holm S, Gebuhr P.** The prevalence of cam-type deformity of the hip joint : a survey of 4151 subjects of the Copenhagen Osteoarthritis Study. *Acta Radiol* 2008 ; 49 : 436-441.

12. **Kang AC, Gooding AJ, Coates MH et al.** Computed tomography assessment of hip joints in asymptomatic individuals in relation to femoroacetabular impingement. *Am J Sports Med* 2010 ; 38 : 1160-1165.
13. **Laborie LB, Lehmann TG, Engesaeter IO et al.** Prevalence of radiographic findings thought to be associated with femoroacetabular impingement in a population-based cohort of 2081 healthy young adults. *Radiology* 2011 ; 260 : 494-502.
14. **Jung KA, Restrepo C, Hellman M et al.** The prevalence of cam-type femoroacetabular deformity in asymptomatic adults. *J Bone Joint Surg* 2011 ; 93-B : 1303-1307.
15. **Leunig M, Ganz R.** [Femoroacetabular impingement. A common cause of hip complaints leading to arthrosis.] (in German). *Unfallchirurg* 2005 ; 108 : 12-17.
16. **Parvizi J, Leunig M, Ganz R.** Femoroacetabular impingement. *J Am Acad Orthop Surg* 2007 ; 15 : 561-570.
17. **Pollard TC, Villar RN, Norton MR et al.** Genetic influences in the aetiology of femoroacetabular impingement : a sibling study. *J Bone Joint Surg* 2010 ; 92-B : 209-216.
18. **Pollard TC, Villar RN, Norton MR et al.** Femoroacetabular impingement and classification of the cam deformity : the reference interval in normal hips. *Acta Orthop* 2010 ; 81 : 134-141.
19. **Roas A, Andersson GB.** Normal range of motion of the hip, knee and ankle joints in male subjects, 30-40 years of age. *Acta Orthop Scand* 1982 ; 53 : 205-208.
20. **Standaert CJ, Manner PA, Herring SA.** Expert opinion and controversies in musculoskeletal and sports medicine : femoroacetabular impingement. *Arch Phys Med Rehabil* 2008 ; 89 : 890-893.
21. **Wu G, Siegler S, Allard P et al.** ISB recommendation on definitions of joint coordinate system of various joints for the reporting of human joint motion – part I : ankle, hip, and spine. International Society of Biomechanics. *J Biomech* 2002 ; 35 : 543-548.