



Removal of an intra-pelvic socket : Description of a safe surgical algorithm

Liselore MAECKELBERG, Jean-Pierre SIMON, Douglas NAUDIE, Steven MACDONALD, Kristoff CORTEN

University Hospital Pellenberg, Belgium and University Hospital London Health Science Center, London, Ontario, Canada

Migration of an acetabular component beyond the ilio-ischial line is a rare but potentially lethal complication following a total hip arthroplasty, because the socket can become entrapped between the iliac vessels. Pre-operative assessment of the position of the socket relative to the intra-pelvic vascular structures is always mandatory to set up a staged procedure with a retroperitoneal exposure of the iliac vessels. This allows for a safe mobilization and looping of the vessels followed by extraction of the component either through the retroperitoneal or standard surgical approach to the hip joint. This strategy will minimize the risk of disruption of the vessels and of uncontrollable bleeding in case of vessel damage.

Keywords : intrapelvic hip socket ; removal ; retroperitoneal approach.

INTRODUCTION

Severe destruction of the peri-acetabular pelvic bone may lead to intra-pelvic migration of the acetabular component of a total hip arthroplasty (THA) beyond the ilio-ischial line. The socket may damage other intra-pelvic structures or can become entrapped between the iliac vessels. As a result, extraction of the socket under such circumstances can be very difficult and even life threatening if these anatomic structures are not adequately mobilized and protected.

The retroperitoneal approach for revision surgery of cemented sockets that have migrated into the small pelvis has been previously described (9,10).

However, cementless components are currently preferred by majority of surgeons. These sockets rely on immediate press fit fixation of the outer surface, thereby allowing for bony ingrowth. Extraction of these sockets from the small pelvis through a standard lateral or posterolateral approach can be made even more challenging because of interpenetration of the soft tissue and the rough outer surface of the cup and the presence of protruding screws or pins that can potentially damage the intra-pelvic structures during the extraction maneuver. Therefore, a thorough pre-operative assessment followed by a staged procedure with exposure, mobilization and protection of the intra- and retro-

■ Liselore Maeckelbergh, MD, Resident in Orthopaedic Surgery.

■ Kristoff Corten, MD, Orthopaedic Surgeon.

■ Jean-Pierre Simon, MD, PhD, Orthopaedic surgeon, Professor.
Department of Orthopaedic Surgery, Hip Unit, University Hospital Pellenberg, Belgium.

■ Douglas Naudie, MD, FRCS, Orthopaedic Surgeon.

■ Steven MacDonald, MD, FRCS, Orthopaedic Surgeon, Professor.
University Hospital London Health Science Center, Department of Orthopaedic Surgery, London, Ontario, Canada.

Correspondence : Kristoff Corten, Department of Orthopaedic Surgery, Hip Unit, University Hospital Pellenberg, Weligerveld 1, 3212 Pellenberg, Belgium.

E-mail : kristoff.corten@uzleuven.be

© 2012, Acta Orthopædica Belgica.

peritoneal structures is mandatory in order to safely extract these intrapelvic sockets.

We present a surgical algorithm to safely extract cementless sockets that have protruded into the small pelvis.

Illustrative Cases

– An 84-year-old female patient presented to the emergency department 6 weeks following a primary THA of the right hip for coxarthrosis. Immediate fixation of the cementless socket (Pinnacle 300, DePuy, Warsaw, USA) was provided by three spikes on its outer surface. The patient presented with an excruciating pain in the right groin region, which originated after normal walking without any traumatic event. The neurovascular status of the lower limb and groin region was normal. She had a marked shortening of the right leg. Antero-posterior radiographs of the pelvis showed that the socket had migrated beyond the ilio-ischial line, with a high suspicion of a pelvic discontinuity. This was confirmed on a Judet alar view of the right hemipelvis. A CT-angiogram showed that the external iliac artery and vein were displaced, with the spiked cup entrapped between both structures (Fig. 1).

– A 74-year-old male patient had been treated in another hospital for an acetabular Paprosky type 3C bone defect following a left THA. Revision surgery was conducted with a cementless component without screw fixation. Six weeks following surgery the socket was found to have migrated beyond the ilio-ischial line. The pelvic discontinuity was confirmed in conjunction with entrapment of the socket between the external iliac vessels on a pre-operative CT-angiogram.

– An 80-year-old female had undergone a right THA in 1989. Sixteen years later, she fell several times and presented with protrusion of the socket into the small pelvis, as a result of extensive wear that had caused a massive osteolysis of the acetabular floor and posterior column (Paprosky type 3B defect). Again, CT-angiogram revealed that the socket was in close proximity to the iliac vessels.

All three patients were successfully treated with the same surgical algorithm as described below

with an uneventful postoperative recovery. Progression from crutches to independent mobilization took place over 6 weeks to 3 months after operation. One patient developed an incisional hernia at the retroperitoneal incision six weeks after surgery but this did not require any further intervention.

All patients were planned for a staged procedure (3). In the first step, the iliac vessels were exposed and looped by a vascular surgeon. With the patient in the supine position, a limited incision was made parallel and just distal to the subcutaneous border of the anterior half of the iliac crest. The periosteum was then incised, releasing the fibers of the external oblique, internal oblique and transverse abdominal muscles. Caution was taken not to damage the lateral femoral cutaneous nerve. The iliacus muscle was then elevated from the iliac wing and the iliac vessels came into view when the iliopsoas muscle was retracted medially. First, a dissection to the external iliac artery was performed and the artery was mobilized all the way down to the common femoral artery underneath the inguinal ligament. The iliofemoral branches were preserved and the artery was circumferentially mobilized in order to ascertain that it was not adherent to the pelvic wall and the socket. The artery was then looped with a silicone loop. This would allow mobilizing the artery during socket retraction and it would also allow closing the artery in case of a tear of the main vessel or other vascular structures, which could otherwise lead to uncontrolled bleeding. In some cases, the component can already be localized and removed safely through the retroperitoneal incision. This was possible in one of our cases. After ensuring good haemostasis, the abdominal wall muscles and skin were closed with the loop left outside the wound so that it could be pulled in case of uncontrolled bleeding. In the second part of the procedure, the patient was repositioned in lateral decubitus with draping allowing for an easy access to the retroperitoneal loop. The socket could then be removed through the direct lateral or posterolateral approach after mobilization and under protection of the vessels. Finally, a reconstruction cage was used to reconstruct the acetabulum and stabilize the pelvic discontinuity (Fig. 1). A trial component was put into the acetabular defect. A trial cage was

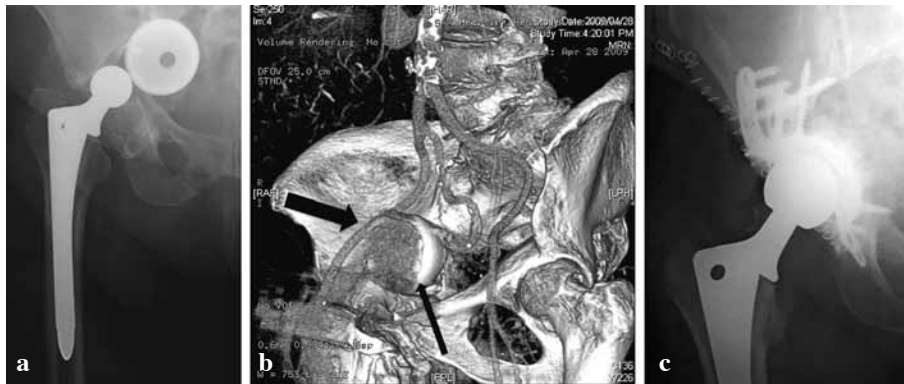

Fig. 1. — Case 1. (a) The socket had migrated beyond the ilio-ischial line. (b) The pre-op CT angiogram revealed the external iliac artery (thick arrow) had been entrapped by the socket (thin arrow). (c) The patient was treated with a cage construct after safe removal of the socket.

positioned in the ischial bony sleeve until sufficient purchase was obtained. Next, the final cage was assembled based on the trial and fixed inside the ischial bone with its inferior flange. The superior flange was fixed to the outer iliac table with several screws. Finally, a polyethylene liner was cemented into the cage with the correct anteversion and inclination angles. The hip approach wound was closed. The retroperitoneal loop was pulled out through the retroperitoneal wound without re-opening it.

DISCUSSION

When an acetabular component has protruded into the small pelvis beyond the ilio-ischial line as visualized on the AP pelvis radiograph, it can become entrapped between the external iliac vessels, and retrieval of the socket through the regular approaches without mobilizing and protecting the intra-pelvic vessels may lead to disruption and uncontrollable bleeding.

Protrusion of the socket may result from a variety of aetiologies such as aseptic loosening with severe pelvic osteolysis, a traumatic injury to a well-fixed component or excessive reaming of the acetabular bone (11). Treatment of an acetabular floor fracture with an undersized cementless component that is not well fixed to the iliac and ischial bone can also lead to protrusion of the loose socket into the small pelvis when the patient initiates weight bearing. The component can then become

entrapped between the iliac vessels. Therefore, awareness of this potentially life-threatening situation is important in case a patient presents with severe peri-acetabular pelvic defects. Good radiographic and intra-operative assessment of the bone quality is therefore mandatory and revision surgery should be planned as soon as possible in order to prevent protrusion of the socket to occur. Iliac and ischial fixation of the socket with or without a cage is mandatory because this will prevent the socket from migrating medially during load bearing.

The most important intra-pelvic structures at risk are the external iliac, obturator, superior and inferior gluteal and internal pudendal artery and vein together with the urologic structures or gastrointestinal tract. Several neurologic structures such as the obturator nerve, the superior and inferior gluteal, internal pudendal and sciatic nerve are also jeopardized and should all be carefully assessed clinically prior to the revision procedure (4,9). The external iliac artery and vein run obliquely down the medial border of the psoas muscle. A decreasing amount of iliopsoas muscle is interposed from proximal to distal between the vessels and the anterior column (5). As a result, there is only minimal soft tissue coverage at the level where the vessels are opposite to the anterior-superior acetabular quadrant. Protrusion through this quadrant, such as can happen when the anterior column has been disrupted, is therefore associated with a very high risk for vessel entrapment. The common femoral artery

and vein are the distal extensions of the external iliac vessels, after they have passed below the inguinal ligament. They course anterior to the hip joint and are separated from it by the iliopsoas tendon. The artery is found lateral to the vein at the level of the hip joint and is therefore more prone to injury. The obturator neurovascular structures are located along the acetabular quadrilateral surface. As a result, they can be damaged when the component is driven into the pelvis when e.g. a lateral force is applied to the greater trochanter. The obturator internus muscle can protect the neuro-vascular bundle because it overlies the acetabular antero-inferior quadrant. The neurovascular bundle exits the pelvis at the supero-lateral corner of the obturator foramen. The distance from the anterior inferior iliac spine to the external iliac artery and the distance from the base of the superior pubic ramus to the obturator artery is shorter in females than in males (6). In addition, the right external iliac artery is located more ventral and closer to the anterior inferior iliac spine than on the left side (6). In summary, the iliac vessels are at risk of injury when the socket protrudes through the acetabular antero-superior region whereas the obturator vessels are at risk when protrusion occurs in the antero-inferior quadrant, especially in females on the right side. The vessels can even be within a 5 mm distance of the acetabular floor quadrants and this distance tends to be smaller with advancing age (12). Special attention is thus also required for those situations where the cementless socket has maybe not fully protruded inside the small pelvis but has eroded through the acetabular floor or anterior column (Fig. 2). Similarly to the fully protruded socket, the soft tissues can become adherent to the outer surface of the socket and extraction of the socket using a conventional technique may be complicated with severe haemorrhage. Vascular complications associated with migration of the socket or adhesion of the soft tissues to the socket, consist of thrombo-embolism, vessel laceration, pseudo aneurysms and fistulas. Acute intra-operative injuries will lead to severe haemorrhage whereas injuries due to laceration of the arterial wall will cause pain induced by a false aneurysm or ischaemic symptoms due to an impaired blood flow. Urologic complications can

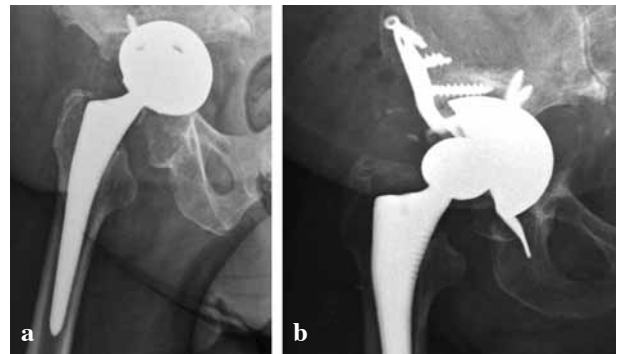


Fig. 2. — (a) A trabecular metal socket (Zimmer, Warsaw) was used to reconstruct the acetabulum following a large defect of the anterior column. The socket had migrated medially but did not completely pass the ilio-ischial line. However, extraction of these sockets can still lead to disruption of the external iliac vessels owing to penetration of the soft tissues into the trabecular metal surface and the close proximity of the vessels. Caution should therefore be taken not to disrupt the vessels and a muscle sparing, direct anterior Smith-Petersen approach with an osteotomy of the superior iliac spine provided excellent visualisation of the peri-acetabular bone, the iliopsoas muscle and the distal part of the iliac vessels. This allowed for a safe removal of the socket. (b) A reconstruction cage with fixation into the ischial bone was used because ischial fixation of the socket with screws only was not deemed stable enough. This allowed for a stable protection of the socket during ingrowth. A polyethylene liner was cemented into the cage with appropriate anteversion and inclination.

also occur, mostly after gradual erosion of tissues accounting for the development of haematuria or dyspareunia. The bladder can be disrupted, which will lead to haematuria. A gastro-intestinal fistula formation can occur (1,11). For all these reasons, it is important to set up a thorough preoperative assessment. This includes a detailed clinical examination of the neuro-vascular structures of the groin region and the lower limb along with a pre-operative CT angiogram. The angiogram will allow assessing the position of the outer surface of the socket relative to the vessels. Any impression, pseudo-aneurysm or disruption of the vessels will be evaluated. Special attention is given to the orientation of the socket and the location of pins and screws relative to the vessels (3,10). CT scans will also allow assessing the bony morphology of the involved hemipelvis in order to set up a surgical treatment plan. Peri-prosthetic joint infection should always be excluded

and a preoperative fluid aspiration of the hip joint is recommended along with urine analysis.

Removal of the migrated socket through a routine surgical approach to the hip joint has been reported to be difficult and dangerous (9). Extraction of the entrapped socket can only be safely conducted after mobilization and looping of the intrapelvic vessels for several reasons. First, adhesions from the intra-pelvic structures to the rough outer surface of the socket should be removed. Second, the vessels should be sufficiently mobilized proximally and distally to the inguinal ligament in order to minimize the tension on the vessels when the socket is being removed. Thirdly, in case any vessel disruption would occur, the looping will prevent uncontrolled bleeding to occur, which will allow for easier and safe repair of the vessels. Finally, the socket can sometimes be removed under direct vision of the vessels through the retroperitoneal approach (2). Whether the revision should be conducted during the same procedure could be debated. Eftekhar and Nercessian described a staged procedure with a 12-month interval between both stages (2). The first stage consisted of the removal of the stem through a lateral transtrochanteric approach, followed by removal of the socket through an abdominal-retroperitoneal approach with direct exposure of the intrapelvic structures. Bone grafts were then applied to the acetabular bone to increase the pelvic bone stock. One year later, the revision THA was conducted as the second stage of the treatment. Similar to Petretera *et al* we recommend a two-stage procedure in one surgical session because contemporary reconstruction techniques such as the reconstruction cages usually allow for sufficient support to the revision socket. First, the iliac vessels are identified, mobilized and looped through a retroperitoneal approach (8). The abdominal wound is packed, the patient is repositioned and a standard revision surgery is performed through a modified Hardinge lateral approach. Haemorrhage after or during removal of the socket can then be controlled through the retroperitoneal opening or simply by pulling on the loop which is left outside the retroperitoneal wound. In accordance to Reiley *et al* we also strongly advice for assistance of a vascular

surgeon during the procedure (10). We believe that this algorithm has prevented major problems to occur in our patients and allowed for early and safe weight bearing following the procedure.

In conclusion, migration of the acetabular component beyond the ilio-ischial line into the pelvis is a very rare but potentially dangerous situation. The acetabular cementless component can promote a significant soft tissue response and extensive local entrapment of adjacent neurologic, urologic and vascular structures to the porous-coated surface must be considered. Therefore, a good pre-operative assessment and surgical plan is mandatory. A two-step intervention with a retroperitoneal approach, mobilization and looping of the vessels should be performed. Retraction of the component can then be safely conducted either through the retroperitoneal approach or through any other regular surgical approach of the hip joint.

REFERENCES

1. **Bach C, Streingruber I, Ogon MB *et al*.** Intrapelvic complications after total hip arthroplasty failure. *J Bone Joint Surg* 2002 ; 183-A ; 75-79.
2. **Eftekhar N, Nercessian O.** Intrapelvic migration of total hip arthroplasty. Operative treatment. *J Bone Joint Surg* 1989 ; 71-A ; 1480-1486.
3. **Grigoris P, Robers P, Mcminn DJ, Villar RN.** A technique for removing an intrapelvic acetabular cup. *J Bone Joint Surg* 1988 ; 75-B ; 25-27.
4. **Isiklar Z, Lindsey R, Tullos HS.** Sciatic neuropathy secondary to intrapelvic migration of an acetabular cup. A case report. *J Bone Joint Surg* 1997 ; 79-A ; 1395-1397.
5. **Kambe T, Naito M, Asayama I *et al*.** Vascular anatomy for rotational acetabular osteotomy : cadaveric study. *J Orthop Science*, 2003 ; 8 : 323-328.
6. **Kirkpatrick J, Callaghan J, Vandemark RM, Goldner RD.** The relationship of the intrapelvic vasculature to the acetabulum. *Clin Orthop Relat Res* 1990 ; 258 : 183-190.
7. **Nolan DR, Fitzgerald RH Jr, Beckenbaugh RD, Coventry MB.** Complications of total hip arthroplasty treated by reoperation. *J Bone Joint Surg* 1975 ; 57-A : 977-981.
8. **Petretera P, Trakru S, Mehta S *et al*.** Revision total hip arthroplasty with a retroperitoneal approach to the iliac vessels. *J Arthroplasty* 1996 ; 11 : 704-708.
9. **Ratliff AHC.** Vascular and neurologic complications following total hip replacement. In : Salvati EA (ed). *The Hip : Proceedings of the Ninth Open Scientific Meeting of the Hip Society*. CV Mosby, St Louis, 1981.

10. **Reiley MA, Bond D, Braninck RI, Wilson EH.** Vascular complications following total hip arthroplasty. *Clin Orthop Relat Res* 1984 ; 186 : 23-28.
11. **Stiehl J.** Acetabular prosthetic protrusion and sepsis : case report and review of literature. *J Arthroplasty* 2007 ; 22 : 283-288.
12. **Wasielowski R, Cooperstein L, Kruger MP, Rubash HE.** Acetabular anatomy and the transacetabular fixation of screws in total hip arthroplasty. *J Bone Joint Surg* 1990 ; 72-A : 501-508.