



## Aneurysmal bone cyst of the spine in an adolescent : A case report

Martin GOTHNER, Mustafa CITAK, Thomas A. SCHILDHAUER, Bernd ROETMAN

*From BG-University Hospital Bergmannsheil, Ruhr-University Bochum, Germany*

**Aneurysmal bone cysts are often localized in long bones of the lower extremity and are characterized by aggressive expansion with local destruction of bone. We present the case of a 14-year-old female patient with a two weeks history of low dorsal pain. Computerized tomography (CT) scan of the spine showed local destruction of the 10<sup>th</sup> thoracic vertebra and magnetic resonance imaging (MRI) revealed a 50 percent compression of the spinal cord. The partly septated and partly solid cystic tumour in the 10<sup>th</sup> thoracic vertebra was resected and a dorsal spondylodesis stabilised the thoracic spine. Aneurysmal bone cyst should be considered in the differential diagnosis of unspecific pain of the spine. Follow-up examinations after three, five and twelve months did not show signs of recurrence.**

**Keywords :** aneurysmal bone cyst ; thoracic vertebra ; surgical treatment ; MRI ; CT.

unclear. However, preexisting bony lesions like non ossifying fibroma, osteoblastoma or haemangioma or even an injury may influence the development of an ABC. MRI and CT are the imaging modalities of choice in the diagnosis of bone cysts in the spine (7,11). However, a definitive diagnosis can be validated only via histological examination. Several treatment options have been described. Isolated radiation therapy has been associated with a high recurrence rate and followed by fractures of the vertebra (11). Surgical resection and autologous bone grafting, or the instillation of bone cement are currently the treatment options of choice (5,10).

We report a rare juvenile occurrence of ABC of the thoracic spine in a 14-year-old female patient, which has not been reported in the literature.

### INTRODUCTION

Aneurysmal bone cysts (ABC) are primarily non-malignant tumours which mostly affect individuals during their second decade of life and may occur in any bone in the body (5,9). Although benign, ABC can be locally aggressive and can lead to severe weakening of the bony structure (2). The most common localizations of ABC are the long bones such as the femur, tibia or humerus but they also occur in the pelvis and the spine. The spine is a rare and uncommon localization for an ABC (7). The aetiology and pathophysiology of ABC remain

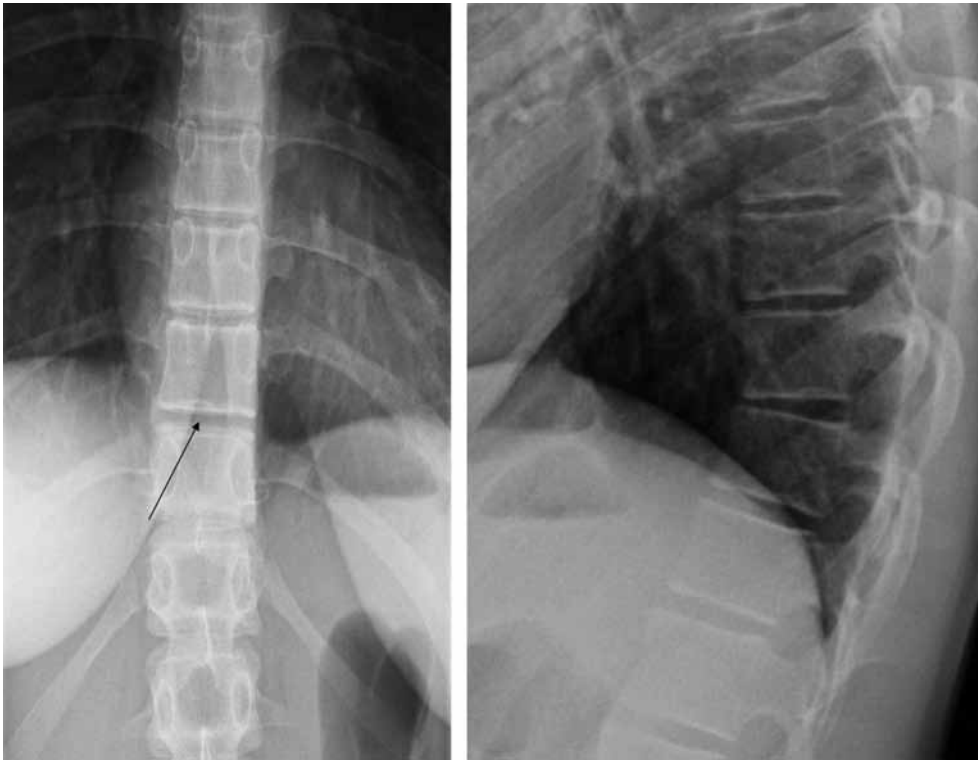
- Martin Gothner, MD, Resident.
- Mustafa Citak, MD, Resident.
- Thomas A. Schildhauer, MD, Consultant Professor.
- Bernd Roetman, MD, Consultant.

*Department of General and Trauma Surgery, BG-University Hospital Bergmannsheil, Ruhr-University Bochum, Germany.*

Correspondence : Dr. Martin Gothner, Department of General and Trauma Surgery, BG-University Hospital Bergmannsheil GmbH, Ruhr-University Bochum, Bürkle della-Camp Platz 1, 44789 Bochum, Germany.

E-mail : mgothner@gmx.de

© 2011, Acta Orthopædica Belgica.



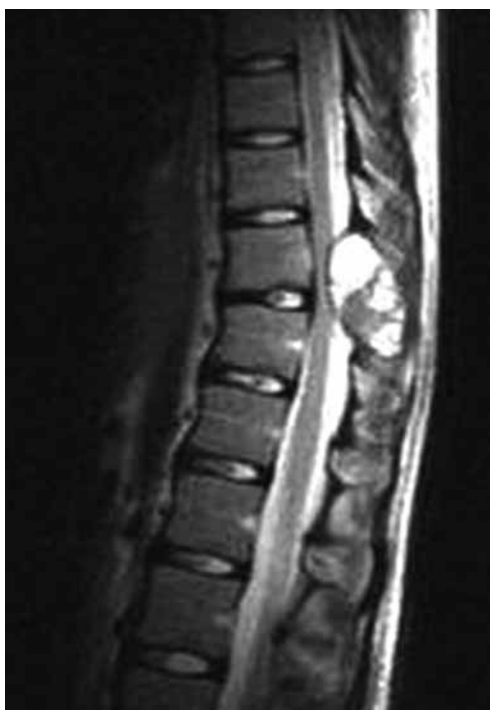**Fig. 1.** — Routine radiograph of the thoracic spine with an absent spinous process at T10 (arrow) and a minimal right convex angulation.

### CASE REPORT

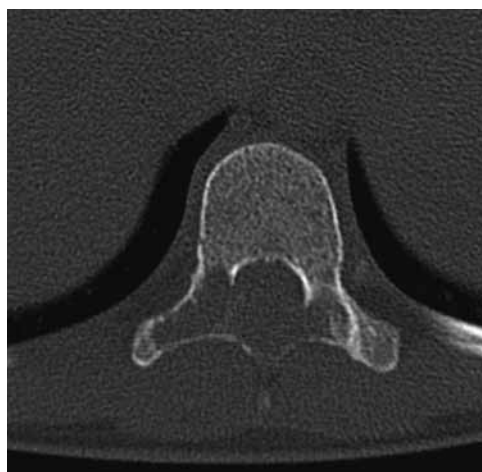
A 14-year-old athletic girl was admitted to our institution with a two-week history of unspecified back pain. She noted a tingling sensation in the feet when coughing, sneezing, and with forced flexion of the spine. Clinical examination showed a normal range of motion (ROM) in the spine. Local tenderness was found around the 10<sup>th</sup> thoracic vertebra. There was no bowel or bladder dysfunction. Laboratory investigation was normal. Routine plain radiographs of the thoracic spine showed a minimal angulation at the thoracolumbar junction. An absent spinous process and a hardly definable right pedicle of the 10<sup>th</sup> thoracic vertebral body, were highly suspicious for tumorous pathology (Fig. 1). Further diagnostic workup with magnetic resonance imaging (MRI) showed a cystic, partly solid tumour with a 50% stenosis of the spinal cord (Fig. 2). A computed tomography (CT) scan revealed a cystic

lesion with involvement of the posterior parts of the 10<sup>th</sup> vertebral body (Fig. 3). Based on the MRI findings, where the cysts typically appeared as irregularly mixed signal structures with fluid levels, and taking into account the age of the girl, the cyst was highly suspicious for an aneurysmal bone cyst and the decision for an operation was made. The tumorous lesion was resected and the thoracic spine segment from Th9 to Th11 was stabilised by resection of facets, dorsal spondylodesis and autologous bone grafting. The recovery was uneventful.

Postoperative histopathological examination revealed osseous tissue with bony transformation, increased cortical structures with fibrosis of the medullary cavity and cystic areas. Furthermore, univacuolated fat tissue and collagenic and fibrotic connective tissue were found. Osseous tissue with osteoclastic giant cells and a fibrosis of the medullary cavity were noted. Histopathological examination revealed no signs of malignancy. From



**Fig. 2.** — MRI of the thoracic spine with a cystic tumour in T10 with compression of the spinal cord.



**Fig. 3.** — Computed tomography showed cystic destruction of the posterior parts of T10.

a histopathological point of view, ABC's are normally characterized by channels and multiloculated cyst-like spaces filled with blood, lined by fibrous septa which can contain osteoclast-like giant cells, osteoid and matrix material. The histopathological findings and the typical radiological findings in our case were suggestive for a non-malignant ABC.

The girl was re-examined three, five and twelve months after the operation. Computed tomography of the thoracic spine three months postoperatively showed a beginning bony consolidation without any implant loosening or tumour recurrence (Fig. 4). Five months postoperatively the patient started with unrestricted sport activities. She remained pain free 12 months after operation.

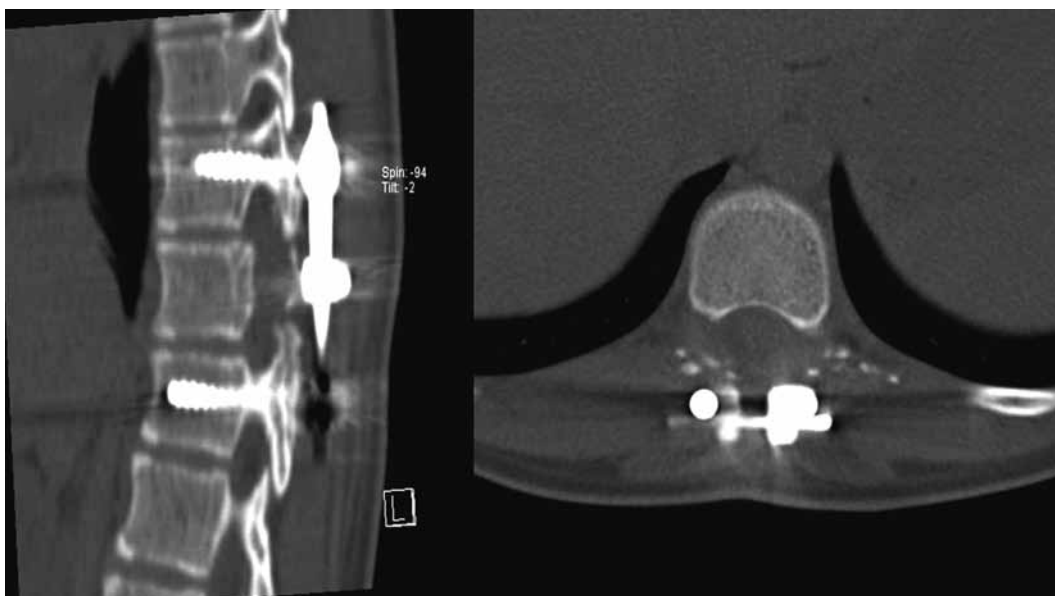
## DISCUSSION

Aneurysmal bone cyst of the spine was first described by Jaffè *et al* in 1942 (8). In long bones the bone cysts are normally localized in the diaph-

ysis or metaphysis area (11). The spine and pelvis are a rare and uncommon localization for an aneurysmal bone cyst (7). In the spine, the lumbar vertebrae are most often affected. The reported incidence in the spine varies from 3 to 20% (1,14). ABC often shows involvement of the posterior elements such as the pedicles or laminae (2,7). The female gender in the second decade of life is predominantly affected (5,13). Capanna *et al* reported a juvenile aneurysmal bone cyst of the spine with neurologic deficit (nerve root and central cord compression) (2). Aneurysmal bone cysts are primarily non-malignant, but locally aggressive tumours and can lead to severe weakening of bony structures (2). The pathogenesis is unclear (7). However, preexisting bony lesions like non ossifying fibroma, osteoblastoma or haemangioma or trauma may influence the development of the ABC. To date, genetic or neoplastic causes have not been supported by the literature (2,6,9).

In 1975, Ruitter *et al* were able to detect a high fibrinolytic activity in the fluid of the cyst. The progression of the size of the bone cyst could be explained by its high fibrinolytic activity (13).

MRI and CT are the imaging modalities of choice in the diagnosis of bone cysts in the spine (11,12). Specific radiological signs such as fluid levels or septated cysts can be helpful to



**Fig. 4.** — Postoperative computed tomography 3 months postoperatively showed a correct position of the implant with beginning bony consolidation.

underline the diagnosis. However, radiological techniques alone are not sufficient in the differential diagnosis. A definitive diagnosis can be validated only by histological examination. Sometimes a pre-operative aspiration biopsy can identify the tumour, if the aspiration fluid contains not only blood cells but also tumour cells (3).

Histology shows that the walls are lined with fibroblasts and the septated areas are built of collagenic tissue and filled with bone matrix and macrophages (3). The cysts are sometimes filled with unclotted blood, osteoid, osteoclast-like giant cells and chondroid matrix material (3). ABC's are divided into primary and secondary types. The primary type normally occurs without being associated with another primary bone tumour. The secondary lesions are associated with other tumorous lesions which may be malignant or benign (3). Giant cell tumour or osteosarcoma should be kept in mind as a differential diagnosis and a histopathological examination is essential to differentiate between benign or malignant lesions. Furthermore the diagnosis of an ABC is also suggested by clinical (age, gender) and radiological findings (fluid levels on MRI).

Several treatment options have been described and discussed in literature (2,7,11,12). At present, curettage and bone grafting are the techniques generally used (4,11,15). Radiation therapy or instillation of sclerosing substances and bone substitutes were associated with a high recurrence rate and radiation therapy was associated with fractures of the vertebra. In 1985 Capanna *et al* analysed 22 cases of aneurysmal bone cyst of the spine. The primary treatment was either radiotherapy alone or surgery, or surgery and radiotherapy combined. There was no benefit of single radiotherapy over surgical resection or over radiotherapy and surgery combined. Recurrence occurred in 4 cases after radiotherapy alone (2).

Surgical resection and autologous bone grafting or the instillation of bone cement is currently the treatment option of choice (5,11). Recurrence rates are up to 12% higher after instillation of sclerosing substances or after surgical resection followed by allogeneic bone grafting instead of autologous bone grafting (11).

There are no long-term results reported following surgical resection of aneurysmal bone cysts of the spine (2). A surgical intervention including stabi-

lization of the vertebra with a posterior spondylolysis is recommended to prevent fractures with possible neurological deficit (2). Radiotherapy alone is associated with a high recurrence rate.

Currently, the aetiology and pathogenesis of ABC remain unclear. Possible differential diagnosis should include a malignant giant cell tumour, osteoblastoma or osteosarcoma. In cases of unspecific pain of the spine in adolescents without a history of trauma, aneurysmal bone cyst should be considered in the differential diagnosis. In such cases, a radiological imaging should be performed routinely. MRI is helpful in case of suspicious standard radiographs. Computed tomography scan can help to optimize the preoperative planning.

#### REFERENCES

1. **Biesecker JL, Marcove RC, Huvos AG, Mike V.** Aneurysmal bone cysts. A clinicopathologic study of 66 cases. *Cancer* 1970 ; 26 : 615-625.
2. **Capanna R, Albisinni U, Picci P et al.** Aneurysmal bone cyst of the spine. *J Bone Joint Surg* 1985 ; 67-A : 527-531.
3. **Creager AJ, Madden CR, Bergman S, Geisinger KR.** Aneurysmal bone cyst : fine-needle aspiration findings in 23 patients with clinical and radiologic correlation. *Am J Clin Pathol* 2007 ; 128 : 740-745.
4. **Dormans JP, Hanna BG, Johnston DR, Khurana JS.** Surgical treatment and recurrence rate of aneurysmal bone cysts in children. *Clin Orthop Relat Res* 2004 ; 421 : 205-211.
5. **Frangen TM, Pennekamp W, Kuhnen C et al.** [Aneurysmal bone cysts. First description of the extensive destruction of the upper cervical spine.] (in German). *Unfallchirurg* 2007 ; 110 : 640-644.
6. **Freiberg AA, Loder RT, Heidelberger KP, Hensinger RN.** Aneurysmal bone cysts in young children. *J Pediatr Orthop* 1994 ; 14 : 86-91.
7. **Hay MC, Paterson D, Taylor TK.** Aneurysmal bone cysts of the spine. *J Bone Joint Surg* 1978 ; 60-B : 406-411.
8. **Jaffe HL, Lichtenstein L.** Solitary unicameral bone cyst : With emphasis on the roentgen picture, the pathologic appearance and the pathogenesis. *Am Med Assoc* 1942 ; 44 : 1004-1025.
9. **Leithner A, Machacek F, Haas OA et al.** Aneurysmal bone cyst : a hereditary disease ? *J Pediatr Orthop* 2004 ; 13-B : 214-217.
10. **Lichtenstein L.** Aneurysmal bone cyst ; observations on fifty cases. *J Bone Joint Surg* 1957 ; 39-A : 873-882.
11. **Mankin HJ, Hornicek FJ, Ortiz-Cruz E, Villafuerte J, Gebhardt MC.** Aneurysmal bone cyst : a review of 150 patients. *J Clin Oncol* 2005 ; 23 : 6756-6762.
12. **Ozaki T, Halm H, Hillmann A, Blasius S, Winkelmann W.** Aneurysmal bone cysts of the spine. *Arch Orthop Trauma Surg* 1999 ; 119 : 159-162.
13. **Ruiter DJ, Lindeman J, Haverkate F, Hegt VN.** Fibrinolytic activity in aneurysmal bone cysts. *Am J Clin Pathol* 1975 ; 64 : 810-816.
14. **Tillman BP, Dahlin DC, Lipscomb PR, Stewart JR.** Aneurysmal bone cyst : an analysis of ninety-five cases. *Mayo Clin Proc* 1968 ; 43 : 478-495.
15. **Vergel De Dios AM, Bond JR, Shives TC, McLeod RA, Unni KK.** Aneurysmal bone cyst. A clinicopathologic study of 238 cases. *Cancer* 1992 ; 69 : 2921-2931.