



Clinical and radiographic results after treatment of cervical degenerative disc disease with the Bryan disc prosthesis : A prospective study with 2-year follow-up

Quanming WANG, Hongbing CHENG, Zhixiang MAO, Xinsheng QI, Meng ZHANG, Yun CHEN

From the Fourth Affiliated Hospital of Suzhou University, Wuxi, China

The purpose of this study was to prospectively evaluate the clinical and radiographic results obtained with the Bryan disc prosthesis (Medtronic Sofamor Danek, Memphis, TN) in 20 consecutive patients with single-level or two-level cervical degenerative disc disease. All patients were followed up for at least two years. The mean Neck Disability Index and the visual analogue scale for neck and arm pain scores were significantly reduced for all postoperative periods compared with the mean preoperative values. SF-36 outcome measures, including the physical and mental component scores, significantly improved after surgery and remained unchanged or improved at two years postoperatively. According to Odom's scale, 18 patients (90%) had good to excellent outcomes. The range of movement of the cervical spine, of the functional spinal unit, the treated segment and the adjacent segment temporarily decreased at the early assessment, but all recovered to preoperative levels over a 6-24 months time period. There was no heterotopic ossification at the implanted levels, no adjacent level degeneration and no prosthesis subsidence or excursion. Cervical disc replacement using the Bryan disc prosthesis appeared to be safe and demonstrated encouraging clinical and radiological outcomes. However, further studies are required to assess the long-term efficacy of this prosthesis and its protective influence on adjacent levels.

Keywords : cervical spine ; degenerative disc disease ; disc replacement ; Bryan disc.

INTRODUCTION

Anterior cervical discectomy and fusion (ACDF) was pioneered in 1955 by Robinson and Smith (20) to treat radiculopathy and/or myelopathy resulting from cervical degenerative spondylosis. Despite the fact that clinical results after ACDF are generally in the good to excellent range, one negative consequence of fusion after anterior cervical decompression is the development of symptomatic adjacent segment degeneration (ASD), which typically manifests as new-onset radicular and/or myelopathic symptoms (12,13,15). It has been postulated that a

-
- Quanming Wang, PhD, MD, Orthopaedic Resident.
 - Zhixiang Mao, MD, Professor of Orthop. Surgery.
 - Xinsheng Qi, MD, Professor of Orthop. Surgery.
Department of Orthopaedic Surgery, The Fourth Affiliated Hospital of Suzhou University, Wuxi, Jiangsu Province, China.
 - Hongbing Cheng, MD, Professor of Orthop. Surg.
 - Yun Chen, MD, Orthopaedic Resident.
Department of Orthopaedic Surgery, Nantong Hospital of Chinese Medicine, Nantong, Jiangsu Province, China.
- Correspondence : Xinsheng Qi, Department of Orthopaedic Surgery, The Fourth Affiliated Hospital of Suzhou University, Huihe Street 200, Wuxi, Jiangsu Province, China, 214062.
E-mail : wxsygk@yahoo.com.cn
© 2011, Acta Orthopædica Belgica.
-

fusion procedure produces increased stress on the discs above and below the fusion-level, resulting in disc herniation and further progression of degenerative disease (4,5,7,17,25).

Cervical disc replacement (CDR) has emerged as a promising alternative to ACDF with several theoretical advantages, including segmental motion preservation, the maintenance of adjacent level kinematics, the avoidance of ASD, reconstruction of the cervical sagittal alignment, and an early return to function. The short-term clinical results of CDR for the treatment of symptomatic cervical disc degeneration are promising (1,6,10). However, there are scarce data in the literature at this time to support this statement. The authors describe the clinical and radiographic results of CDR using the Bryan disc prosthesis (Medtronic Sofamor Danek, Memphis, TN, USA) for the treatment of patients with single-level or two-level cervical disc degenerative disease.

MATERIALS AND METHODS

The Bryan disc is a single-piece, metal-on-polymer, unconstrained device, which was first implanted by Goffin in Leuven, Belgium, in January 2000. It comprises a polycarbonate/polyurethane core between two porous coated titanium endplate shells encapsulated by a polymer sheath. The instantaneous axis of rotation is variable and not limited by the geometry of articulating surfaces, a characteristic which is typical of two-piece disc designs. The purpose of the polyurethane sheath is to contain debris and prevent soft tissue ingrowth (18).

Between January 2007 and July 2008, 20 consecutive patients underwent CDR with the Bryan disc prosthesis at two institutions. Patients were 13 males and 7 females with a mean age of 46.5 years (range : 36-64 years). Inclusion criteria were : single-level or two-level disc herniation or spondylosis with radiculopathy and/or myelopathy which had not responded to conservative treatment. Exclusion criteria were : previous cervical procedures, significant cervical anatomic deformity, radiographic signs of instability, active infection and implantations below C6 (for radiological reasons). The mean duration of symptoms was 18.6 months (range : 8-34 months). All patients were followed up for at least two years postoperatively.

The surgical technique consisted of a conventional anterior cervical approach and discectomy. Sub-

sequently, a simple system was used to establish the center of the disc space. A milling fixture was positioned appropriately and affixed to the vertebral bodies with bone anchors. The milling fixture precisely controlled the locations of the powered cutting instruments while preparing the vertebral body endplates for placement of the prosthesis. The milled concavity of the vertebral endplates exactly matched the geometry of the implant's convex outer surface, thereby capturing the rim of each shell inside a ridge of bone. Insertion of a Bryan prosthesis of suitable size (14-18 mm) was accomplished under lateral fluoroscopy to ensure an adequate depth. Appropriate placement of the prosthesis was confirmed with anteroposterior and lateral fluoroscopic imaging. Postoperatively, a soft cervical collar was worn for 4 weeks. Patients were allowed to move in their collars as tolerated. Non-steroidal anti-inflammatory drugs (NSAIDs) were routinely administered for two weeks after surgery to avoid heterotopic ossification.

Preoperative demographic data, surgical data, and outcome data were prospectively collected. The clinical outcome tools included a neck and arm pain visual analogue scale (VAS), a Neck Disability Index (NDI), the SF-36 and Odom's scale. Outcome assessments were completed before surgery and postoperatively at 1, 6, 12, and 24 months. Lateral flexion-extension radiographs in the standing position were obtained before surgery and at all follow-up intervals to determine the angular motion at the following levels : the functional spinal unit, the instrumented level, the adjacent cranial level, the adjacent caudal level, and the C2-C6 area. Level C6 was chosen as the distal endpoint for the total cervical spine because the failure to adequately visualize C7-T1 in many patients precluded reliable measurements of the C2-C7 Cobb angle. Radiographic signs of cervical disc degeneration at the adjacent levels were assessed according to the Kellgren classification (14). A paired t-test, using SPSS version 13.0, was performed to measure the statistical significance of postoperative score changes from the preoperative values for NDI, neck and arm VAS, and SF36 (PCS and MCS). SPSS was also used for the analysis of motion scores at the target level when a change from the preoperative motion was recorded. A p value less than 0.05 was considered to be significant.

RESULTS

A total of 23 disc arthroplasties were performed in 20 patients. Seventeen patients received single-level,

and three received two-level Bryan replacements. The following discs were replaced: C3C4 (4 or 17.4%), C4C5 (7 or 30.4%), C5C6 (12 or 52.5%). The diagnosis was radiculopathy with axial neck pain in 1 patient (5%), combined radiculopathy and myelopathy in 3 patients (15%), and myelopathy in 16 patients (80%). The mean operative time for a single-level disc replacement was 130 ± 45 minutes and 160 ± 36 minutes for a two-level disc replacement. The mean peroperative blood loss was 260 ± 50 ml. No major surgical complications were observed.

As far as function is concerned: the Neck Disability Index (NDI) significantly decreased ($p < 0.05$) at all follow-up periods: the mean score before surgery was 47.4 ± 7.3 , with a marked decline to 24.3 ± 5.8 at 1 month, 19.6 ± 5.1 at 6 months, 17.8 ± 4.4 at 12 months, and 18.3 ± 4.8 at 24 months (Fig. 1a). The mean neck VAS score significantly decreased ($p < 0.05$) from $71.3 \text{ mm} \pm 13.6$ before surgery to $28.4 \text{ mm} \pm 9.3$ at 1 month, $25.9 \text{ mm} \pm 8.9$ at 6 months, $25.3 \text{ mm} \pm 8.7$ at 12 months, and $25.6 \text{ mm} \pm 7.6$ at 24 months (Fig. 1b). The mean arm VAS score significantly decreased ($p < 0.05$) from $69.1 \text{ mm} \pm 11.7$ before surgery to $21.3 \text{ mm} \pm 8.7$ at 1 month, $19.8 \text{ mm} \pm 7.8$ at 6 months, $19.2 \text{ mm} \pm 7.2$ at 12 months, and $20.1 \text{ mm} \pm 7.1$ at 24 months (Fig. 1c). The SF-36 health survey was used to measure the patients' general health status. Values for each period were presented in the SF-36 physical component summary (PCS) and mental component summary (MCS) scores. The mean PCS (Physical Component Summary) score before surgery was 32.2 ± 6.5 followed by a significant increase ($p < 0.05$) to 41.2 ± 9.8 at 1 month, and 45.1 ± 10.2 at 6 months, then rising to 47.5 ± 10.1 at 12 months and leveling off at 47.6 ± 10.2 at 24 months. The mean MCS (Mental Component Summary) score before surgery was 33.4 ± 7.1 , and it significantly increased ($p < 0.05$) to 46.8 ± 10.1 at 1 month, to 47.1 ± 10.4 at 6 months, to 46.9 ± 9.6 at 12 months and to 47.5 ± 10.2 at 24 months (Fig. 2). According to Odom's criteria, 18 (90%) of the 20 patients were classified as having excellent or good results at the 24-month follow-up; the remaining two patients (10%) had fair outcomes.

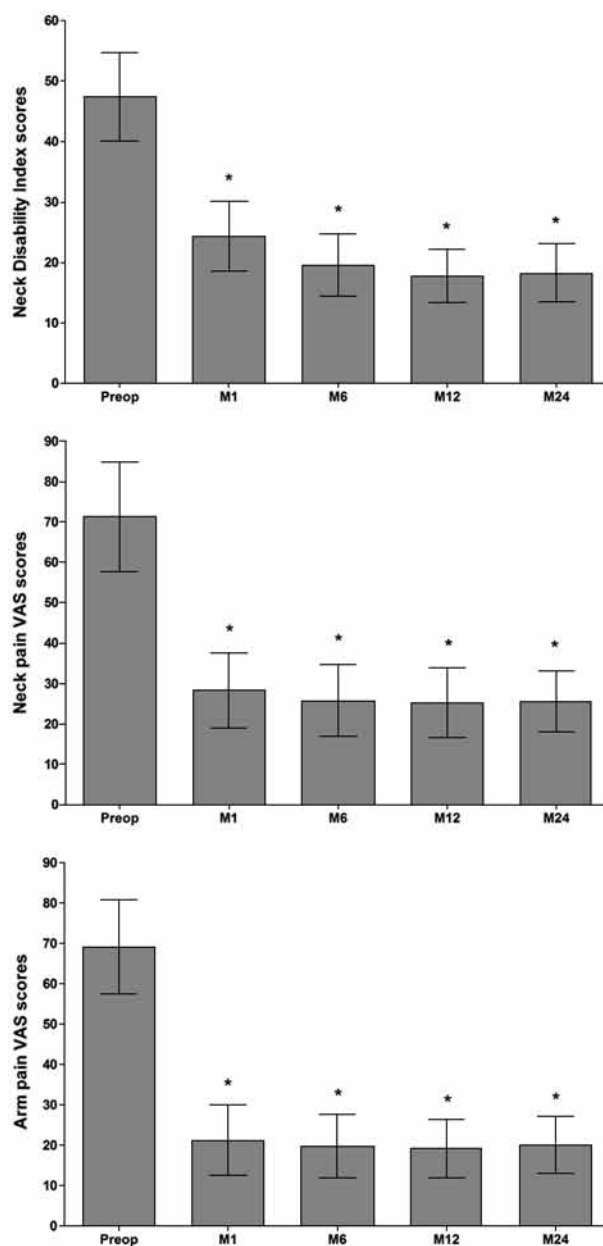


Fig. 1. — Mean scores (\pm standard deviation) of (top) Neck Disability Index, (middle) neck VAS pain, (bottom) arm VAS pain before surgery and at follow-up intervals.

* represents a significant difference ($p < 0.05$) compared with preoperative values.

Range of movement (ROM) of the cervical spine, the functional spinal unit, the treated segment, and the adjacent segments are summarized in Table I. These parameters temporarily decreased during the

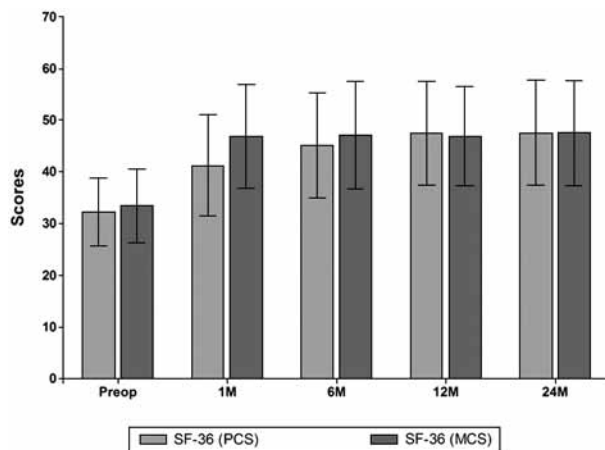


Fig. 2. — Mean SF-36 summary scores (\pm standard deviation) preoperatively and during the 24-month follow-up period. Left : PCS = Physical Component Summary ; right : MCS = Mental Component Summary.

* or ** represents a significant difference ($p < 0.05$) compared with preoperative values.

initial month after surgery, but recovered to preoperative levels at the 6 to 24-month time periods. There was no heterotopic ossification (HO) at the implanted levels, no adjacent level degeneration and no prosthesis subsidence or excursion (Fig. 3).

DISCUSSION

Initiatives promoting spinal motion-sparing technology are under way in an attempt to maintain spinal movement and to reduce strain on adjacent segments. In the lumbar spine, this technology has

been advertised as an alternative to fusion for the treatment of low back pain, and a relatively long clinical experience has been built up. CDR is the successor of anterior discectomy for the treatment of cervical degenerative disc disease ; it has a shorter clinical history than lumbar disc replacement.

Like most spinal techniques the success rate of CDR depends on proper selection of patients, correct indication, and good surgical technique. Currently, candidates for CDR are patients with normal cervical spinal alignment, physiological motion at the treated segment with no evidence of instability or hypermobility, absence of osteoporosis, and one of the following pathologic entities : disc herniation with radiculopathy or myelopathy, spondylotic radiculopathy or myelopathy, or any combination of the above. Furthermore, the potential indications for CDR continue to be refined by ongoing clinical trials. One recent study (2) estimated that 43% of surgical cervical spine patients would meet strict criteria for cervical arthroplasty, while even 47% would meet criteria if the indications were expanded to include the treatment of ASD. These results suggest that CDR has a larger potential role for the treatment of degenerative disc disease than does lumbar disc replacement.

The preliminary studies about the Prestige and Bryan discs (Medtronic Sofamor Danek, Memphis, TN), the ProDisc-C (Synthes, West Chester, PA), and the PCM (Cervitech, Roundhill, NJ) were encouraging (1,4,6,10,19,20,21). Goffin *et al* (10) reported on the early results of a multi-center study using the Bryan disc at a single level in 60 patients for the treatment of radiculopathy or myelopathy

Table I. — Range of movement of the cervical spine, functional spinal unit, treated segment and adjacent segments (degrees, mean \pm standard deviation)

Time intervals	Cervical spine (C2C6)	Functional segment unit	Implanted level	Sup. adjacent level	Inf. adjacent level
Before surgery	45.2 \pm 8.6	11.4 \pm 2.3	8.5 \pm 3.6	8.2 \pm 3.2	9.1 \pm 2.3
After 1 month	40.2 \pm 6.6*	10.1 \pm 1.6*	7.2 \pm 3.0*	7.3 \pm 2.4*	8.1 \pm 2.2*
After 6 months	45.8 \pm 8.2	11.1 \pm 2.1	8.4 \pm 3.9	8.1 \pm 3.0	9.2 \pm 2.2
After 12 months	45.1 \pm 7.5	11.4 \pm 2.3	8.6 \pm 4.1	8.2 \pm 3.1	9.4 \pm 2.2
After 24 months	45.2 \pm 7.7	11.6 \pm 2.3	8.8 \pm 4.2	8.3 \pm 3.2	9.4 \pm 2.3

* represents significant difference ($p < 0.05$) compared with preoperative values.

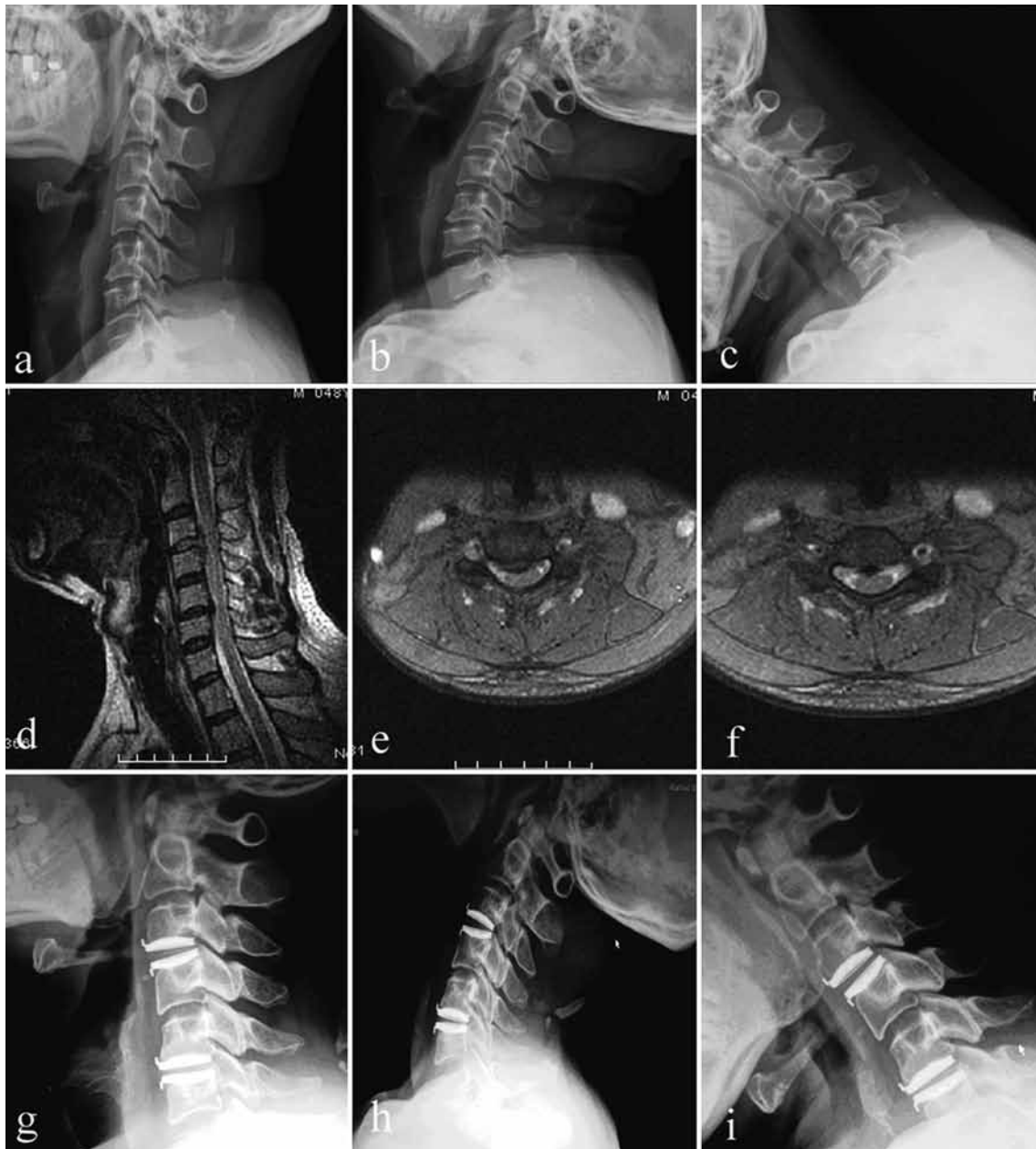


Fig. 3. — A 48-year-old man underwent a cervical disc replacement at C3C4 and C5C6. Top : preoperative neutral and flexion-extension radiographs showing initial mobility. Middle : preoperative MRI T2 reveals spinal cord compression secondary to disc herniation at C3C4 and C5C6. Bottom : 24 months postoperatively, neutral and flexion-extension radiographs demonstrate a restored range of motion without prosthesis excursion or subsidence.

due to disc herniation or spondylosis which had resisted to at least 6 weeks of conservative treatment. During the 12-month follow-up period, an 85% to 90% success rate was achieved, and no devices were revised or removed. Duggal *et al* (6)

reported on 26 patients undergoing a single-level or two-level implantation of the Bryan disc for the treatment of symptomatic cervical degenerative disc disease. A significant improvement in mean NDI and SF-36 scores was noted between the

preoperative and late postoperative follow-up assessment. Anderson *et al* (1) evaluated the clinical results of 73 patients with a minimum of 2 years of follow-up after implantation of a single-level Bryan disc. Forty-five of these patients were rated as excellent, 7 as good, and 13 as fair. Only 8 patients had a poor rating at the 2-year follow-up point. The SF-36 functional outcome assessment demonstrated significant improvement at the 3-month follow-up, and this condition remained stable for two years. Also the current study led to a significant improvement in multiple clinical outcome measures at two years after the index surgery, including the NDI, the neck and arm pain VAS, and the SF-36 PCS and MCS scores. In addition, no obvious subsidence or excursion of the prosthesis was noted. Finally, 90% of the patients had good to excellent clinical outcomes. These findings are consistent with those of previous prospective studies about cervical disc prostheses.

But the success rate for CDR in the current study was also comparable to previously published results for ACDF (fusion), in which approximately 90% of patients reported excellent or good clinical outcomes at a mean follow-up of 17 to 20 months (22, 23). In addition to a higher success rate than that achieved by ACDF, CDR using the Bryan disc prosthesis simultaneously preserved normal motion of the cervical spine. The radiological results showed that the Bryan disc prosthesis accurately replicated the preoperative ROM at the treated segment. More importantly, the ultimate ROMs of the adjacent segment, the functional spinal unit, and the cervical spine were equal to the preoperative levels. Recent biomechanical studies (4,5) have shown that CDR leads to a normalization of the load transfer to the adjacent segments by maintaining physiologic motion and kinematics, thereby reducing the rate of adjacent level degeneration when compared to fusion. The advantage of CDR in this regard was confirmed in the current study, in which there was no identification of new radiological degenerative changes or progression of existing radiological degenerative signs at adjacent levels over the course of the two years. However, it was noted that the ROM of the cervical spine decreased at the initial 1-month assessment. This may be attributed to

postoperative neck pain or the wearing of the cervical support. This temporary limitation of cervical kinematics diminished with time, and the ROM of the cervical spine recovered to preoperative levels at the 6-, 12-, and 24-month follow-up.

Several recent reports of CDR using a Bryan disc have revealed the occurrence of HO at the device-level (11,16,24). However, the aetiology of HO and the factors which induce its development remain uncertain. Many authors have demonstrated that HO following hip arthroplasty can be avoided with the prophylactic use of NSAIDs during the immediate postoperative period (8,9). Therefore, NSAID prevention was routinely administered in the current study during the first 14 postoperative days. In addition, the operative field was copiously irrigated with saline after preparing the vertebral body endplates, in an attempt to remove bone dust, because this is also thought to play an important role in the development of HO. In the current study all patients received the prophylactic protocol, and no case of HO occurred.

REFERENCES

1. Anderson PA, Sasso RC, Rouleau JP, Carlson CS, Goffin J. The Bryan cervical disc : wear properties and early clinical results. *Spine J* 2004 ; 4 (6 Suppl) : 303S-309S.
2. Auerbach JD, Jones KJ, Fras CI *et al*. The prevalence of indications and contraindications to cervical total disc replacement. *Spine J* 2008 ; 8 : 711-716.
3. Bertagnoli R, Yue JJ, Pfeiffer F *et al*. Early results after ProDisc-C cervical disc replacement. *J Neurosurg Spine* 2005 ; 2 : 403-410.
4. Chang UK, Kim DH, Lee MC *et al*. Changes in adjacent-level disc pressure and facet joint force after cervical arthroplasty compared with cervical discectomy and fusion. *J Neurosurg Spine* 2007 ; 7 : 33-39.
5. Dmitriev AE, Cunningham BW, Hu N *et al*. Adjacent level intradiscal pressure and segmental kinematics following a cervical total disc arthroplasty : an in vitro human cadaveric model. *Spine* 2005 ; 30 : 1165-1172.
6. Duggal N, Pickett GE, Mitsis DK, Keller JL. Early clinical and biomechanical results following cervical arthroplasty. *Neurosurg Focus* 2004 ; 17 : E9.
7. Eck JC, Humphreys SC, Lim TH *et al*. Biomechanical study on the effect of cervical spine fusion on adjacent-level intradiscal pressure and segmental motion. *Spine* 2002 ; 27 : 2431-2434.

8. **Fijn R, Koorevaar RT, Brouwers JR.** Prevention of heterotopic ossification after total hip replacement with NSAIDs. *Pharm World Sci* 2003 ; 25 : 138-145.
9. **Fransen M, Neal B.** Non-steroidal anti-inflammatory drugs for preventing heterotopic bone formation after hip arthroplasty. *Cochrane Database Syst Rev* 2004 : CD001160.
10. **Goffin J, Casey A, Kehr P et al.** Preliminary clinical experience with the Bryan Cervical Disc Prosthesis. *Neurosurgery* 2002 ; 51 : 840-845.
11. **Goffin J, Van Calenberg F, van Loon J et al.** Intermediate follow-up after treatment of degenerative disc disease with the Bryan Cervical Disc Prosthesis : single-level and bi-level. *Spine* 2003 ; 28 : 2673-2678.
12. **Hilibrand AS, Carlson GD, Palumbo MA, Jones PK, Bohlman HH.** Radiculopathy and myelopathy at segments adjacent to the site of a previous anterior cervical arthrodesis. *J Bone Joint Surg* 1999 ; 81-A : 519-528.
13. **Ishihara H, Kanamori M, Kawaguchi Y, Nakamura H, Kimura T.** Adjacent segment disease after anterior cervical interbody fusion. *Spine J* 2004 ; 4 : 624-628.
14. **Kettler A, Wilke HJ.** Review of existing grading systems for cervical or lumbar disc and facet joint degeneration. *Eur Spine J* 2006 ; 15 : 705-718.
15. **Kulkarni V, Rajshekhar V, Raghuram L.** Accelerated spondylosis changes adjacent to the fused segment following central cervical corpectomy : magnetic resonance imaging study evidence. *J Neurosurg* 2004 ; 100 (1 suppl Spine) : 2-6.
16. **Leung C, Casey AT, Goffin J et al.** Clinical significance of heterotopic ossification in cervical disc replacement : a prospective multicenter clinical trial. *Neurosurgery* 2005 ; 57 : 759-763.
17. **Matsunaga S, Kabayama S, Yamamoto T et al.** Strain on intervertebral discs after anterior cervical decompression and fusion. *Spine* 1999 ; 24 : 670-675.
18. **Phillips FM, Garfin SR.** Cervical disc replacement. *Spine* 2005 ; 30 : (17 Suppl) S27-S33.
19. **Pimenta L, McAfee PC, Cappuccino A, Bellera FP, Link HD.** Clinical experience with the new artificial cervical PCM (Cervitech) disc. *Spine J* 2004 ; 4 : (6 Suppl) 315S-321S.
20. **Robinson R, Smith G.** Anterolateral disc removal and interbody fusion for cervical disc syndrome. *Bull Johns Hopkins Hosp* 1955 ; 96 : 223-224.
21. **Robertson JT, Metcalf NH.** Long-term outcome after implantation of the Prestige I disc in an end-stage indication : 4-year results from a pilot study. *Neurosurg Focus* 2004 ; 17 : E10.
22. **Samartzis D, Shen FH, Matthews DK et al.** Comparison of allograft to autograft in multilevel anterior cervical discectomy and fusion with rigid plate fixation. *Spine* 2003 ; 3 : 451-459.
23. **Samartzis D, Shen FH, Goldberg EJ, An HS.** Is autograft the gold standard in achieving radiographic fusion in one-level anterior cervical discectomy and fusion with rigid anterior plate fixation ? *Spine* 2005 ; 30 : 1756-1761.
24. **Wenger M, Hoonacker P, Zachee B, Lange R, Markwalder TM.** Bryan cervical disc prostheses : preservation of function over time. *J Clin Neurosci* 2009 ; 16 : 220-225.
25. **Wigfield CC, Gill S, Nelson R, Metcalf NH, Robertson JT.** Influence of an artificial cervical joint compared with fusion on adjacent-level motion in the treatment of degenerative cervical disc disease. *J Neurosurg* 2002 ; 96 : (1 Suppl) 17S-21S.