



Total hip arthroplasty in patients less than 40 years old with avascular necrosis of the femoral head A 5 to 19-year follow-up study

Jean-Pierre SIMON, Pieter BERGER, Johan BELLEMANS

From the University Hospital Pellenberg, Belgium

We evaluated 34 total hip arthroplasties (THA) for avascular necrosis of the femoral head in 26 patients who were younger than 40 years at the time of the index operation. The average age at the time of THA was 28.3 (17-38) years. The mean follow-up was 10.9 (5-19) years. We used 6 cemented and 28 cementless acetabular components and a cemented polished tapered stem in all hips. The mean Charnley modified Merle d' Aubigné Postel score was 8.9 points pre-operatively and 16.6 points at final follow-up. Two cemented metal-backed cups were revised because of aseptic loosening at 10 years, one cemented polyethylene cup failed at 12 years and 2 more all polyethylene cups had pending failure. The metal-backed cemented cups and the all polyethylene cups had a longer follow-up than the uncemented cups. Therefore and because of the proven unfavourable long term outcome of the cemented metal-backed Exeter™ cup we are not able to draw any firm conclusions regarding the preferred choice between cemented and uncemented cups in this particular group of patients. On the femoral site none of the stems had to be revised. Our results show that a cemented polished tapered femoral component has an excellent survival in primary total hip replacement in young patients with avascular necrosis of the femoral head.

Keywords : total hip arthroplasty ; avascular necrosis ; young patients ; cemented polished stems.

INTRODUCTION

Avascular necrosis (AVN) of the femoral head is one of the main causes of early end-stage degenerative arthritis of the hip in adolescents and young adults. In developed countries AVN is estimated to be responsible for 5 to 12% of total hip arthroplasties (THA) (13). The condition may have multiple aetiologies, including traumatic and non-traumatic factors (13). The use of steroids and alcohol abuse account for 90% of the atraumatic causes (27). Ultimately THA remains the only helpful solution in advanced stages of AVN, but in the long run the intervention is associated with higher failure rates compared with THA in an older population (29,30).

-
- Jean-Pierre Simon, MD, PhD, Professor in Orthopaedics.
 - Pieter Berger, MD, Orthopaedic Resident.
 - Johan Bellemans, MD, PhD, Professor in Orthopaedics and Chairman.
Orthopaedic Department, University Hospital Pellenberg, Leuven, Belgium.
- Correspondence : Jean-Pierre Simon, University Hospital Pellenberg, Weligerveld 1, B-3212 Leuven, Belgium.
E-mail : jean-pierre.simon@uz.kuleuven.ac.be
© 2011, Acta Orthopædica Belgica.
-

Moreover it is believed that there is a difference in prognosis of THA performed for various aetiologies of AVN (11,18). Likewise the results of THA for AVN are less satisfactory compared with THA for other sources of osteoarthritis (3,6,29,33). The debate concerning the optimal fixation method of the implants and the best possible bearing combination for this young group of patients remains open (3,28,29,33,34). This study evaluates the clinical and radiographic results of THA at a medium term follow-up in patients with AVN of the femoral head who were younger than 40 years at the time of the index operation.

MATERIALS AND METHODS

The study was approved by the hospital ethics committee. Using the institutional database for THA we identified 31 patients younger than 40 years who received a THA for AVN of the femoral head (40 hips). Because the minimum cut off for follow-up was set at 5 years, 5 patients were excluded, leaving 26 patients with 34 THAs for review. There were 13 male and 13 female patients. The mean age at the time of index surgery was 32 years for male patients, and 24.5 years for female patients. The age range was from 17 to 38 years. The primary causes leading to AVN were steroid intake in 13 patients (19 hips), alcohol abuse in 2 patients (3 hips), trauma in 1 patient (1 hip), AVN following surgery for slipped capital epiphysis in 4 patients (4 hips), surgery for an aneurysmal bone cyst in 1 patient (1 hip) and idiopathic in 2 patients (3 hips). AVN was also seen after a combined femoral and pelvic osteotomy for Perthes disease in 2 patients (2 hips) and repeated surgery following septic arthritis in 1 patient (1 hip). Three patients had a previous core decompression of both hips. All operations were done through a posterolateral approach in a clean air enclosure using total body exhaust suits. Three types of uncemented acetabular components were used: 18 Morscher™ cups with a conventional polyethylene 28 mm internal bearing (Zimmer Inc, Warsaw, IN formerly Sulzer Orthopedics, Switzerland), 3 Metasul™ cups with a 28 mm metal internal bearing (Zimmer Inc, Warsaw, IN formerly Sulzer Orthopedics, Switzerland) and 7 Trilogy™ (Zimmer Inc, Warsaw, IN, USA) cups with a 28 mm conventional polyethylene bearing. In the Morscher™ cup the polyethylene is welded to the external metal mesh in order to avoid micromovements and wear between the mesh and the polyethylene. The same principle applies to the Metasul™ cup in which the poly-

ethylene is sandwiched and welded between the metal external mesh and the metal internal bearing. The Trilogy™ cup bears an internal exchangeable polyethylene liner. In addition 6 Exeter™ cemented metal backed acetabular components (Stryker Inc, Caen, France) with a 26 mm internal diameter conventional polyethylene were used. Ten femoral components were polished triple tapered cemented MS-30™ (Zimmer Inc, Warsaw, IN formerly Sulzer Orthopedics, Switzerland) stems and 24 were polished double tapered cemented Exeter™ (Stryker Inc, Caen, France) stems. Cementing technique for the femoral component included retrograde injection with a cement gun of hand mixed antibiotic cement (Simplex P™ Stryker Inc) followed by pressurization of the cement with a Sorbothane™ seal. Post-operatively immediate full weight bearing was allowed.

Follow-up was at 6 weeks, 3 months and 1 year post-operatively. Thereafter clinical and radiographic evaluation was performed every 2 to 3 years. The Charnley modification of the Merle d'Aubigné-Postel (CMA) grading system was used for clinical evaluation preoperatively and during follow-up examination (5,26). Patients were divided into functional categories A, B or C.

Radiographic assessment was performed by evaluation and comparison of serial anteroposterior radiographs of the pelvis and anteroposterior and lateral radiographs of the hip taken at each visit. The appearance and evolution of radiolucent lines between the 6 weeks and follow-up radiographs was evaluated. The classification of DeLee and Charnley was used for the cup and the method of Gruen *et al* to assess the femoral site (9,12). Grading of heterotopic ossification was performed according to Brooker *et al* (4). A Kaplan-Meier survival curve was produced in the analysis of the failure free rate. Two patients were lost to follow-up at 6 and 9 years respectively. Revision of both the femoral and acetabular component were taken as endpoint for the overall survival probability of the total hip replacement. In addition survival of both components was calculated separately. For the evaluation of the clinical scores the Wilcoxon signed rank test was used. The effects of gender, cementation, core decompression and functional group were investigated by use of a Proportional Odds Model. The significance level was set at $p < 0.05$.

RESULTS

The mean follow-up was 10.9 years (range: 5-19, SD 3.9). The median follow-up was 12 years with 5 implants having 12 years follow-up,

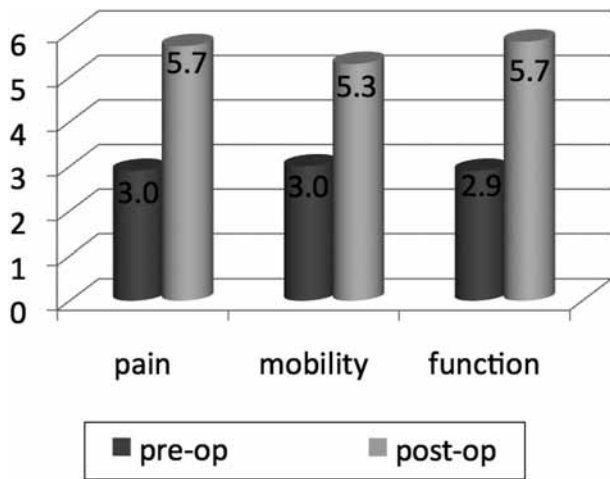


Fig. 1. — Charnley modification of the Merle d'Aubigné-Postel (CMA) pre- and postoperative scores for pain, mobility and function.

13 implants having more than 12 years follow-up and 16 implants having less than 12 years follow-up.

Functional outcome

The mean preoperative CMA score for the group as a whole was 8.9 points. When subdivided in functional category the mean preoperative CMA score was 9.3 points for patients with unilateral hip involvement, 9.1 points for patients with bilateral hip involvement and 7.9 points for patients with other conditions affecting gait. The overall postoperative CMA score for the entire group was

16.6 points, which is a significant improvement of more than 75% compared with the overall preoperative CMA score ($p < 0.001$) (Fig. 1). There was no statistically significant difference in the postoperative CMA score amongst the 3 functional categories ($p = 0.4$) (Table I). Similarly, no statistically significant differences in postoperative CMA scores were found between males and females ($p = 0.9$) and between hips that had previous core decompression and hips that had not ($p = 0.1$). The postoperative CMA score was not different for patients who had a cemented cup or a cementless cup. When classified according to aetiology there were no statistically significant differences in postoperative CMA score (Table II).

Survival analysis

Kaplan-Meier survivorship analysis, with revision of either component as end-point for failure, demonstrated an overall survival of the THAs of 95% at 10 and 90% at 15 and 19 years postoperatively. The survival rate of the stems was 100% at 10, 15 and 19 years after the index operation (Fig. 2). The overall survival rate of the cups was 100% during the first 9 years. Due to aseptic loosening of 2 cemented metal-backed cups in the tenth year, this value dropped to 95% after 10 years and further to 90% after 12 years due to an additional all polyethylene cemented cup failure (Fig. 3). When subdividing the cups between cemented cups and cementless cups the former had a survival rate of 100% throughout the whole

Table I. — Preoperative and postoperative values at latest follow-up of the Charnley modification of the Merle d'Aubigné-Postel (CMA) grading system. CMA-score for sex and functional group

| Sex | N | THA | Bilateral THA | Mean Age (years) | CMA pre-op (S.D.) | CMA post-op (S.D.) |
|--------|----|-----|---------------|------------------|-------------------|--------------------|
| Male | 13 | 17 | 4 | 31.9 | 8.9 (1.8) | 16.9 (1.2) |
| Female | 13 | 17 | 4 | 24.6 | 8.8 (1.7) | 16.3 (1.1) |
| Group | | | | | | |
| A | 9 | 9 | 0 | 23.9 | 9.3 (1.6) | 16.6 (1.1) |
| B | 11 | 16 | 5 | 30.5 | 9.1 (1.5) | 16.8 (0.9) |
| C | 6 | 9 | 3 | 28.8 | 7.9 (2.0) | 16.2 (1.6) |
| Total | 26 | 34 | 8 | 28.3 | 8.9 (1.7) | 16.6 (1.2) |

Table II. — Causes of AVN leading to THA. There were no significant differences in post-op Charnley modification of the Merle d'Aubigné-Postel (CMA) values for various aetiologies of AVN

| Cause | N | Hips | CMA post-op (S.D.) |
|-------------------|----|------|--------------------|
| Steroids | 13 | 19 | 16.3 (1.2) |
| Trauma | 1 | 1 | 18.0 (0) |
| Slipped Epiphysis | 4 | 4 | 17.0 (0.8) |
| Alcohol | 2 | 3 | 15.3 (1.5) |
| LCP | 2 | 2 | 16.5 (0.7) |
| Idiopathic | 2 | 3 | 15.0 (1.0) |
| Others | 2 | 2 | 17.0 (0) |
| Total | 26 | 34 | 16.6 (1.2) |

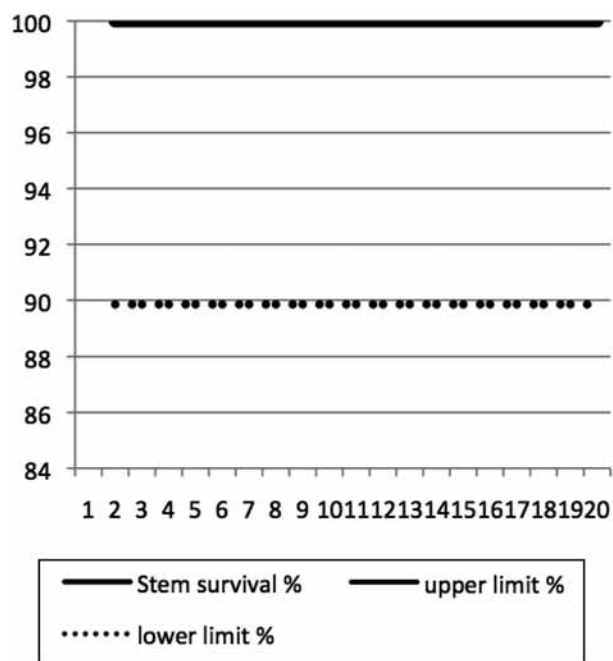


Fig. 2. — Survival analysis of the femoral component : 100% at 19 years follow-up. The upper limit coincides with 100% survival.

period, while the latter had a drop from 100% to 60% in the tenth year.

Radiographic findings

Only one stem was associated with a radiolucent line in zone 1 and 2 at 5 years follow-up and it was mildly progressive at 16 years follow-up (Table III).

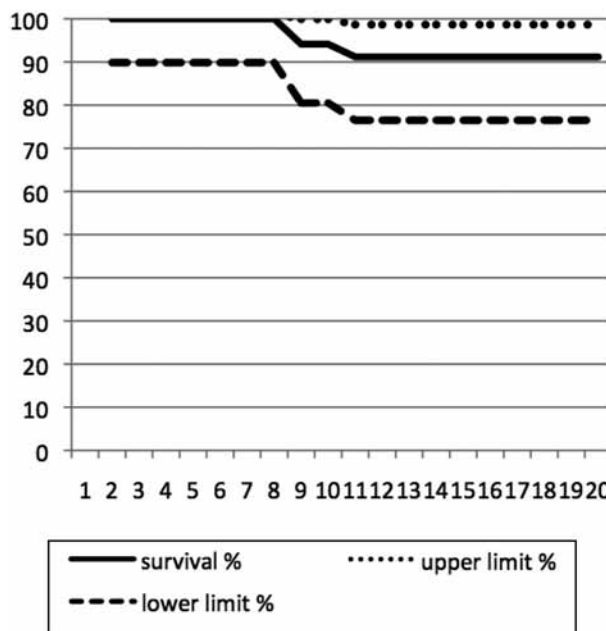


Fig. 3. — Survival analysis of the acetabular component with 95% confidence interval.

This progression was not sufficient to conclude that there was any loosening. Calcar resorption in zone 7 was not seen. In 97% of the femoral implants no radiolucent lines could be detected in the stem-cement and bone-cement interface at the time of last follow-up. Two cemented acetabular components showed definite loosening with a radiolucent line extending in all zones and progressive migration at

Table III. — Radiographic results for the acetabular and femoral component and incidence of heterotopic ossification

| Radiolucencies acetabular component | Hips |
|---|------|
| Zone I | 5 |
| Probable loosening : proximal migration without progression | 2 |
| Definite loosening : All zones + progressive migration + tilt | 3 |
| Zones II and III | 1 |
| Radiolucencies femoral component | |
| Zone 1 + 2 | 1 |
| Heterotopic ossifications | |
| Grade I | 3 |
| Grade II | 2 |
| Grade III | 1 |

10 years of follow-up. This occurred in a patient who had undergone a single stage bilateral THA. Both cups were revised to a cementless porous coated cup. All 4 remaining cemented cups had radiolucencies at the last follow-up. In addition 3 of these cups showed mild proximal migration indicating probable loosening. Two Morscher press-fit porous cups showed a radiolucent line in zone I. None of the cementless implants showed migration or other evidence of probable or definite loosening. Asymmetric cup wear was seen in 3 cups. No dislocation or loosening had occurred at the last follow-up.

Complications and revisions

Brooker grade II ossifications were seen in 2 hips. These lesions were associated with mild impairment of movement. One Brooker grade III occurred and this resulted in pain and restricted active and passive movement (Table III).

In one patient redness and swelling appeared in the scar 6 years after the index operation. This was treated with a thorough wound debridement. At latest follow-up there still remained suspicion of a deep low-grade infection of the implant.

None of the patients developed a deep venous thrombosis or pulmonary embolism.

No dislocations or periprosthetic fractures were seen. In 2 patients occasionally a feeling of subluxation was noted. Since all of the femoral components survived, no femoral revisions occurred. Two

metal-backed cemented femoral components needed revision after 10 years. Since the 4 remaining cemented cups showed radiolucent lines and 3 cups were proximally migrating the imperative conclusion is that revision is almost unavoidable for these implants.

DISCUSSION

The main concern for THA in juvenile and young patients is the almost absolute certainty for future revision. Preservation of the bone stock is therefore one of the primary concerns in this age group. To overcome these problems, more durable bearing materials have been developed. Large diameter metal-on-metal resurfacing arthroplasty has been advocated as a bone sparing procedure for young active patients. With more than ten years follow-up there is, at the present time, insufficient evidence to determine whether modern metal-on-metal resurfacing offers advantages over standard total hip arthroplasty (16,25). In addition the occurrence of high metal ion concentrations after implantation of large diameter metal-on-metal articulations raises serious concerns for their use in women during child bearing age. A further worry is the reported incidence of symptomatic and asymptomatic pseudotumours (23). Finally higher revision rates have been reported among patients who received modern metal-on-metal resurfacing arthroplasty (16,25).

The mediocre results for conventional THA in young patients are mainly due to aseptic loosening

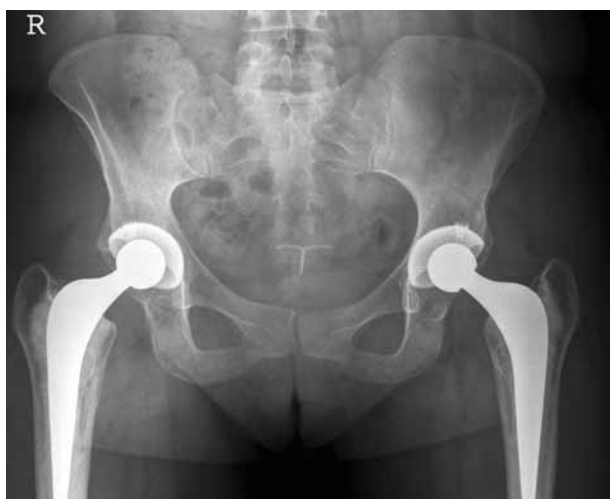

Fig. 4. — 14 year follow-up of a single stage bilateral THA for AVN due to steroid use. Bilateral Morscher™ cup and bilateral Exeter™ stem.

of the acetabular component (1,7,10). With two revisions and three pending revisions, cup failure was also the main reason for reintervention in our patients. Failure of cemented acetabular components after 12 to 15 years may vary between 22% and 33% in patients under 50 years of age (7). Uncemented porous-coated acetabular components were therefore introduced and are considered by some as a preferred choice for treatment of degenerative arthritis of the hip in young patients (2,21,30). Nevertheless, polyethylene wear remains a concern for cementless cups with conventional polyethylene (21).

The results of THA for AVN are less favourable compared with THA for other causes of osteoarthritis (3,6,29,31,33). There are several possible explanations for this. AVN of the hip affects young patients and steroid intake inhibits osteoblastic activity and increases bone resorption. Some papers suggest that steroid-induced and alcohol-related AVN are associated with a less satisfactory outcome after THA compared with other causes of AVN (6,10,11,18). Dorr *et al* identified AVN, especially alcohol-induced AVN as a negative prognostic indicator in patients younger than 40 years of age who were treated with THA (7). In addition former operative procedures can compromise the success of sub-

sequent THA in AVN hips. Therefore operations that have a low success rate, high complication rate or morbidity or compromise subsequent THA are no longer justified (8,15,19,33). Core decompression remains justified in early pre-collapse stages of AVN (27).

Second-generation cementing techniques have improved the results of cemented THA in patients with AVN. Kantor *et al* showed a survival rate of 85.7% after 10 years in 28 total hip replacements in 20 patients with non-traumatic AVN with a mean age of 55 years at surgery (15). Because of the rather disappointing initial results with cemented THA in patients with AVN of the femoral head, cementless stems became more attractive for some surgeons (12,14,21,33). Stulberg *et al*, in a study of 87 cementless THAs in 57 patients with AVN with a mean age of 41 years, reported a survival of the femoral component of 92% after 7.3 years (33). However, 16% of the revisions resulted from excessive wear of the polyethylene liner. In another more recent study, Kim *et al* compared the results of 50 third-generation cemented femoral components and 98 second-generation cementless femoral components in 98 patients with AVN with a mean age of 47.3 years (21). The survival rate with revision as an endpoint was 98% for both groups at 10 years. The same authors, in a study with the use of a ceramic-on-ceramic bearing in 93 cementless THAs in 64 patients with AVN younger than 45 years old, reported no revision or loosening after a mean follow-up of 11.1 years (20).

In this study we reviewed the results of THA in patients 40 years old or younger who received a THA for AVN of the femoral head. A limitation in the outcome is the fact that the aetiopathogenesis of the AVN was diverse. There was nevertheless a significant improvement in pain, range of motion and function after surgery in all patients and no significant differences were seen with respect to gender, functional category or past core decompression. The complication rate in the early and late post-operative stage was low. The main cause of failure was loosening of the metal-backed acetabular component. The Exeter™ metal-backed cup was introduced in 1984 and was claimed to have theoretical advantages. The design became associated with

excessive wear and early failure and the concept of metal backed cemented cups was eventually considered to be unsound (24). The cup was abandoned in 1990 in the UK, but was still promoted at that time outside the UK and was therefore still in use in our patients who now have the longest follow-up. Both the metal-backed cemented cups and the cemented all polyethylene cups had a longer follow-up than the uncemented cups. Consequently and because of the proven unfavourable long term outcome of the cemented metal-backed Exeter™ cup we cannot draw any firm conclusions regarding the preferred choice between cemented and uncemented cups in this particular group of patients. On the other hand the survival of the cemented femoral component was excellent (100%). Comparable survivals of polished tapered stems have already been reported in patients younger than 50 years with osteoarthritis of the hip and in patients under 35 years of age with inflammatory arthritis of the hip (24,32). In conclusion polished cemented femoral components have an excellent survival rate in young patients affected by AVN of the hip. Despite the development of newer implants such as modern resurfacing metal-on-metal arthroplasty with theoretical, but thus far no long-term proven benefits, we positively recommend using a cemented polished tapered stem regardless of the aetiopathogenesis of AVN of the hip in young patients.

Acknowledgements

The authors gratefully acknowledge Mr. Thomas Neyens for his assistance in the statistical analysis of the data.

REFERENCES

- Barrack RL, Mulroy RD, Harris WH.** Improved cementing techniques and femoral component loosening in young patients with hip arthroplasty. A 12-year radiographic review. *J Bone Joint Surg* 1992 ; 74-B : 385-389.
- Berger RA, Jacobs JJ, Quigley LR, Rosenberg AG, Galante JO.** Primary cementless acetabular reconstruction in patients younger than 50 years old. 7- to 11 year results. *Clin Orthop Relat Res* 1997 ; 344 : 2216-2226.
- Brinker MR, Rosenberg AG, Kull L, Galante JO.** Primary total hip arthroplasty using noncemented porous-coated femoral components in patients with osteonecrosis of the femoral head. *J Arthroplasty* 1994 ; 9 : 457-468.
- Brooker AF, Bowerman JW, Robinson RA, Riley LH.** Ectopic ossification following total hip replacement. *J Bone Joint Surg* 1973 ; 55-A : 1629-1632.
- Charnley J.** The long-term results of low-friction arthroplasty of the hip performed as a primary intervention. *J Bone Joint Surg* 1972 ; 54-B : 61-76.
- Chiu KH, Shen WY, Ko CK, Chan KM.** Osteonecrosis of the femoral head treated with cementless total hip arthroplasty. A comparison with other diagnoses. *J Arthroplasty* 1997 ; 12 : 683-688.
- Collis DK.** Long-term (twelve to eighteen-year) follow-up of cemented total hip replacements in patients who were less than fifty years old. A follow-up note. *J Bone Joint Surg* 1991 ; 73-A : 593-597.
- Davis ET, McKee MD, Waddell JP, Hupel T, Schemitsch EH.** Total hip arthroplasty following failure of free vascularized fibular graft. *J Bone Joint Surg* 2006 ; 88 : 110-115.
- DeLee JG, Charnley J.** Radiological demarcation of cemented sockets in total hip replacement. *Clin Orthop Relat Res* 1976 ; 121 : 20-32.
- Dorr LD, Kane TJ, Conaty JP.** Arthroplasty in patients 45 years old or younger. A 16-year follow-up study. *J Arthroplasty* 1994 ; 9 : 453-456.
- Dudkiewicz I, Covo A, Salai M et al.** Total hip arthroplasty after avascular necrosis of the femoral head : does etiology affect the results ? *Arch Orthop Trauma Surg* 2004 ; 124 : 82-85.
- Gruen TA, McNeice GM, Amstutz HC.** "Modes of failure" of cemented stem-type femoral components. A radiographic analysis of loosening. *Clin Orthop Relat Res* 1979 ; 141 : 17-27.
- Hamilton TW, Goodman SM, Figgie M.** SAS Weekly Rounds : Avascular Necrosis. *HSS J* 2009 ; 5 : 99-113.
- Hartley WT, McAuley JP, Culpepper WJ, Engh CA Jr, Engh CA Sr.** Osteonecrosis of the femoral head treated with cementless total hip arthroplasty. *J Bone Joint Surg* 2000 ; 82-A : 1408-1413.
- Hungerford DS.** Treatment of osteonecrosis of the femoral head : everything's new. *J Arthroplasty* 2007 ; 22 : 91-94.
- Jiang Y, Zhang K, Die J et al.** A systematic review of modern metal-on-metal total hip resurfacing vs standard total hip arthroplasty in active young patients. *J Arthroplasty* 2010 ; Epub ahead of print DOI : 10.1016/j.arth.2010.07.008
- Kantor SG, Huo MH, Huk OL, Salvati EA.** Cemented total hip arthroplasty in patients with osteonecrosis : A 6-year minimum follow-up study of second-generation cementing techniques. *J Arthroplasty* 1996 ; 9 : 267-271.
- Katz RL, Bourne RB, Rorabeck CH, McGee H.** Total hip arthroplasty in patients with avascular necrosis of the hip. Follow-up observations on cementless and cemented operations. *Clin Orthop Relat Res* 1992 ; 281 : 145-151.
- Kawasaki M, Hasegawa Y, Sakano S, Masui T, Ishiguro N.** Total hip arthroplasty after failed

- transtrochanteric rotational osteotomy for avascular necrosis of the femoral head. *J Arthroplasty* 2005 ; 20 : 574-579.
20. **Kim YH, Choi Y, Kim JS.** Cementless total hip arthroplasty with ceramic-on-ceramic bearing in patients younger than 45 years with femoral-head osteonecrosis. *Int Orthop* 2010 ; 34 : 1123-1127.
 21. **Kim YH, Oh SH, Kim JS.** Primary total hip arthroplasty with a second-generation cementless total hip prosthesis in patients younger than fifty years of age. *J Bone Joint Surg* 2003 ; 85-A : 109-114.
 22. **Kim YH, Oh SH, Kim JS, Koo KH.** Contemporary total hip arthroplasty with and without cement in patients with osteonecrosis of the femoral head. *J Bone Joint Surg* 2003 ; 85-A : 675-681.
 23. **Kwon Y-M, Ostlere SJ, Mc Lardy-Smith P et al.** "Asymptomatic" pseudotumors after metal-on-metal hip resurfacing arthroplasty. Prevalence and metal ion study. *J Arthroplasty* 2010. DOI : 10.1016/j.arth.2010.05.030. Epub ahead of print
 24. **Lewthwaite SC, Squires B, Gie GA, Timperley AJ, Ling RS.** The Exeter Universal hip in patients 50 years or younger at 10-17 years' follow up. *Clin Orthop Relat Res* 2008 ; 466 : 324-333.
 25. **Mc Grory B, Barrack R, Lachiewicz et al.** Modern metal-on-metal resurfacing. *J Am Acad Orthop Surg* 2010 ; 18 : 306-314.
 26. **Merle d'Aubigné R, Postel M.** Functional results of hip arthroplasty with acrylic prosthesis. *J Bone Joint Surg* 1954 ; 36-A : 451-475.
 27. **Mont MA, Hungerford DS.** Non-traumatic avascular necrosis of the femoral head. *J Bone Joint Surg* 1995 ; 77-A : 459-474.
 28. **Mont MA, Seyler TM, Plate J, Delanois R, Parvizi J.** Uncemented total hip arthroplasty in young patients with osteonecrosis of the femoral Head : A comparative study. *J Bone Joint Surg* 2006 ; 88-A : 104-109.
 29. **Ortiguera DJ, Pulliam IT, Cabanela ME.** Total hip arthroplasty for osteonecrosis. Matched-pair analysis of 188 hips with long-term follow-up. *J Arthroplasty* 1999 ; 14 : 21-28.
 30. **Restrepo C, Lettich T, Roberts N, Parvizi J, Hozack WJ.** Uncemented total hip arthroplasty in patients less than twenty years. *Acta Orthop Belg* 2008 ; 74 : 615-622.
 31. **Saito S, Saito M, Nishina T, Ohzono K, Ono K.** Long term results of total hip arthroplasty for osteonecrosis of the femoral head. A comparison with osteoarthritis. *Clin Orthop Relat Res* 1989 ; 244 : 198-207.
 32. **Simon JP, Maes M, Robbens E, Bellemans J.** Total hip arthroplasty in inflammatory arthritis in patients under 35 years. A 7 to 19 year follow-up. *Hip Int* 2010 ; 20 : 163-170.
 33. **Stulberg BN, Singer R, Goldner J, Stulberg J.** Uncemented total hip arthroplasty in osteonecrosis. A 2- to 10-year evaluation. *Clin Orthop Relat Res* 1997 ; 334 : 116-123.
 34. **Wangen H, Lereim P, Holm I, Gunderson R, Reikerås O.** Hip arthroplasty in patients younger than 30 years : excellent ten to 16-year follow-up with a HA coated stem. *Int Orthop* 2008 ; 32 : 203-208.