



Arthroscopic psoas release for iliopsoas impingement after total hip replacement

Anne VAN RIET, Jo DE SCHEPPER, Hendrik Pieter DELPORT

From General Hospital AZ Nikolaas, St Niklaas, Belgium

Psoas impingement is a rare cause of persisting pain after hip arthroplasty. Diagnosis is based on clinical examination and exclusion of other complications after arthroplasty by radiographs, ultrasound, CT and blood analysis. The diagnosis is strongly supported by temporary pain relief after infiltration.

When conservative measures fail, treatment can consist of a psoas tenotomy or a revision arthroplasty. When there is no obvious cause such as malpositioning for component impingement, psoas release reliably improves pain and function. This procedure is mostly performed through an open approach, which can give significant complications. An arthroscopic technique for psoas tenotomy after hip arthroplasty is described.

This report shows that this minimal invasive technique is safe and effective and allows for inspection of the implant in the same session. However, the score used did not improve in a significant way.

Keywords : psoas release ; hip arthroscopy ; arthroscopic psoas release.

can occur. They are mostly related to the surgical approach or an imbalanced hip. The psoas tendon may also be responsible for complaints after a hip arthroplasty.

Iliopsoas impingement is a complication that has been reported in 4.3% of patients (2). In most cases it is caused by a malpositioned or oversized cup or by extruding cement. When the origin of the impingement is obvious, this can be treated e.g. by revision of a malpositioned or oversized cup or by removal of extruding cement. In some cases however, there is no obvious cause for the problem (9) ; under such circumstances, a number of patients can be helped with a less invasive procedure e.g. psoas tenotomy. The latter is usually performed through an open procedure in order to evaluate the fixation of the implants and to take samples for culture and biopsy at the same time (11).

The purpose of our study was to describe the arthroscopic technique and short-term clinical outcome after arthroscopic psoas release. We

INTRODUCTION

Total hip arthroplasty is one of the most successful surgical procedures in orthopaedics. Despite this, complications still occur, the most common being aseptic loosening and infection. Fractures of the pelvis and femur are rarely the cause of persistent pain. Beside this, soft tissue problems such as tendonitis or rupture of the abductor mechanism,

- Anne Van Riet, MD, Junior registrar.
- Jo De Schepper, MD, Orthopaedic surgeon.
- Hendrik Pieter Delpport, MD, Orthopaedic surgeon.
- *Department of Orthopaedics, General Hospital AZ Nikolaas, St Niklaas, Belgium.*

Correspondence : Jo De Schepper, Regentiestraat 60, 9100 St Niklaas, Belgium. E-mail : jodeschepper@telenet.be

© 2011, Acta Orthopædica Belgica.

hypothesized that arthroscopic release of the psoas tendon after hip replacement is a safe procedure.

PATIENTS AND METHODS

Between March 2007 and October 2008 nine patients underwent an arthroscopic psoas release for persisting groin pain after hip arthroplasty. Five patients had undergone resurfacing surgery, three had undergone a total hip arthroplasty and one had a revision total hip arthroplasty. Patients were retrospectively reviewed after a mean follow-up of 11 months (range : 4-20 months). The median age at surgery was 51 years (range : 24-81 years). The psoas release took place on average 6.5 months after the hip arthroplasty (range : 1.5-11 months).

The main complaint in all patients was pain in the groin, which started 4 to 10 weeks after arthroplasty. Typical examples were pain when getting in and out of a car or when rising from a deep chair. All patients had difficulty mounting on the examination table. They all mentioned increasing activity as the cause for this problem. Clinically, every patient had weakness and pain when performing straight leg raising against resistance. No snapping could be documented.

All patients had routine radiographs, consisting of an AP view of the pelvis and an AP and Dunn view of the hip. In one patient radiographs showed a possibly oversized cup, with inferior and superior overhang, despite good bottoming out. No abnormalities, such as loosening were seen on the radiographs of the other patients. One patient was investigated by ultrasound of the hip and groin, which could not support the diagnosis of psoas impingement. A third patient underwent a CT-scan which showed lack of anterior coverage of the cup suggesting impingement of the psoas tendon. This lack of coverage was confirmed during the arthroscopic exploration of the joint. CRP and erythrocyte sedimentation rates were normal in all patients. Aspirations of the joint were done in 5 cases, but no abnormalities were found. If any doubt remained about the origin of the complaints, an infiltration of the tendon was performed. Six out of nine patients were given an infiltration of the psoas tendon with temporary improvement of the pain.

All patients were seen 10 days and 4 weeks after surgery, at which time mobility of the hip and ability to perform a straight leg raising were measured. All patients completed a Hip Osteoarthritis Outcome Score (HOOS) before and a few months after the arthroscopy. We used the HOOS because De Groot *et al* (5) validated this score in Dutch. The pre- and postoperative results of this ques-

tionnaire were statistically compared using the paired Student t-test with a 95% confidence interval. Patients were also asked about pain, functionality and postoperative complications

Operative technique

Patients are installed supine on a traction table but without applying traction to the hips. This installation makes use of fluoroscopy possible during the procedure. The operated leg is positioned in 30° of flexion to relax the anterior capsule of the hip. After disinfection and draping an anterolateral portal as described by Byrd (3) is developed, to inspect the peripheral compartment of the hip. The anterolateral portal is situated just anterosuperior to the greater trochanter. For those who are familiar with Dienst' superior anterolateral portal, the latter might be just as convenient. Prior to inserting the trocar, the hip is injected with normal saline. The injection together with the slight flexion of the hip provide enough capsular distention to get access to the peripheral compartment. This is definitely the case when one deals with a resurfaced hip where the original femoral neck is maintained. Also in case of big ball Total Hip Replacement the neocapsule can easily be distended. Standard total hip replacements are more of a challenge because of the densely scarred neocapsule. We aim with the needle for the trunion in case of a total hip and for the head neck junction in case of a resurfacing arthroplasty. A second distal anterolateral portal is made. This portal lies 6 cm distal and 1 cm anterior to the first portal. The more proximal portal is used as a working portal, while the camera is positioned in the distal one. Through this approach the borders of the prosthesis can be inspected and samples for culture can be taken (Fig. 1). After extensive shaving of a thick and scarred neocapsule, especially in case of a total hip arthroplasty, a window in the anterior capsule is made through which the psoas tendon can be inspected (Fig. 2). In case of a standard THR, a broad resection of the neocapsule may be necessary to provide enough working space. We choose to work from inside out, rather than from an area in front of the capsule to make sure that we stay in the correct plane. The tendinous portion of the psoas muscle is cut with a radiofrequency probe, while the muscular part of the muscle is left intact. It is easier to extend the leg for this part of the procedure : the tendon will be under tension and the tendinous fibres can be cut more easily. By maintaining the muscular part, the femoral nerve, lying anterior to it, is secured and the continuity of the psoas is

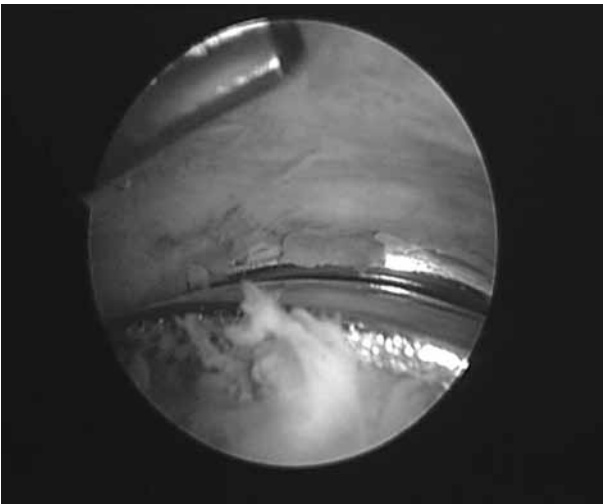


Fig. 1. — Arthroscopic view of a resurfacing arthroplasty of the hip.

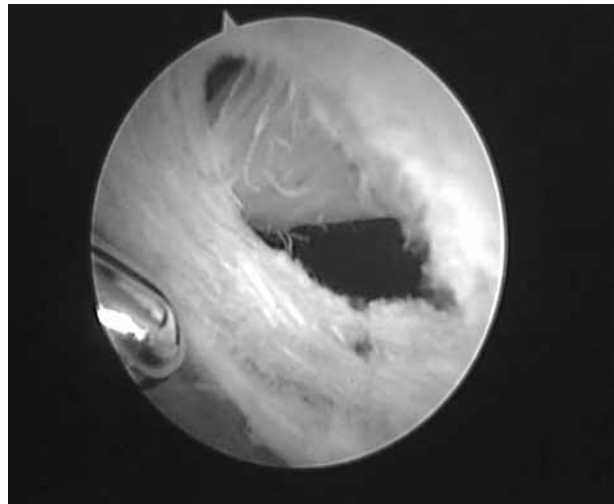


Fig. 2. — Arthroscopic view of the window in the anterior hip capsule through which the psoas tendon can be seen.

saved. This allows for quicker recovery and less flexion weakness in the first weeks after the operation.

All patients spent one night in the hospital for observation of the postoperative swelling, related with the use of large amounts of saline to inflate the joint.

Postoperatively indomethacine is prescribed for 10 days to prevent heterotopic bone formation and patients are asked to use crutches for the same period. Full body weight bearing is allowed.

RESULTS

During surgery, no signs of synovitis suggesting metal hypersensitivity were seen. In view of the current knowledge about this problem we should probably have taken synovial tissue samples routinely.

When asked about pain complaints five patients mentioned a complete relief of pain, two patients experienced intermittent mild discomfort in the groin area (see table I, case 3 and 5). Despite this, they were both able to return to their previous activity level. One of them participates in sports activities every day (mountain biking, swimming and fitness), the other has returned to his previous job as a construction worker. An eighth patient did not experience any pain during the first two weeks after arthroscopy, but gradually developed the same complaints again. The Hip Osteoarthritis Outcome

Score (HOOS) for this patient was unreliable, because of symptomatic osteoarthritis of the contralateral hip. However, he is capable of performing straight leg raising without any weakness or pain on the side of the release (case 1). The last patient, an 81-year-old lady, still reports mild, diffuse pain and difficulty with walking, which can be attributed to her advanced age.

The mean preoperative HOOS was 41 (range : 11-53) and the mean postoperative HOOS was 58 (range : 32.5-100). This difference was not significant using Student's t-test. All patients were able to perform a straight leg raising without pain or with only minor discomfort postoperatively. Clinically they all regained muscular power against resistance at the one-month control according to the Medical Research Council (MRC) Scale (Table I).

None of these patients reported any early postoperative complications. They considered hip arthroscopy as a minor procedure with little discomfort and all but one only used analgesics apart from indomethacine for 1 or 2 days.

DISCUSSION

Psoas impingement may be a cause for persistent groin pain after total hip arthroplasty (THA). Most patients present after an asymptomatic interval of a

Table I. — Data on patients

Case #	Age (yrs)	HOOS preop	HOOS postop	Hip flexion strength preop	Hip flexion strength postop	Pain with SLR*
1	36	35	35.6	3/5	5/5	none
2	59	52.5	59.37	3/5	5/5	none
3	51	33.75	53.13	3/5	5/5	mild
4	65	16.88	100	2/5	5/5	none
5	52	48.08	48.13	3/5	5/5	mild
6	24	73.75	82.5	2/5	5/5	none
7	81	63.9	68.75	2/5	5/5	mild
8	34	41	41.6	3/5	5/5	none
9	61	10.6	32.5	3/5	5/5	none

*SLR : straight leg raising.

few months to several years, but in some cases pain develops immediately after surgery. The main complaint is pain in the groin, exacerbated with activity, especially when rising from a chair or getting in and out of a car.

Palpation in the groin area is painful and pain can be provoked by straight leg raising or active flexion of the hip while sitting. Hyperextension of the hip also causes pain. Most patients are not able to perform a straight leg raise. Passive mobilization of the hip is not painful.

Other possible causes for pain after THA should of course be excluded. Infection can be identified by blood analysis (white cell count, erythrocyte sedimentation rate and C-reactive protein). Standard AP and lateral radiographs can indicate aseptic loosening or can show heterotopic ossification. When occult fractures of pelvis or hip are suspected technetium bone scintigraphy can support this diagnosis. In case of resurfacing, metal hypersensitivity should be considered and excluded if at all possible.

Psoas impingement can be suspected on standard radiographs when there is important overhang or malpositioning of the cup on an AP and Dunn view of the hip. When iliopsoas impingement is thought to cause the complaints, CT and ultrasound of the hip can assist supporting this diagnosis.

In a study by Cyteval *et al* (4) the CT findings in a group of patients with iliopsoas impingement were compared with those of a control population

and with those of patients with other complications such as infection or loosening. This study showed an acetabular overhang of more than 12 mm in all cases of impingement, while in the other groups overhang was always less than 8 mm ; they also found iliopsoas bursal effusion in half of the cases with impingement, but this was also seen in some of the cases with infection or aseptic loosening.

The next diagnostic and therapeutic step is injection of the tendon sheath and bursa with a corticoid and a local analgesic. Disappearance of pain strongly suggests psoas tendonitis to be the basic cause of the pain. In the majority of patients improvement is only temporary, but a small group of patients is cured with one or multiple injections. CT-guidance is often used to perform this procedure. Recently Nunley *et al* (10) published the results of selective injection of the iliopsoas bursa with a steroid and a local analgesic in 19 patients ; in their series 30% needed a second injection because of recurrent symptoms and surgery was eventually necessary in 20% of patients.

Although CT is considered the gold standard in imaging of psoas impingement, Rezig *et al* (12) suggested using ultrasound (US) as first-line investigation in the diagnosis. US makes it possible to evaluate overhang of the acetabular component and to visualize the presence of tendonitis and fluid effusion intra-articularly or in the iliopsoas bursa. The most important advantages of US are that it is a non-invasive, inexpensive, readily available

technique which also can be performed under dynamic conditions. Pain can be provoked by applying pressure with the probe. Because of direct visualization of the tendon, the needle for injection of an anesthetic-corticosteroid can be optimally placed, which assures a safe and effective application (1).

In most cases there is an evident mechanical factor causing friction of the psoas tendon such as an oversized cup with anterior overhang, an implant in relative retroversion, extruding cement or protrusion of the fixation screws through the iliac bone into the deep body of the psoas muscle. In some cases no obvious cause can be identified.

In a study of 2007 O'Sullivan *et al* (11) however showed no statistically significant difference in femoral offset between patients with psoas impingement and a control group. Increased femoral offset therefore could not clearly explain the inflammation of the psoas tendon. Hence some cases of psoas tendonitis after THA are still unexplained.

There are several treatment options for psoas impingement. First, a conservative treatment is recommended with rest, NSAID and stretching of the iliopsoas muscle. This usually results in only minor and temporary improvement. Secondly an infiltration with a corticosteroid and a local analgesic, possibly under CT or US guidance, can be performed. In most patients there is an immediate improvement of pain, but pain often re-occurs after a short time period. Only in a few patients was this improvement permanent (1). When infiltration gives at least temporary pain control, this strongly supports the diagnosis, so with recurrence of symptoms a surgical procedure needs to be applied.

In a recent study Dora *et al* (7) showed that psoas tenotomy has the same functional results as revision of the acetabular component, but a tenotomy has fewer complications than revision surgery. However, O'Sullivan *et al* (11) described a patient with an oversized acetabular implant as cause for psoas impingement. She was first treated with psoas tenotomy which relieved her pain for 3 months. Because pain reappeared, she underwent revision surgery which gave complete relief of pain. Therefore, it seems reasonable to correct factors

that cause impingement such as an oversized or malpositioned cup, certainly in younger patients. In cases where there appears to be no reason to perform a revision of the cup, a psoas tenotomy can give pain relief, without generating an important functional deficit (7).

Most authors choose to do the surgery through a posterior or anterolateral approach to assess the prosthesis at the same time. When there is no evidence of loosening or infection, a tenotomy is recommended. It is also possible to do the surgery through a small medial (13) or anterior (Smith-Petersen) approach (9).

Several complications have been described following open psoas release. Although the majority of them occurred in the treatment of a snapping hip, it is worth considering them in the perspective of psoas impingement after hip replacement surgery. Dobbs *et al* (6) described a modified ilioinguinal approach for release of the psoas tendon in athletes with internal snapping of the hip. Two out of nine patients had transient sensory loss of the anterolateral thigh. In a more extensive study Hoskins *et al* (8) described a 40% complication rate following open psoas release for a snapping hip. They reviewed the results of 92 procedures in 78 patients. Complications included anterior thigh paraesthesia, haematoma, superficial wound infection, hip flexor weakness persisting for more than one month and formation of a painful bursa over the lesser trochanter.

In this series of 9 patients no complications were noted and the procedure did not cause significant morbidity to the patients. Hip flexion strength returned to normal within one month after surgery. Wettstein *et al* (14) reviewed the results of arthroscopic psoas release in the treatment of a painful snapping hip. In their series of 9 patients no complications were seen in a follow-up of 9 months and the procedure did not cause loss of hip flexion strength.

Psoas tenotomy has already proven its benefit in the treatment of psoas impingement after hip arthroplasty. This arthroscopic technique seems to be as successful as an open procedure, but there is less postoperative pain because of the limited dissection needed. The risk for infection is very low

because of the small incisions and the extensive lavage of the joint. So far no postoperative complications have been seen.

Arthroscopic psoas release appeared in our experience as a safe and efficient technique in the treatment of psoas impingement after hip arthroplasty. So far we are not aware of any studies about arthroscopic psoas release after hip arthroplasty.

We acknowledge that there are some weaknesses in this study group. The small sample size and the mixed population (Resurfacing, THR and Revision THR) did not allow us to draw firm statistical conclusions.

There was no statistically significant improvement of the HOOS score postoperatively. In our opinion, these scores were low because our population was young and high demanding, except for one female patient. Moreover, the HOOS may not be specific enough to reflect an isolated dysfunction of the psoas. Additionally, some patients are in dispute with their insurance company and therefore seem to underrate their capabilities, although they perform normally in daily and professional living. The choice for the HOOS questionnaire was more driven by the language of the patients than by its specificity for psoas impingement. This again led to a lack of hard figures.

Nevertheless we recommend this procedure as safe and effective to overcome psoas impingement after hip arthroplasty, provided that all other possible causes of discomfort after such a procedure have been excluded. Further research is necessary in order to determine the potential benefits of arthroscopy over open psoas release.

REFERENCES

1. **Adler RS, Buly R, Ambrose R, Sculco T.** Diagnostic and therapeutic use of sonography-guided iliopsoas peritendinous injections. *Am J Roentgenol* 2005 ; 185 : 940-943.
2. **Bricteux S, Beguin L, Fessy MH.** Iliopsoas impingement in 12 patients with a total hip arthroplasty. *Rev Chir Orthop Réparatrice Appar Mot* 2001 ; 87 : 820-825.
3. **Byrd JWT.** Hip arthroscopy utilizing the supine position. *Arthroscopy* 1994 ; 10 : 275-280.
4. **Cyteval C, Sarrabere MP, Cottin A et al.** Iliopsoas impingement on the acetabular component : radiological and computed assisted tomography findings of a rare hip prosthesis complication in eight patients. *J Comp Ass Tomography* 2003 ; 27 : 183-188.
5. **De Groot IB, Reijman M, Terwee CB et al.** Validation of the Dutch version of the Hip Disability and Osteoarthritis Outcome Score. *Osteoarthritis Cartilage* 2007 ; 15 : 104-109.
6. **Dobbs MB, Gordon JE, Luhmann SJ, Szymanski DA, Schoenecker PL.** Surgical correction of the snapping iliopsoas tendon in adolescents. *J Bone Joint Surg* 2002 ; 84-A : 420-424.
7. **Dora C, Houweling M, Koch P, Sierra R.** Iliopsoas impingement after total hip replacement : the results of non-operative management, tenotomy or acetabular revision. *J Bone Joint Surg* 2007 ; 89-B : 1031-1035.
8. **Hoskins JS, Burd TA, Allen WC.** Surgical correction of internal coxa saltans : A 20-year consecutive study. *Am J Sports Med* 2004 ; 32 : 998-1001.
9. **Jasani V, Richards P, Wynn-Jones C.** Pain related to the psoas muscle after total hip replacement. *J Bone Joint Surg* 2002 ; 84-B : 991-993.
10. **Nunley RM, Wilson JM, Gilula L et al.** Iliopsoas bursa injections can be beneficial for pain after total hip arthroplasty. *Clin Orthop Relat Res* 2010 ; 468 : 519-526.
11. **O'Sullivan M, Tai CC, Richards S et al.** Iliopsoas tendonitis, a complication after total hip arthroplasty. *J Arthroplasty* 2007 ; 16 : 923-926.
12. **Rezig R, Copercini M, Montet X, Martinoli C, Bianchi S.** Ultrasound diagnosis of anterior iliopsoas impingement after total hip replacement. *Skeletal Radiol* 2004 ; 33 : 112-116.
13. **Taher RT, Power RA.** Iliopsoas tendon dysfunction as a cause of pain after total hip arthroplasty relieved by surgical release. *J Arthroplasty* 2003 ; 18 : 387-388.
14. **Wettstein M, Jung J, Dienst M.** Arthroscopic psoas tenotomy. *Arthroscopy* 2006 ; 22 : 907 e1-4.