



## Post impingement in posterior stabilised total knee arthroplasty

Olivier VERBORGT, Jan VICTOR

**Posterior stabilised implants are a well-proven treatment for patients requiring primary total knee arthroplasty. Concerns about the posterior stabilised (PS) design have been raised and recent studies suggest that the post-cam articulation can be an additional source of polyethylene wear debris. In this study, the authors report impingement of the tibial post against the patellar component in deep flexion in posterior stabilised total knee arthroplasty. Their data suggest that “post impingement” is associated with a raised joint line, patella infera, too anterior placement of the tibial component and a smaller femoral component size. “Post impingement” may lead to extensor mechanism problems and additional polyethylene wear and therefore may affect the long-term functional results of posterior stabilised total knee arthroplasty.**

### INTRODUCTION

Posterior stabilised (PS) implants are widely used for patients requiring primary total knee replacement. They were developed to provide controlled roll-back of the femur in flexion and redirect forces over the implant-bone interface (3, 14, 25). The post-cam design prevents uncontrolled anterior sliding of the femoral component in deep flexion without requiring excessive conformity and may restore closer to normal knee kinematics (3, 13). Satisfactory results have been widely reported for posterior stabilised implants with a higher than 95% survival rate in long-term follow-up studies (5, 9, 12, 14, 20).

However, several authors reported their concerns about the resection of the posterior cruciate ligament during total knee arthroplasty (6, 10, 21, 27) and

about the design of the posterior stabilised implants, causing increased patellar problems, decreased range of motion and osteolysis (11, 16, 18). Recent observations of the presence of surface damage and wear on the tibial post of posterior stabilised implants suggest that the cam-post interface is not an innocent articulation and may be an additional source for polyethylene wear debris (19, 22).

In this study we report the observation of impingement of the tibial post against the patellar component in deep flexion in posterior stabilised total knee arthroplasty. We determined whether post impingement is associated with 1) joint line position, 2) patellar height, 3) posterior offset of the tibial component and 4) femoral component size.

### MATERIAL AND METHODS

Impingement of the tibial post against the patellar component in deep flexion and position of the implant were evaluated in 23 consecutive patients who received a posterior stabilised total knee prosthesis (Genesis II,

---

*From St Lucas General Hospital, Bruges, Belgium and the University Hospital of Antwerp, Belgium.*

Olivier Verborgt<sup>1,2</sup>, MD, PhD, Orthopaedic Registrar.

Jan Victor, MD<sup>1</sup>, Consultant Orthopaedic Surgeon.

<sup>1</sup> AZ St. Lucas, Department of Orthopaedic Surgery, Brugge, Belgium.

<sup>2</sup> University Hospital of Antwerp, Department of Orthopaedic Surgery and Traumatology, Edegem, Belgium.

Correspondence : Olivier Verborgt, Kardinaal Mercierlei 64 b 3, 2900 Berchem, Belgium. E-mail : olivier.verborgt@pandora.be.

© 2004, Acta Orthopædica Belgica.

---

Smith and Nephew Richards, Memphis, Tennessee, USA). All components were cemented and in all cases the patella was resurfaced with a cemented polyethylene inlay component. Eighteen patients were female and 5 were male. The ages ranged from 53 to 79 years ( mean age : 71 years). The underlying diagnosis was degenerative osteoarthritis or post-traumatic arthritis in all patients.

### Peroperative Measurements

At the time of surgery, after cementing all the components and after release of the tourniquet, the flexion angle at which impingement of the post against the patella occurred was measured using a calibrated goniometer.

### Radiographic Evaluation

Anterior-posterior, lateral and full leg radiographs were made preoperatively and postoperatively at six weeks with the patient standing. On the full leg radiographs, coronal alignment was determined. On the lateral standing radiographs joint line position, patellar height and posterior offset of the tibial component were determined using the methods described by Figgie *et al* (7, 8).

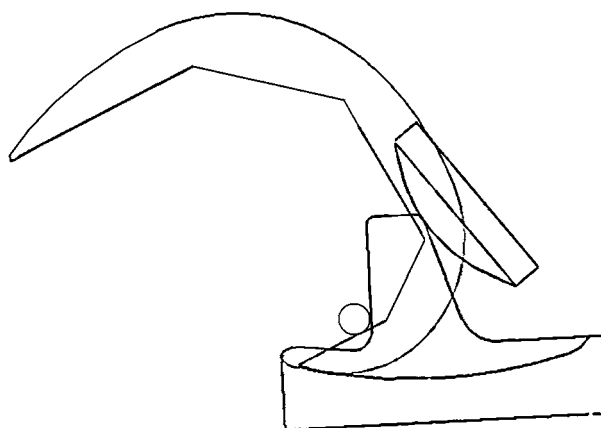
The change in joint line position pre- and postoperatively was defined as the difference between the perpendicular distance from the weight-bearing surface of the tibia plateau to the tibial tubercle on the pre-op film and the perpendicular distance from the weight-bearing surface of the prosthetic tibial component to the tibial tubercle on the post-op film. When the joint line was raised, this distance is positive. In contrast, if the joint line was lowered, this distance is negative.

The Insall-Salvati ratio (length of the patellar tendon relative to the length of the patella) was used to determine the patellar height (23).

Also, the anterior-posterior position of the tibial plateau in the sagittal plane was measured. The distance between the anatomical axis of the tibia and the center line of the tibial prosthetic component indicates the posterior offset of the tibial component.

### Statistical analysis

The Pearson product-moment correlation coefficient was used to compare angle of impingement to the four independent variables – change in joint line position, patellar height, anterior-posterior offset of the tibial



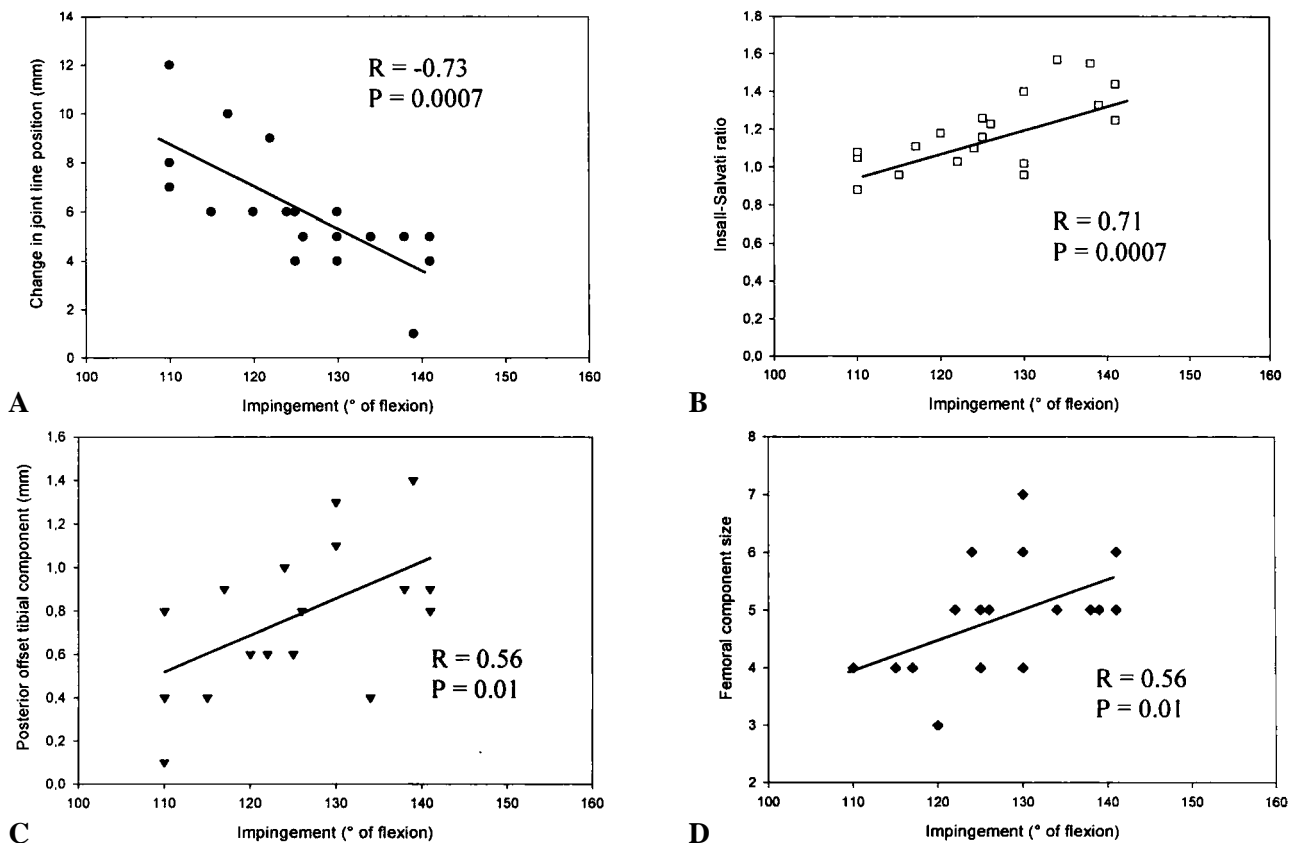
*Fig. 1.* — Schematic drawing of the mechanism of tibial post impingement against the patellar component in deep flexion in posterior stabilised total knee arthroplasty.

plateau and femoral component size. Statistical analyses were performed using the Sigmastat statistical software (version 2.03 ; SPSS, Inc). Data are reported as means  $\pm$  SD.

## RESULTS

During surgery, 19 out of 23 cases showed frank impingement of the tibial post against the patellar component at some point in deep flexion. The mean flexion angle at which impingement occurred was  $126^{\circ} \pm 10^{\circ}$ . These data confirm that impingement of the tibial post against the patellar component may occur in deep flexion in posterior stabilised total knee arthroplasty (fig 1).

The mean change in joint line position was + 6 mm in the group that showed impingement, whereas only a + 3 mm change was noted in the group that did not show impingement. When comparing change in joint line position to angle of impingement, a significant negative correlation was seen (fig 2a). This means that the more the joint line is raised, the earlier impingement of the tibial post against the patella will occur. There is a significant positive correlation between the Insall-Salvati ratio and angle of impingement, which means the lower the position of the patella, the earlier "post impingement" occurs (fig 2b). Also, we observed a significant positive correlation between



**Fig. 2.** — Comparison of angle of impingement to a) change in joint line position, b) patellar height, c) anterior-posterior offset of the tibial component and d) femoral component size.

the posterior offset of the tibial component and angle impingement, so the more anterior the tibial implant is placed, the earlier impingement may occur (fig 2c). Finally, there is a significant positive correlation between femoral component size and angle of impingement, meaning that the smaller the femoral component, the earlier impingement will occur (fig 2d).

## DISCUSSION

This study clearly shows that impingement of the tibial post against the patellar component may occur in deep flexion in posterior stabilised total knee arthroplasty. Moreover, our data strongly suggest that post impingement is associated with 1) a raised joint line, 2) patella infera, 3) too anterior placement of the tibial component and 4) smaller femoral component size.

Raising the joint line has been shown to occur quite often in posterior stabilised total knee arthroplasty (8, 14). In our study, the joint line was raised  $6 \pm 2$  mm in the group where post impingement occurred. When the posterior cruciate ligament is resected, the flexion gap will become larger (7) and the surgeon will therefore often use a thicker polyethylene insert to improve stability, hereby raising the joint line. In order to avoid post impingement in posterior stabilised total knee arthroplasty, the joint line should be kept low by performing a limited distal femoral resection, by not downsizing the femoral component when in between two sizes and by performing a generous proximal tibial resection.

Patella infera can be pre-existing or acquired after total knee arthroplasty. Both situations may lead to early post impingement. If a patella infera pre-exists, e.g. after a high tibial osteotomy, the surgeon should try to resect scar tissue behind the

patellar tendon, keep the joint line low at all times, and even sometimes consider proximal reattachment of the tibial tubercle in order to respect the patellar height. In order to avoid an acquired patella infera, correct position of the joint line, gentle surgical management of the extensor mechanism and early mobilisation postoperatively are important.

Our data suggest that using a smaller femoral component size will lead to earlier post impingement. Downsizing the femoral component when in between two sizes in posterior stabilised total knee arthroplasty is a crucial mistake, since it will lead to a raised joint line, an acquired patella infera and ultimately will result in post impingement in deep flexion.

Wear and other damage on tibial polyethylene inserts of posterior stabilised implants have been implicated in loosening and osteolysis (1, 13, 15, 24, 26). Puloski *et al* observed the presence of wear on the tibial post and suggested that the cam-post articulation in posterior stabilised implants can be an additional source of polyethylene wear debris (19). More recently, Schmalzried *et al* reported surface damage on the anterior aspect of the post in open box PS modular polyethylene tibial inserts. In their study, surface damage was associated with increased tibial slope, femoral flexion and varus malalignment (22). Although we did not look for long-term effects of post impingement in our study, one can assume that post impingement can lead to patellofemoral pain and decreased range of motion. On the long run, cyclic impingement of the tibial post against the polyethylene patellar component may cause accumulation of polyethylene wear debris and even post fracture, directly associated with negative outcomes, such as osteolysis and recurrent effusions.

This observation of impingement of the tibial post against the patella is important as the use of a post-cam mechanism is an almost universal characteristic of posterior stabilised knee designs. Posterior stabilised designs display a greater roll back of the femur on the tibia during flexion than other designs. This roll back reduces patellofemoral joint reaction forces and offers mechanical advantage for the quadriceps muscle to extend the

knee (2). Also, the knee needs 'clearance' of the posterior structures to avoid contact between the posterior tibia and the femoral bone to achieve deep flexion. This 'clearance' can only be obtained by forcing the femur into sufficient roll back and providing enough posterior condylar offset (4). As the interest in guided motion for total knee design is apparently increasing, designers need to be well aware of the possible conflict between the tibial post and the patella. It is possible that the observation of impingement is related to the specific design of the prosthesis that was used. From an implant design standpoint, this phenomenon can be avoided by chamfering the top of the tibial post or moving the post-cam mechanism further posterior. Further research is needed to evaluate the occurrence of impingement of the post with the patella in the different total knee designs that are currently used.

In conclusion, this study indicates that impingement of the tibial post against the patellar component may occur in deep flexion in posterior stabilised total knee arthroplasty. Moreover, post impingement is significantly associated with 1) a raised joint line, 2) patella infera, 3) too anterior placement of the tibial component and 4) a smaller femoral component size. These situations should therefore be avoided whenever possible. "Post impingement" may lead to patellofemoral complications, decreased range of motion and increased polyethylene wear and may on the long term jeopardise the results of posterior stabilised total knee arthroplasty.

## REFERENCES

1. Amstutz HC, Campbell P, Kossovsky N, Clarke IC. Mechanism and clinical significance of wear debris-induced osteolysis. *Clin Orthop* 1992 ; 276 : 7-18.
2. Andriacchi TP, Hurwitz DE. Gait biomechanics and total knee arthroplasty. *Am J Knee Surg* 1997 ; 10 : 255-260.
3. Banks SA, Markovich GD, Hodge WA. In vivo kinematics of cruciate-retaining and -substituting knee arthroplasties. *J Arthroplasty* 1997 ; 12 : 297-304.
4. Bellemans J, Banks S, Victor J, Vandenneucker H, Moermans A. Fluoroscopic analysis of the kinematics of deep flexion in total knee arthroplasty. Influence of the posterior condylar offset. *J Bone Joint Surg* 2002 ; 84-B : 50-53.

5. **Colizza WA, Insall JN, Scuderi GR.** The posterior stabilized total knee prosthesis. Assessment of polyethylene damage and osteolysis after a ten-year-minimum follow-up. *J Bone Joint Surg* 1995 ; 77-A : 1713-1720.
6. **Dorr LD, Ochsner JL, Gronley J, Perry J.** Functional comparison of posterior cruciate-retained versus cruciate-sacrificed total knee arthroplasty. *Clin Orthop* 1988 ; 236 : 36-43.
7. **Figgie HE, Goldberg VM, Figgie MP, Inglis AE, Kelly M, Sobel M.** The effect of alignment of the implant on fractures of the patella after condylar total knee arthroplasty. *J Bone Joint Surg* 1989 ; 71-A : 1031-1039.
8. **Figgie HE, Goldberg VM, Heiple KG, Moller HS, Gordon NH.** The influence of tibial-patellofemoral location on function of the knee in patients with the posterior stabilized condylar knee prosthesis. *J Bone Joint Surg* 1986 ; 68-A : 1035-1040.
9. **Font-Rodriguez DE, Scuderi GR, Insall J.** Survivorship of cemented total knee arthroplasty. *Clin Orthop* 1997 ; 345 : 79-86 .
10. **Freeman MA, Railton GT.** Should the posterior cruciate ligament be retained or resected in condylar nonmeniscal knee arthroplasty ? *J Arthroplasty* 1988 ; Suppl. 3 : S3-12.
11. **Grelsamer RP.** Patella baja after total knee replacement. Is it really patella baja ? *J Arthroplasty* 2002 ; 17 : 66-69.
12. **Groh GI, Parker J, Elliot J, Pearl AJ.** Results of total knee arthroplasty using the posterior stabilized condylar prosthesis : a report of 137 consecutive cases. *Clin Orthop* 1991 ; 269 : 58-62.
13. **Harris WH.** The problem is osteolysis. *Clin Orthop* 1995 ; 311 : 46-53.
14. **Insall JN, Lachiewicz PF, Burstein AH.** The posterior stabilized condylar prosthesis : a modification of the total condylar design : two to four-year clinical experience. *J Bone Joint Surg* 1982 ; 64-A : 1317-1323.
15. **Kuster MS, Stachowiak GW.** Factors affecting polyethylene wear in total knee arthroplasty. *Orthopedics* 2002 ; 25 : S235-242.
16. **Li E, Ritter MA, Moilanen T, Freeman MA.** Total knee arthroplasty. *J Arthroplasty* 1995 ; 10 : 560-570.
17. **Mihalko WM, Krackow KA.** Posterior cruciate ligament effects on the flexion space in total knee arthroplasty. *Clin Orthop* 1999 ; 360 : 243-250.
18. **O'Rourke MR, Callaghan JJ Goetz DD, Sullivan PM, Johnston RC.** Osteolysis associated with a cemented modular posterior-cruciate-substituting total knee design : five to eight-year follow-up. *J Bone Joint Surg* 2002 ; 84-A : 1362-1371.
19. **Puloski SKT, McCalden RW, MacDonald SJ, Rorabeck CH, Bourne RB.** Tibial post wear in posterior stabilized total knee arthroplasty. *J Bone Joint Surg* 2001 ; 83-A : 390-398.
20. **Ritter MA, Campbell E, Faris PM, Keating EM.** Long-term survivor analysis of the posterior cruciate condylar total knee arthroplasty. A 10-year evaluation. *J Arthroplasty* 1989 ; 4 : 293-296.
21. **Rorabeck CCR, Clarke CR, MacDonald S, MacDonald D, Swafford J, Cleland D.** Posterior-stabilized and cruciate-retaining total knee replacement : a randomized study. *Clin Orthop* 2001 ; 392 : 208-212.
22. **Schmalzried TP, Silva M, Kabbash CA, Tiberi JV, Park SH, Reilly T.** Surface damage on open box PS modular polyethylene tibial inserts. Presented at the *Annual Meeting of the Knee Society*, New Orleans, LO, February 2003.
23. **Scuderi GR, Windsor RE, Insall JN.** Observations on patellar height after proximal tibial osteotomy. *J Bone Joint Surg* 1989 ; 71-A : 245-248.
24. **Sharkey PF, Hozack WJ, Rothman RH, Shastri S, Jacoby SM.** Why are total knee arthroplasties failing today ? *Clin Orthop* 2002 ; 404 : 7-13.
25. **Uvehammer J, Karrholm J, Brandsson S.** In vivo kinematics of total knee arthroplasty. *J Bone Joint Surg* 2000 ; 82-B : 499-505.
26. **Wasielowski RC, Galante JO, Leighty RM, Natarajan RN, Rosenberg AG.** Wear patterns on retrieved polyethylene tibial inserts and their relationship to technical considerations during total knee arthroplasty. *Clin Orthop* 1994 ; 299 : 31-43.
27. **Worland RL, Jessup DE, Johnson J.** Posterior cruciate recession in total knee arthroplasty. *J Arthroplasty* 1997 ; 12 : 70-73.