



Reconstruction of the medial patellofemoral ligament for patellar instability using an autologous gracilis tendon graft

Chul Ki GOORENS, Hisco ROBIJN, Bart HENDRICKX, Hendrik DELPORT, Kris DE MULDER, Johan HENS

From the Algemeen Ziekenhuis, St-Niklaas, Belgium

Patellofemoral dislocations are common. In cases with recurrence or residual instability, surgical intervention is usually considered. Numerous treatment protocols have been used in the past to treat patellofemoral instability secondary to patella dislocation. Reconstruction of the medial patellofemoral ligament is one of the possible options, since it was acknowledged to have a major medial stabilising role on the patella.

We present a technique for reconstruction of the medial patellofemoral ligament using an autologous gracilis tendon graft.

Keywords : medial patellofemoral ligament reconstruction ; patellofemoral instability.

INTRODUCTION

Patellofemoral dislocations are common. Numerous approaches have been used in the past to treat residual patellofemoral instability. Most surgeons advocate an initial conservative attitude towards acute first-time patellar dislocations, whereas in cases of recurrence or residual instability, surgical intervention is usually considered.

Dislocation or subluxation is generally directed to the lateral side. The strongest restrictors to lateral movement are the medial ligamentous structures : the capsule and medial retinacular ligament. In this medial retinacular ligament a dense bundle of transversely orientated fibres is found, the so-called medial patellofemoral ligament (MPFL).

The MPFL runs obliquely from the superior two thirds of the medial border of the patella to the femoral attachment, just distal to the adductor tubercle and proximal to the posterior part of the insertion of the superficial medial collateral ligament (MCL). Some fibres extend into the posterior capsule of the knee (10,11). The medial patellofemoral ligament is thought to be responsible for more than 50% of the medial restraining force to the patella. The patellomeniscal ligament only contributes 22%. In chronic dislocations or subluxations, an insufficiency of the MPFL exists and in the acute setting a tear of the MPFL can be found in 94% of patients, especially at the femoral insertion. Isolated sectioning of the MPFL leads to increased lateral shifting of the patella between 20° to 90° of knee flexion (2,3,7,12-14).

■ Hendrik Delpport, MD, Orthopaedic Surgeon.

■ Kris De Mulder, MD, Orthopaedic Surgeon.

■ Johan Hens, MD, Orthopaedic Surgeon.

Department of Orthopaedic Surgery, Algemeen Ziekenhuis, St-Niklaas, Belgium.

■ Chul Ki Goorens, MD, Orthopaedic Surgeon.

■ Bart Hendrickx, MD, Orthopaedic Surgeon.

■ Hisco Robijn, MD, Orthopaedic Surgeon.

Department of Orthopaedic Surgery, Regionaal Ziekenhuis Tienen, Tienen, Belgium.

Correspondence : Chul Ki Goorens, Dorpsstraat 204/3, 3078 Meerbeek, Belgium. E-mail : cgoorens@msn.com

© 2010, Acta Orthopædica Belgica.

MPFL reconstruction restores almost normal patellar tracking between 20° and 120° of knee flexion. The aim is to restore the isometric part of the MPFL, which corresponds to the part between the inferior patellar attachment and the superior part of the femoral attachment (13,17).

Several materials have been used to reconstruct the MPFL : artificial ligament, autologous patellar tendon, hamstring tendon (semitendinosus, gracilis), adductor tendon, iliotibial band, various types of allografts, and strips of the medial retinaculum. Donor site morbidity and biomechanical compatibility must be considered, when an autograft is used (2,4,6,8,11-13,16).

We describe here our operative technique using an autologous gracilis tendon graft.

Surgical technique

The patient is operated under general anaesthesia, in supine position, with a thigh tourniquet, with both knees in 30° of flexion, lowering the distal part of the operating table and using a pillow under the affected knee. A support under the ipsilateral buttock corrects for spontaneous external rotation in the hip joint. The ipsilateral gracilis tendon is harvested with a tendon stripper at its distal insertion using a small oblique anteromedial approach.

Next, the femoral insertion site is prepared using a vertical medial skin incision halfway between the medial epicondyle and the medial patellar edge. Alternatively, a small vertical incision over the medial femoral epicondyle can be made and a small vertical medial parapatellar incision over the patellar insertion site. Dissection of the superior part of the epicondyle just posterior to the superficial part of the MCL and inferior to the adductor tubercle is performed. The patellar insertion site is prepared by dissecting the proximal half of the medial patellar ridge, which can be found underneath the medial patellar retinaculum and the insertion of the vastus medialis obliquus (VMO) ; the retinaculum is carefully opened in a longitudinal fashion and liberated from the medial patellar edge, just inferior to the distal edge of the VMO, avoiding opening the capsule and entering the knee joint. By retracting the VMO, the superomedial corner of the medial patellar border can be visualised.

Two connecting bony tunnels are created in the patella using a 3.5 mm drill. The first tunnel starts at the superior medial corner and is directed laterally and downwards to halfway the upper medial quadrant of the patella. The second starts halfway on the medial ridge of the patella to meet the distal end of the first tunnel, hereby creating a passage in the medial upper part of the patella.

Using a suture passed through the patellar tunnel and fixed to a guide wire, the most isometric point of the femoral insertion is determined ; it lies superiorly and posteriorly to the MCL insertion. The guide wire is drilled laterally to emerge at the lateral epicondyle. A deep tunnel approximately 3.5 cm in length is created using a 6 or 7 mm diameter reamer over the guide wire. Subsequently, the double bundled graft is passed through the patellar tunnel and the two bundles are tunnelled underneath the medial retinaculum and the VMO. Using Krackow N° 0 non-absorbable braided traction sutures at both ends of the graft, the graft strands are pulled firmly into the femoral drill hole, the guide wire is extracted through the lateral epicondyle and an absorbable soft tissue interference screw measuring 7 × 30 mm (Biocryl, Mitek®) locks the graft into the femoral tunnel while the knee is held in 30° of flexion (fig 1-5).

Retinacular structures, VMO and fascia are closed anatomically with absorbable sutures. A small suction drain is left in place under the deep fascia for 24 hours.

Postoperative rehabilitation consists of two weeks of cast immobilisation in slight flexion. Partial weight-bearing using two crutches is allowed. After this period a hinge brace is applied for 6 weeks, and the range of motion is gradually increased (range of motion for the first 2 weeks 0-30°, after 2 weeks 0-60°, after 4 weeks 0-90°) until full range of motion is regained in 6 weeks. Resuming or starting sports activities is allowed after a minimum period of 3 months.

DISCUSSION

Various MPFL reconstruction techniques have been described, with generally satisfactory outcome. Steensen *et al* used a quadriceps tendon

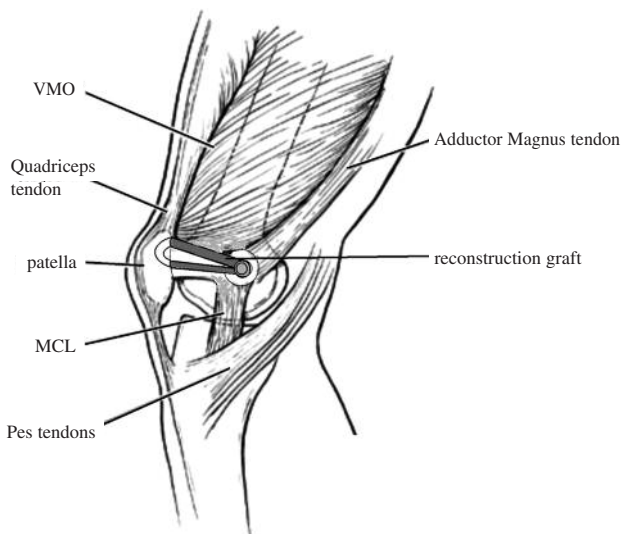


Fig. 1. — Sagittal view from a medial perspective illustrating the normal course of the medial patellofemoral ligament (MPFL) and the reconstruction graft. Vastus medialis obliquus (VMO), Medial collateral ligament (MCL).

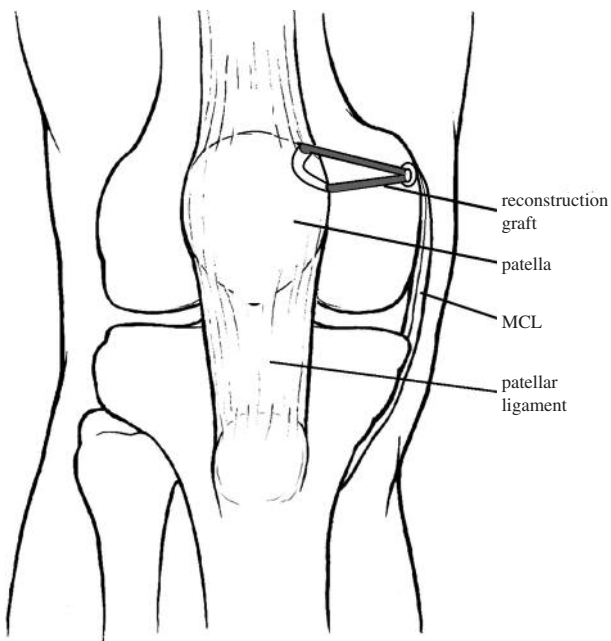


Fig. 2. — Anterior view from an illustration of the course of the MPFL.

autograft, leaving the attachment to the patella intact and turning this graft 90° medially (16). Although they reported ‘promising results’ with this technique and no recurrence of dislocation, we

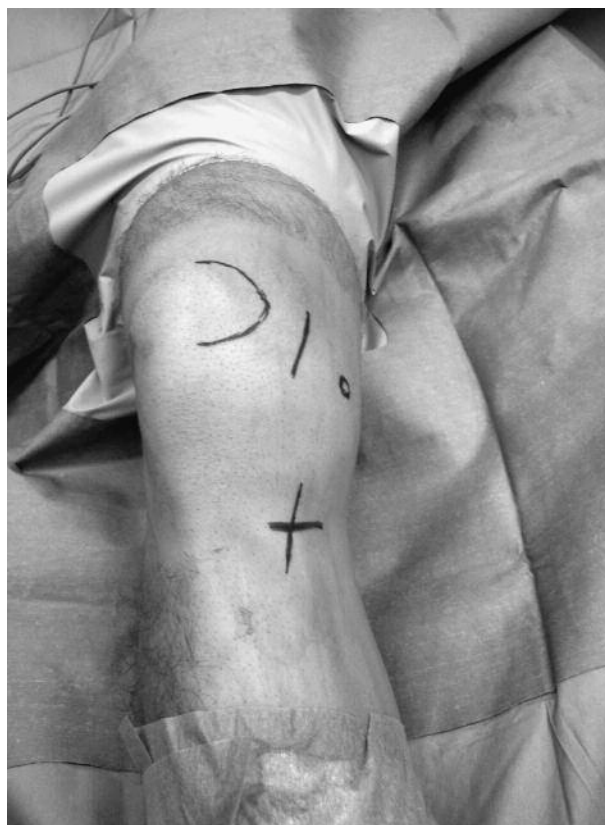

Fig. 3. — Anteromedial view of the skin incisions: one halfway between patella and medial femoral epicondyle and one small obliquely running incision at the gracilis distal insertion site.

believe that harvesting part of the quadriceps-tendon may give important co-morbidity like important scarring, loss of quadriceps strength and inferior isometric positioning of the graft.

Fernandez *et al* reconstructed the MPFL in 27 knees with a semitendinosus autograft in a transpatellar tunnel technique with excellent results (9). Camanho *et al* described the use of the medial third of the patellar ligament in 25 patients with ‘encouraging’ results with a follow-up time of less than 2 years (2). This last technique is almost the mirror approach of the technique described by Steensen *et al* (17).

Nomura *et al* described the use of a mesh-type artificial ligament and medial retinacular slip coverage in 27 knees, rating 96% of the reconstructed knees as excellent or good after 5.9 years of follow-up. They also described a hybrid method in

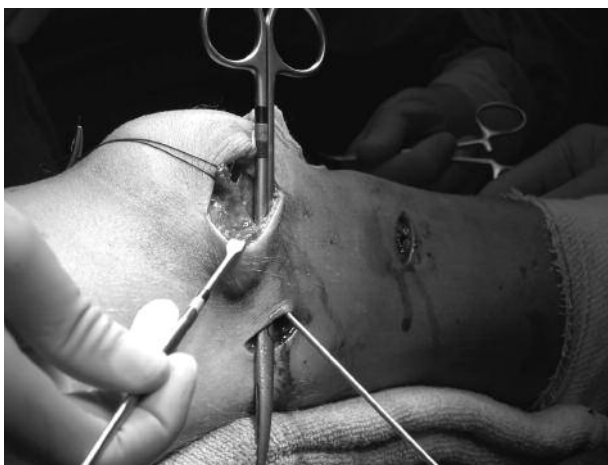

Fig. 4. — Sagittal view from a medial perspective showing the alternative approach with three incisions. The tunnel underneath the medial retinaculum and vastus medialis obliquus is illustrated by the dissection scissors.

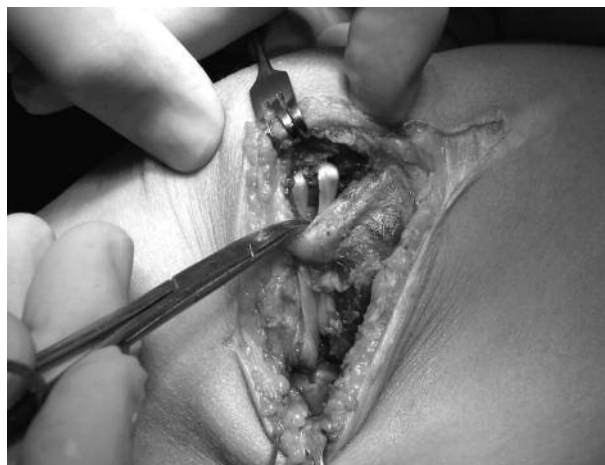

Fig. 5. — Sagittal view from a medial perspective showing the course of the reconstruction graft.

reconstructing the MPFL in 2006 for 12 patients, in which the semitendinosus tendon is looped through an Ethibond loop, which is attached to the patella in a comparable manner as in the technique we used (12,13).

Mikashima *et al* fixed a double strand of a semitendinosus graft to the femur with an endobutton and passed one of the two strands through a transverse bony tunnel in the patella. The ends of the strands were then sutured to one another. The alternative technique they used was by suturing the two strands directly to the periosteal and fibrous tissue overlying the patella (10).

Christiansen *et al* described a similar technique using a gracilis tendon routed through two parallel bony tunnels (5).

We pass the graft through a curved bony tunnel with a smooth angle in the medial upper part of the patella. Since the gracilis tendon is less bulky than the semitendinosus, the graft can easily be passed through patellar drill holes with a small diameter. This reduces the chance of patellar fracture. The use of the gracilis tendon minimizes the effect on hamstring function.

By creating a bony tunnel only at the medial side, the chance of horizontal patellar fracture is also greatly reduced.

Furthermore, we believe that the use of a bony tunnel provides a better graft fixation to the patella than a direct suture to the fibrous tissue overlying the patella.

The femoral point of origin needs to be carefully prepared to obtain an isometric reconstructed ligament. There is still discussion about this femoral attachment point: Smirk *et al* showed that in a series of 25 knee specimens, 84% of the attachments were to the posterior border of the medial epicondyle (isolated or as part of a wider area) and in 16% the attachments were to the anterior part of the medial epicondyle. Most studies confirm that the origin of the MPFL on the femoral side is posterosuperior to the medial epicondyle and just distal to the adductor tubercle, the so called ‘Nomura’s point’ (1-3,7,9,12,13,15).

Additionally, attention needs to be given to the fixation of the graft since multiple fixation methods exist, such as complete or incomplete transpatellar tunnelling and use of a patellar interference screw, partial tunnelling and reattachment onto the graft itself, periosteal plication and suturing the graft onto the patella or use of suture-anchors to fixate the graft at the patellar side. Complications such as loss of fixation or patellar fracture (with complete transpatellar tunnels) have been described (10).

We noted no problems of fixation or donor site morbidity. We have had no recurrent dislocations to report.

We believe that reconstruction of the MPFL using a gracilis autograft is a valuable technique for the treatment of patellar instability, based on soft tissue insufficiency. The surgical technique is relatively simple and reproducible.

REFERENCES

1. **Amis AA, Firer P, Mountney J, Senavongse W, Thomas NP.** Anatomy and biomechanics of the medial patellofemoral ligament. *Knee* 2003 ; 10 : 215-220.
2. **Camanho GL, Bitar AC, Hernandez AJ, Olivi R.** Medial patellofemoral ligament reconstruction : a novel technique using the patellar ligament. *Arthroscopy* 2007 ; 23 : 108.e1-108.e4.
3. **Conlan T, Gaeth WP Jr, Lemons JE.** Evaluation of the medial soft-tissue restraints of the extensor mechanism of the knee. *J Bone Joint Surg* 1993 ; 75-A : 682-693.
4. **Cossey AJ, Paterson R.** A new technique for reconstructing the medial patellofemoral ligament. *Knee* 2005 ; 12 : 93-98.
5. **Christiansen SE, Jacobsen BW, Lund B, Lind M.** Reconstruction of the medial patellofemoral ligament with transverse patellar drill holes. *Arthroscopy* 2008 ; 24 : 82-87.
6. **Deie M, Ochi M, Sumen Y et al.** Reconstruction of the medial patellofemoral ligament for the treatment of habitual or recurrent dislocation of the patella in children. *J Bone Joint Surg* 2003 ; 85-B : 887-890.
7. **Desio SM, Burks RT, Bachus KN.** Soft tissue restraints to lateral patellar translation in the human knee. *Am J Sports Med* 1998 ; 26 : 59-64.
8. **Drez Jr D, Edwards TB, Williams CS.** Results of medial patellofemoral ligament reconstruction in the treatment of patellar dislocation. *Arthroscopy* 2001 ; 17 : 298-306.
9. **Fernandez E, Sala D, Castejon M.** Reconstruction of the medial patellofemoral ligament for patellar instability using a semitendinosus autograft. *Acta Orthop Belg* 2005 ; 71 : 303-308.
10. **Mikashima Y, Kimura M, Kobayashi Y, Miyawaki M, Tomatsu T.** Clinical results of isolated reconstruction of the medial patellofemoral ligament for recurrent dislocation and subluxation of the patella. *Acta Orthop Belg* 2006 ; 72 : 65-71.
11. **Mikashima Y, Kimura M, Kobayashi Y, Miyawaki M, Tomatsu T.** Medial patellofemoral ligament reconstruction for recurrent patellar instability. *Acta Orthop Belg* 2004 ; 70 : 545-550.
12. **Nomura E, Inoue M.** Hybrid medial patellofemoral ligament reconstruction using the semitendinosus tendon for recurrent patellar dislocation : minimum 3 years' follow-up'. *Arthroscopy* 2006 ; 7 : 787-793.
13. **Nomura E, Inoue M.** Surgical technique and rationale for medial patellofemoral ligament reconstruction for recurrent patellar dislocation. *Arthroscopy* 2003 ; 19 ; E47 : 1-9.
14. **Sanders TG, Morrison BG, Singleton BA, Miller MD, Cornum KG.** Medial patellofemoral ligament injury following acute transient dislocation of the patella : MR findings with surgical correlation in 14 patients. *J Comp Ass Tomo* 2001 ; 25 : 957-962.
15. **Smirk C, Morris H.** The anatomy and reconstruction of the medial patellofemoral ligament. *Knee* 2003 ; 10 : 221-227.
16. **Steenen RN, Dopirak RM, Maurus PB.** A simple technique for reconstruction of the medial patellofemoral ligament using a quadriceps tendon graft. *Arthroscopy* 2005 ; 21 : 365-370.
17. **Steenen RN, Dopirak RM, McDonald III WG.** The anatomy and isometry of the medial patellofemoral ligament. Implications for reconstruction. *Am J Sports Med* 2004 ; 32 : 1509-1513.