



## Persistent knee complaints after retrograde unreamed nailing of femoral shaft fractures

Mostafa EL MOUMNI, Pim SCHRAVEN, Henk Jan TEN DUIS, Klaus WENDT

*From the University Medical Center Groningen, The Netherlands*

Retrograde nailing is an attractive method for stabilisation of femoral shaft fractures in cases of polytrauma, ipsilateral pelvic, acetabular, tibial and femoral neck fractures, bilateral femoral fractures, obese and pregnant patients. However, retrograde nailing may result in complaints about the knee. The purpose of this study was to evaluate the incidence and risk factors of lasting knee pain, and its relation to knee function deficits.

We conducted a retrospective study of 75 patients in whom 82 femoral shaft fractures were treated with retrograde intramedullary nailing.

Complaints of pain about the knee during follow-up were present in 17 patients (23%). The mean age of patients with knee pain was significantly lower (26 years) than the age of those without knee pain (41 years) ( $p = 0.0002$ ). Both groups, with and without pain about the knee, were not significantly different according to gender, injury severity score, AO type of fracture, associated ipsilateral injuries, open fractures, or type of nail used. In addition, the range of motion did not differ. Although 49% of all patients had also presented ipsilateral pelvis, acetabulum or lower leg fractures, the majority (89%) had a knee flexion  $\geq 120^\circ$ .

Complaints of knee pain after retrograde intramedullary nailing of femoral fractures were found to be rather common. Younger age appeared to be a risk factor for knee pain. Nevertheless, the majority of patients had excellent knee function.

**Keywords :** femur ; femoral fractures ; intramedullary nailing ; retrograde nailing ; knee complaints ; knee pain.

## INTRODUCTION

Intramedullary (IM) nailing is considered the treatment of choice for femoral shaft fractures. Interlocking nails can be inserted via an antegrade or retrograde approach. Antegrade femoral nailing is a widespread technique and has demonstrated high rates of healing and low rates of infection and malunion (1,21,22,42,43,44). In a retrospective study, we showed a low incidence of non-union (1.9%) and infection (1.9%) after unreamed antegrade IM nailing of femoral shaft fractures (12). Disadvantages of antegrade nailing of the femur include the risk of injury to the hip abductors or their nerve supply (7), restricted usability in combined ipsilateral femoral neck and shaft fractures, difficulties in locating the exact entry point especially in obese patients (27,40), the risk of heterotopic ossification

- 
- Mostafa El Moumni, MD, Trauma surgeon.
  - Pim J.P. Schraven, MD, Medical Student.
  - Henk Jan ten Duis, MD, PhD, Trauma surgeon, Professor of trauma surgery.
  - Klaus Wilhelm Wendt, MD, PhD, Trauma surgeon.  
*Department of Traumatology, University Medical Center Groningen, The Netherlands.*
- Correspondence : M. el Moumni, Kamer W4.272, BA13, Hanzeplein 1, 9700 RB Groningen, The Netherlands.  
E-mail : m.el.moumni@chir.umcg.nl  
© 2010, Acta Orthopædica Belgica.
-

around the hip (6,36), and the possible occurrence of implant related pain (33).

In 1950, Lezius (25) introduced treatment of inter- and subtrochanteric femoral fractures with a distally inserted curved nail through the medial femoral condyle passing across the fracture into the femoral neck. In the seventies, Ender and Simon-Weidner (13), Küntscher (23), and Collado *et al* (9) also introduced the nails through the medial femoral condyle into the femoral head to treat trochanteric fractures. Retrograde nailing of femoral shaft fractures was first reported by Swiontkowski *et al* also using a distal medial metaphyseal approach and a cloverleaf hollow nail (38). In 1988, Green advocated retrograde nailing of femoral fractures systematically using an intercondylar notch approach (15). Since then, the indication for retrograde nailing of femoral fractures has expanded. Retrograde nailing has been recommended in cases of polytrauma, ipsilateral pelvic, acetabular, tibial and femoral neck fractures, bilateral femoral fractures, obese and pregnant patients (8,16,17,28,33,36). Retrograde femoral nailing is done in the supine position, does not require a fracture table, and therefore does not preclude additional surgical procedures (29). A shorter operating time has been reported (28), although prospective randomised studies do not confirm this (33,39).

Introduction of the nail through the intercondylar notch of the femur may result in knee problems, including infection, damage to the articular cartilage and persistent knee pain (33,36).

The increasing popularity of retrograde nailing has raised concerns about knee complaints. We conducted this retrospective study primarily to evaluate the incidence and possible risk factors of knee pain, as well as the relation to knee function deficits.

## PATIENTS AND METHODS

Between November 1997 and June 2007, 95 patients with 103 femoral fractures were treated with retrograde IM nailing at the University Medical Center Groningen, the Netherlands. Pathological fractures ( $n = 6$ ) were excluded. We also excluded from the study patients with insufficient follow-up data, including 7 patients transferred to other hospitals, 4 who died in the early postoperative period ( $< 1$  week) and 3 who refused follow-up

visits. All patients were skeletally mature. We retrospectively analysed the remaining 75 patients with 82 femoral shaft fractures. They were predominantly young male individuals involved in traffic accidents. There were 55 male and 20 female patients with an average age of 38 years (range : 15-84). Fractures were caused by traffic accidents in 62, by a fall in 6, hit by a heavy object in 3 and by other causes in 4 patients. The mean injury severity score (ISS) was 18 (range : 9-66). Thirty-two patients (43%) had an ISS  $\geq 16$ .

According to the AO classification, we identified 28 type A, 36 type B, and 18 type C shaft fractures. Thirteen fractures were open : Gustilo grade I in 6, grade II in 4, and grade III in 3.

Indications for retrograde nailing included polytrauma (thoracic injury, abdominal injury, and spinal injury) ; ipsilateral acetabulum, pelvis, tibia or femoral neck fractures ; bilateral femoral fractures, and extreme adiposity.

Through a longitudinal incision medial to the patellar tendon, the nail was introduced in the intercondylar groove anterior and lateral to the posterior cruciate insertion. A distal femoral nail (DFN, Synthes®) was used to stabilise 44 femoral shaft fractures, and an ACE nail (Depuy®) was used in the remaining 38 cases. All nails were inserted without reaming. Primary dynamic locking was performed in 22 femurs ; full weight bearing was permitted in these after wound healing. The nails were statically locked in 60 femurs and gradual full weight bearing was allowed after 6 weeks in these cases. Dynamisation was subsequently performed in 22 of these to promote union.

For each patient, we specifically recorded knee pain during follow-up, and the range of motion (ROM) of the knee. The patients were followed at regular intervals with clinical and radiological examination at 6 weeks, 3, 6, 9, 12 and 18 months postoperatively. Minimal follow-up was 1 year in all cases. Knee function was recorded at the latest follow-up visit using the neutral-0-method.

Chi-square or Fisher's exact test were used to evaluate differences in sex, type of fracture (AO classification), the presence of ipsilateral lower limb injury, the degree of soft tissue injury (i.e. open or closed), type of nail used and range of motion ( $\geq 120^\circ$  or  $< 120^\circ$ ) between patients with or without knee pain. Student's *t*-tests were used to evaluate differences in age and ISS. Multiple regression analysis was performed to test the relationship among the study variables and the dependent variable knee pain. In patients with bilateral femur fractures, the injury to the left leg was considered the primary injury. A *p*-value of  $< 0.05$  was considered significant. Data were analyzed using SPSS® for Windows version 16.0.

Table I. — Characteristics of the study group

Mean age	38 years (SD : 19 )
Sex	
male	n = 55
female	n = 20
Mechanism of injury	
traffic accident	n = 62
fall from height	n = 6
crush injury	n = 4
heavy object	n = 3
Mean Injury Severity Score (ISS)	18 (range 9-66)
Side of fracture	
left	n = 34
right	n = 34
bilateral	n = 7
Type of fracture	
Closed	n = 69
Open	n = 13
Gustilo Type I	n = 6
Gustilo Type II	n = 4
Gustilo Type III	n = 3
AO Classification	
A1	n = 4
A2	n = 9
A3	n = 15
B1	n = 5
B2	n = 24
B3	n = 7
C1	n = 12
C2	n = 3
C3	n = 3

## RESULTS

Demographics of the study population are presented in table I.

Complaints of pain in the knee during follow-up were identified in 17 patients (23%). Twelve patients complained of pain at the medial side of the knee, and 4 patients located the pain at the lateral side. One patient complained of persistently 'feeling' the nail while walking, although the fracture was healed. All 17 patients had regained knee flexion of 120° or more. Of these 17 patients, only one had a concomitant injury around the knee, i.e. a supracondylar femoral fracture. Interestingly, 7 patients with an associated patella fracture and 7 patients with a tibial plateau fracture (table III)

Table II. — Variables used in univariate and multivariate analysis

Variables	Pain (n = 17)	No Pain (n = 58)	p-value
Mean age	26	41	0.0002
Sex (M/F)	13/4	42/16	ns
ISS	18	18	ns
AO-type (A/B/C)	7/4/6	21/32/12	ns
Ipsilateral injury	41%	50%	ns
Open fracture	17%	10%	ns
Nail type (ACE/DFN)	11/6	27/38	ns

ns : non significant.

Table III. — Associated ipsilateral pelvis, acetabulum or lower leg fractures

Fracture	Number
Pelvis	10
Acetabulum	2
Patella	7
Tibial plateau	7
Tibia shaft	21
Isolated fibula	2
Ankle	6
Talus	1
Calcaneus	2
Navicular	1
Cuneiform	1
Metatarsal	3
Lisfranc fracture-dislocation	1
Total	64

did not complain of knee pain. There were no cases of infection in this series. Univariate analysis showed no significant difference in sex, ISS, AO type of fracture, ipsilateral injuries, open fractures, or type of nail between patients with or without knee pain (see table II). However, the mean age of patients with knee pain was significantly lower (26 years, 95% confidence interval, 20-32) than the age of those without knee pain (41 years, 95% confidence interval, 36-46 ;  $p = 0.0002$ ). Logistic regression analysis showed that the only independent predictor of knee pain was age.

In one patient the complaints of pain diminished spontaneously. In 4 patients with knee pain the nail was removed, and in 12 patients only the distal screws. The knee pain improved (n = 5) or

disappeared ( $n = 12$ ) in all these patients. The nail and/or screws were removed at an average of 20 months (range 3-52 months).

Knee range of motion was assessed in all patients. Concomitant ipsilateral pelvis, acetabulum or lower leg fractures were present in 40 patients (49%) (table III). Knee flexion  $\geq 120^\circ$  was seen in 73 knees (89%) and flexion  $< 120^\circ$  in 9. There was no significant difference in sex, age, ISS, AO type of fracture, ipsilateral injuries, open fractures, or type of nail between patients with flexion  $\geq 120^\circ$  and patients with flexion  $< 120^\circ$ . Furthermore, there was no difference in range of motion between those who experienced pain and those who did not. Six of the 9 patients with flexion  $< 120^\circ$  had an ipsilateral fracture of the limb or a neurovascular injury. An extension deficit  $> 10^\circ$  was seen in 4 patients.

## DISCUSSION

Retrograde nailing is an attractive alternative to antegrade iIM nailing of femoral shaft fractures. It has been recommended in cases of polytrauma, in patients with ipsilateral pelvic, acetabular, tibial and femoral neck fractures, in bilateral femoral fractures, in obese and pregnant patients (8,16,17,28,33,36). However, retrograde nailing may result in complaints about the knee: pain, knee function deficit and stiffness of the knee joint.

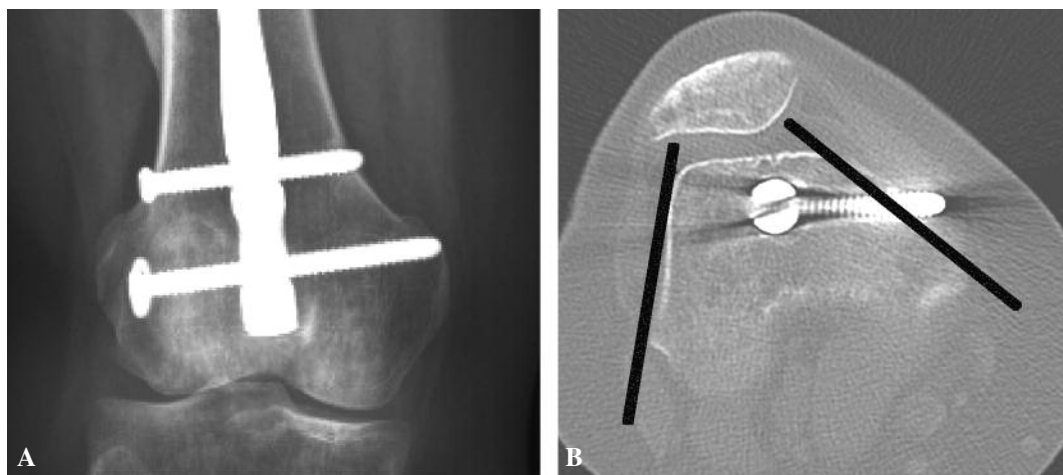
The incidence of knee pain reported in several retrospective studies (17,24,28,35) ranges from 30 to 68%. A review of the literature showed a mean incidence of knee pain of 25.6% (1.1%-55%) at the end of follow-up (20). Little is known about knee pain after retrograde nailing of femoral fractures on the long term. Only a few studies have a follow-up time of more than one year. Sanders *et al* (37), using a medial extra-articular entry point, have reported that 54% of the patients complained of pain with a mean time of follow-up of 16 months. Using an intercondylar approach the long-term incidence of knee pain varies between 32% and 68% (17,19,24,35), with a maximal mean follow-up time of 25 months. In this study, persistent knee pain was present in 23% of the patients. All these patients had regained  $\geq 120^\circ$  knee flexion. We found that age is the only independent predictor of knee pain after retrograde

femoral nailing. Possible explanations include higher physical demands in younger adults or higher pain tolerance in older patients.

Studies comparing antegrade versus retrograde nailing of femoral shaft fractures give conflicting results with respect to the occurrence of knee pain. In a prospective (pseudo)randomised study, Tornetta & Tiburzi (39) reported that in the retrograde group knee pain was common (81%) in the immediate postoperative period. However, these complaints of pain subsided by the time of union in all but 4 retrograde (13%) and 5 antegrade patients (13%), usually with return of quadriceps strength. Yu *et al* (45) found no difference in knee pain between the antegrade and retrograde nailing group. This is consistent with the prospective, (pseudo)randomized study of Ostrum *et al* (33). However, Ostrum *et al* (33) found that hip and thigh pain predominated significantly in the antegrade group. Ricci *et al* (36) retrospectively studied 293 femoral shaft fractures, of which 140 were stabilised with retrograde nailing at an average follow up of 23 months. They found that significantly more patients reported knee pain in the retrograde group (36% vs 9%). However, significantly more patients in the antegrade group reported hip pain (10% vs 4%).

The main cause of pain in this study seemed to be hardware related. In all patients, symptoms improved after removing the distal locking screws or the entire nail. A possible explanation can be found in the observation that the distal femur has a cross sectional trapezoidal form. The medial and lateral walls tend to diverge posteriorly. Using AP fluoroscopy peroperatively, the distal locking screws may be too long as shown in figure 1. The length of the locking screws must carefully be checked to avoid protrusion and irritation of the soft tissues.

Several studies (24,32,35,39) have reported distal locking screws as a possible cause of knee pain. Various other sources of knee pain have been described. Arthroscopic and MRI studies have shown a high incidence of knee pathology associated with femoral fractures (3,10,11). Most affected structures are the medial collateral ligament, the anterior cruciate ligament and the lateral meniscus.



**Fig. 1A-B.** — A 44 year-old female with a type A3 femoral shaft fracture.

(A) Postoperative anteroposterior view of the locking screws. (B) An axial section of the CT scan shows that the lateral and medial wall of the distal femur are sloped. The distal locking screw is 1 cm too long.

In MRI studies based upon knee complaints, bone bruises are increasingly being recognised as related injuries (11). The clinical significance of these lesions has yet to be determined. However, they may be a source of persistent clinical symptoms. Boks *et al* (4) have described the natural course of bone bruises using MRI follow-up in patients with posttraumatic knee complaints who were seeking help from their general practitioner. The median healing time of bone bruises was 42.1 weeks. This was prolonged in the presence of osteoarthritis and a greater number of initial bruises.

Other sources of knee pain include quadriceps dysfunction (39), intraosseous hypertension (2) and patellar tendon injury due to a transtendinous approach (20). Knee pain may also be caused by degenerative changes secondary to an alteration in the mechanical axis of the femur after union (31, 41). A persistent concern has been that retrograde nailing could damage the patellofemoral articulation. However, several authors (5,14,26,28) used arthroscopy to remove the nail after malunion of the fracture and found no patellofemoral articular lesions other than fibrous tissue. These findings are consistent with a report by Morgan *et al* (30). They demonstrated no increased patellofemoral contact pressures when retrograde nails were properly counter-

sunk. It seems doubtful that knee pain after retrograde nailing is caused by any adverse effect on the patellofemoral articulation when the nail is properly placed. Because all complaints improved after removal of the hardware, these described causes are of minor importance in our series.

The majority of our patients (89%) had a range of flexion of the knee of at least 120°. This is comparable to previous reports (17,29,34,35). With the numbers studied, we found no difference in sex, age, ISS, AO type of fracture, ipsilateral injuries, open fractures, or type of nail between patients with flexion  $\geq 120^\circ$  and patients with flexion  $< 120^\circ$ . Comparative studies (18,33,39,45) reported that there is no difference in the range of motion (ROM) of the knee between antegrade and retrograde nailing of femoral shaft fractures. Furthermore, Herscovici (18) and Tornetta & Tiburzi (39) did not find a difference in ROM of the hip either. Papadokostakis *et al* (34) in a meta-analysis reported a mean knee ROM of 127.6° after retrograde nailing of femoral fractures. Patients with type A compared to type C fractures regained a slightly but significantly better ROM. In this study, we found no difference in ROM between these patients.

Our study has the limitations of a retrospective analysis. The study could be underpowered. We did

not use a visual analogue scale or a functional outcome score to assess the pain complaints. It is a single center study and conclusions cannot be generalised. The included subjects are mainly polytrauma patients. In addition, residual confounding factors cannot be ruled out. Also the follow-up is short and the long term effect on function of the knee and possible arthritic changes induced by intra-articular damage remain unknown.

In conclusion, knee complaints were experienced commonly in our series of retrograde nailing of femoral shaft fractures. However, symptoms improved in all patients after removal of the distal locking screws or of the nail. Furthermore, the majority of the patients had an acceptable knee range of motion.

## REFERENCES

1. **Abbas D, Faisal M, Butt MS.** Unreamed femoral nailing. *Injury* 2000 ; 31 : 711-717.
2. **Arnoldi CC, Lemperg K, Linderholm H.** Intraosseous hypertension and pain in the knee. *J Bone Joint Surg* 1975 ; 57-B : 360-363.
3. **Blacksin MF, Zurlo JV, Levy AS.** Internal derangement of the knee after ipsilateral femoral shaft fracture : MR imaging findings. *Skeletal Radiol* 1998 ; 27 : 434-439.
4. **Boks SS, Vroegindewij D, Koes BW et al.** MRI follow-up of posttraumatic bone bruise of the knee in general practice. *Am J Roentgenol* 2007 ; 189 : 556-562.
5. **Born CT, King PJ, Rehman S, Khoury L, Delong WG.** Arthroscopically-assisted removal of retrograde intramedullary femoral nails. *J Orthop Trauma* 2006 ; 20 : 212-215.
6. **Brumback RJ, Wells JD, Lakatos R et al.** Heterotopic ossification about the hip after intramedullary nailing for fractures of the femur. *J Bone Joint Surg* 1990 ; 72-A : 1067-1073.
7. **Brumback RJ, Ellison TS, Molligan H et al.** Pudendal nerve palsy complicating intramedullary nailing of the femur. *J Bone Joint Surg* 1992 ; 74-A : 1450-1455.
8. **Cannada LK, Taghizadeh S, Murali J et al.** Retrograde intramedullary nailing in treatment of bilateral femur fractures. *J Orthop Trauma* 2008 ; 22 : 530-534.
9. **Collado F, Vila J, Beltran JE.** Condylar-cephalic nail fixation for trochanteric fractures of the femur. *J Bone Joint Surg* 1973 ; 55-B : 774-779.
10. **De Campos J, Vangsnæs CT Jr, Merritt PO, Sher J.** Ipsilateral knee injury with femoral fracture. Examination under anesthesia and arthroscopic evaluation. *Clin Orthop Relat Res* 1994 ; 300 : 178-182.
11. **Dickson KF, Galland MW, Barrack RL et al.** Magnetic resonance imaging of the knee after ipsilateral femur fracture. *J Orthop Trauma* 2002 ; 16 : 567-571.
12. **El Moumni M, Leenhouts PA, ten Duis HJ, Wendt KW.** The incidence of non-union following unreamed intramedullary nailing of femoral shaft fractures. *Injury* 2009 ; 40 : 205-208.
13. **Ender J, Simon-Weidner R.** [Fixation of trochanteric fractures with rounded elastic condylar nails.] (in German). *Acta Chir Austriaca* 1970 ; 1 : 40.
14. **Gebhard F, Pokar S, Hehl G et al.** [Minimal invasive removal of implants after retrograde medullary nailing of the distal femur.] (in German). *Unfallchirurg* 2000 ; 103 : 1116-1120.
15. **Green SA.** Distal intramedullary fixation of supracondylar fractures of the femur. *Tech Orthop* 1988 ; 3 : 71-76.
16. **Gregory P, DiCicco J, Karpik K et al.** Ipsilateral fractures of the femur and tibia : treatment with retrograde femoral nailing and unreamed tibial nailing. *J Orthop Trauma* 1996 ; 10 : 309-316.
17. **Hercovici D Jr, Whiteman KW.** Retrograde nailing of the femur using an intercondylar approach. *Clin Orthop Relat Res* 1996 ; 98-104.
18. **Hercovici D Jr, Ricci WM, McAndrews P, DiPasquale T, Sanders R.** Treatment of femoral shaft fracture using unreamed interlocked nails. *J Orthop Trauma* 2000 ; 14 : 10-14.
19. **Holmenschlager F, Piatek S, Halm JP, Winckler S.** [Retrograde medullary nailing of femur fractures with a long nail. A prospective study.] (in German). *Unfallchirurg* 2002 ; 105 : 1100-1108.
20. **Katsoulis E, Court-Brown, Giannoudis PV.** Incidence and aetiology of anterior knee pain after intramedullary nailing of the femur and tibia. *J Bone Joint Surg* 2006 ; 88-B : 576-580.
21. **Krettek C, Rudolf J, Schandelmaier P et al.** Unreamed intramedullary nailing of femoral shaft fractures : operative technique and early clinical experience with the standard locking option. *Injury* 1996 ; 27 : 233-254.
22. **Kröpfl A, Naglik H, Primavesi C, Hertz H.** Unreamed intramedullary nailing of femoral fractures. *J Trauma* 1995 ; 38 : 717-726.
23. **Küntschner G.** A new method of treatment of peritrochanteric fractures. *Proc R Soc Med* 1970 ; 63 : 1120-1121.
24. **Leggon RE, Feldmann DD.** Retrograde femoral nailing : a focus on the knee. *Am J Knee Surg* 2001 ; 14 : 109-118.
25. **Lezius A.** Intramedullary nailing of intertrochanteric and subtrochanteric fractures with curved nail. *J Int College Surg* 1950 ; 13 : 569-572.
26. **Lucas SE, Seligson D, Henry SL.** Intramedullary supracondylar nailing of femoral fractures : a preliminary report of the GSH Supracondylar Nail. *Clin Orthop Relat Res* 1993 ; 296 : 200-206.
27. **McKee MD, Waddell JP.** Intramedullary nailing of femoral fractures in morbidly obese patients. *J Trauma* 1994 ; 36 : 208-210.

28. **Moed BR, Watson JT.** Retrograde intramedullary nailing, without reaming, of fractures of the femoral shaft in multiply injured patients. *J Bone Joint Surg* 1995 ; 77-A : 1520-1527.
29. **Moed BR, Watson JT, Cramer KE, Karges DE, Teefey JS.** Unreamed retrograde intramedullary nailing of fractures of the femoral shaft. *J Orthop Trauma* 1998 ; 12 : 334-342.
30. **Morgan E, Ostrum RF, DiCicco J, McElroy J, Poka A.** Effects of retrograde femoral intramedullary nailing on the patellofemoral articulation. *J Orthop Trauma* 1999 ; 13 : 13-16.
31. **Narasimha Murty A, El Zebdeh MY, Ireland J.** Femoral shaft osteotomy for malunited femoral fractures presenting with varus OA of the knee. *Knee* 2004 ; 11 : 445-449.
32. **Ostrum RF, DiCicco J, Lakatos R, Poka A.** Retrograde intramedullary nailing of femoral diaphyseal fractures. *J Orthop Trauma* 1998 ; 12 : 464-468.
33. **Ostrum RF, Agarwal A, Lakatos R, Poka A.** Prospective comparison of retrograde and antegrade femoral intramedullary nailing. *J Orthop Trauma* 2000 ; 14 : 496-501.
34. **Papadokostakis G, Papakostidis C, Dimitriou R, Giannoudis PV.** The role and efficacy of retrograding nailing for the treatment of diaphyseal and distal femoral fractures : a systematic review of the literature. *Injury* 2005 ; 36 : 813-822.
35. **Reina R, Vilella FE, Ramirez N et al.** Knee pain and leg-length discrepancy after retrograde femoral nailing. *Am J Orthop* 2007 ; 36 : 325-328.
36. **Ricci WM, Bellabarba C, Evanoff B et al.** Retrograde versus antegrade nailing of femoral shaft fractures. *J Orthop Trauma* 2001 ; 15 : 161-169.
37. **Sanders R, Koval KJ, DiPasquale T, Helfet DL, Frankle M.** Retrograde reamed femoral nailing. *J Orthop Trauma* 1993 ; 7 : 293-302.
38. **Swiontkowski MF, Hansen ST, Jr., Kellam J.** Ipsilateral fractures of the femoral neck and shaft. A treatment protocol. *J Bone Joint Surg* 1984 ; 66-A : 260-268.
39. **Tornetta P, III, Tiburzi D.** Antegrade or retrograde reamed femoral nailing. A prospective, randomised trial. *J Bone Joint Surg* 2000 ; 82-B : 652-654.
40. **Tucker MC, Schwappach JR, Leighton RK, Coupe K, Ricci WM.** Results of femoral intramedullary nailing in patients who are obese versus those who are not obese : a prospective multicenter comparison study. *J Orthop Trauma* 2007 ; 21 : 523-529.
41. **Wang JW, Wang CJ.** Total knee arthroplasty for arthritis of the knee with extra-articular deformity. *J Bone Joint Surg* 2002 ; 84-A : 1769-1774.
42. **Winqvist RA, Hansen ST Jr, Clawson DK.** Closed intramedullary nailing of femoral fractures. A report of five hundred and twenty cases. *J Bone Joint Surg* 1984 ; 66-A : 529-539.
43. **Wiss DA, Segal D, Gumbs VL, Salter D.** Flexible medullary nailing of tibial shaft fractures. *J Trauma* 1986 ; 26 : 1106-1112.
44. **Wolinsky PR, McCarty E, Shyr Y, Johnson K.** Reamed intramedullary nailing of the femur : 551 cases. *J Trauma* 1999 ; 46 : 392-399.
45. **Yu CK, Singh VA, Mariapan S, Chong STB.** Antegrade versus retrograde locked intramedullary nailing for femoral fractures : which is better ? *Eur J Trauma Emerg Surg* 2007 ; 2 : 135-140.