



Symptomatic Linburg-Comstock syndrome : a case report

D. SPAEPEN, W. DE MARTELEIRE, LUC DE SMET

The authors report the case of a 39-year-old woman with pain in the right dominant hand after initiating a crafts course. Clinical examination revealed tenderness on the volar side of the thumb and wrist. Simultaneous flexion of the distal interphalangeal joint of the index finger with flexion of the interphalangeal joint of the thumb was observed. Operative procedure confirmed the presumed diagnosis of an anomalous connection between the flexor pollicis longus and the flexor digitorum profundus tendon to the index finger, first described in 1979 by Linburg and Comstock.

INTRODUCTION

In 1979 Linburg and Comstock described a pain syndrome due to an anomalous connection between the FPL (flexor pollicis longus) and the tendon of the FDP (flexor digitorum profundus) to the index finger, which obstructs independent flexion of these fingers. Typically pain was noted at the distal level of the forearm, at the site of the connection. We present a symptomatic case.

CASE REPORT

A 39-year-old nurse presented to the outpatient clinic with chronic, activity-related pain on the volar aspect of the thumb and wrist. No acute trauma was mentioned, but she thought the pain had started seven months earlier, after initiating a crafts course. Besides the pain, she also complained about "instability", noting that she had to fix the thumb in flexion to be able to grasp. This eventually lead to a minor lack of extension and pain in the

forearm on certain activities. She never noticed any problem with the index finger. There was no triggering of the thumb or index.

On physical examination there was tenderness over the flexor pollicis longus tendon. Although the A1 pulley region was involved, the flexor pollicis longus tendon was tender on palpation from the IP (interphalangeal) joint up to proximal to the thenar eminence. Further examination revealed simultaneous flexion of the DIP (distal interphalangeal joint) of the index and the IP of the thumb (fig 1). Radiographs and ultrasonograms were completely normal. The diagnosis of a Linburg-Comstock syndrome was suggested and operative exploration was proposed.

At the A1 pulley no abnormalities on the FPL was observed ; at the second incision, made on the radial side of the flexor carpi radialis tendon at the wrist, the FPL was identified and mobilisation of this tendon gave simultaneous flexion of the IP of the thumb and the DIP of the index finger. The FDP to the index was also identified and mobilisation also gave flexion of the DIP of the index finger. Dissection was continued more distally and an obvious connection (2 mm in width) was found from the FPL proximally to the index finger FDP somewhat more distally (fig 2). After excision of

From the Department of Orthopaedic Surgery, U.Z. Pellenberg, Lubbeek, Belgium.

Correspondence : Luc De Smet, Department of Orthopaedic Surgery, U.Z. Pellenberg, Weligerveld 1, B-3212 Lubbeek (Pellenberg), Belgium.

E-mail : luc.desmet@uz.kuleuven.ac.be.

© 2003, Acta Orthopædica Belgica.

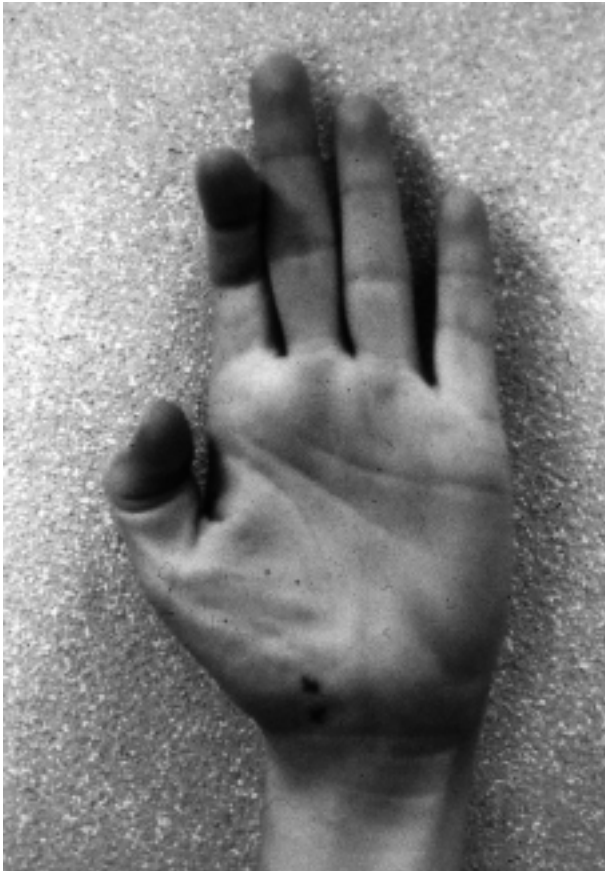

Fig. 1. — Clear demonstration of the patient's simultaneous flexion of the IP of the thumb and the DIP of the index finger. (X) indication of the tender spot.

this connection, independent movement of the FPL and index finger FDP could be demonstrated. Postoperatively, immediate mobilisation of the fingers was encouraged.

One month after the procedure the patient stated that the pain had gone completely and that there were no more "instability" problems. Physical examination confirmed independent and painless flexion of the IP of the thumb and the index finger DIP.

DISCUSSION

A trigger finger is a common disorder often diagnosed and surgically treated in an orthopaedic practice. In this case the somewhat atypical complaint of instability and the more diffuse pain over

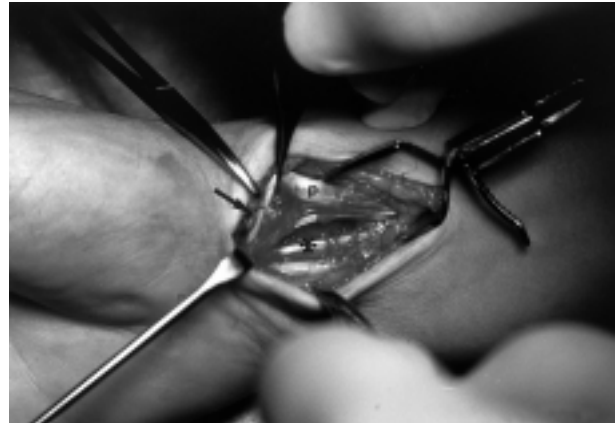


Fig. 2. — Tendinous connection (arrow) between the deep flexor of the index (*) and the flexor pollicis longus (p).

the volar aspect of the thumb lead to a more thorough examination and to the diagnosis and treatment of a Linburg-Comstock syndrome. Lombardi *et al* (4) at the Mayo Clinic reported on 33 symptomatic cases of which 22 were eventually treated surgically ; an anomalous connection was found in 15 cases and they all had improvement after resection of the connection.

Linburg and Comstock (3) have reviewed 194 asymptomatic patients and found the clinical sign in 89 cases of which 28 were bilateral. Allieu *et al* in 1995 (1) examined 236 asymptomatic individuals and found the clinical sign in 97 cases (36%) of which 24 were bilateral. They extended their survey and found similar data (2). In an anatomic dissection study they found 7 connections in 26 cadaver hands. They distinguished 3 types of connection : the most frequent one was a tendinous structure connecting the FDP of the index with the FPL ; in two clinical cases, there was a unique muscle with a bifid tendon for the thumb and index (1, 2, 5) and in ancient anatomical works (referred to in (2)) a common muscle with 5 tendon slips for the thumb and the long fingers has been described. These findings suggest that an additional tendinous connection between the FPL and the index finger FDP is a common anomaly, not necessarily causing pathology. If, however this clinical sign is found in a patient presenting with prolonged activity-related pain on the volar side of the thumb

or wrist, we suggest a surgical exploration and excision of the connection, if present (1, 2, 5, 6).

REFERENCES

1. **Allieu Y, Hamitouche K, Roux JL, Baeten Y.** Unique surgical conditions. In : Winspur & Wynn Parry (eds) : *The Musician's Hand*. Ed, Martin Dunitz, London, 1998, pp 143-148.
2. **Hamitouche K, Roux JL, Baeten Y, Allieu Y.** Syndrome de Linburg-Comstock. Etude épidémiologique et anatomique, implications cliniques. *Chir Main* 2000 ; 19 : 109-115.
3. **Linburg RM, Comstock BE.** Anomalous tendon slips from the flexor pollicis longus to the flexor digitorum profundus. *J Hand Surg* 1979 ; 4 : 79-83.
4. **Lombardi RM, Wood MB, Linscheid RL.** Symptomatic restrictive thumb – index flexor tenosynovitis ; incidence of musculotendinous anomalies and results of treatment. *J Hand Surg* 1988 ; 13-A : 325-328.
5. **Rico Aguanda A, del Pino Paredes V.** Flexor digitorum profundus common to thumb and index finger, associated with a post traumatic distal adherence of both tendons. *J Hand Surg* 1988 ; 13-B : 72-74.
6. **Takami H, Takahashi S, Ando M.** The Linburg Comstock anomaly : A case report. *J Hand Surg* 1996 ; 21-A : 251-252.