



Fishtail deformity as a result of a non-displaced supracondylar fracture of the humerus

Daniel W. SCHULTE, Leonhard E. RAMSEIER

From the University Children's Hospital Zurich, Zurich, Switzerland

Fishtail deformity is a very rare complication of undisplaced supracondylar fractures of the humerus in children. We report the case of a 10-year old girl presenting with pain in the right elbow eight years after a non-displaced supracondylar fracture of the humerus. Radiographs also demonstrated necrosis of the lateral part of the trochlea and of the head of the radius. With this long term clinical and radiographic follow-up after a non-displaced supracondylar fracture of the humerus, we would like to point out the possibility of the development of this very rare deformity.

Keywords : undisplaced supracondylar fracture ; children ; humerus ; fishtail deformity.

INTRODUCTION

Supracondylar fracture of the humerus is the most frequent type of elbow fractures in children (1). Nonunion of the lateral humeral condyle, cubitus varus, cubitus valgus and fishtail deformity are rare complications of these injuries. Fishtail deformity is a well known complication from radial condyle fractures (7) but have been described as well as a consequence of nearly any fractures involving the distal humerus in children (2). This includes supracondylar fractures, T-condylar fractures of the distal humeral condyles and fractures of the ulnar condyle. The deformity can occur even with absent or minimal displacement of the fracture fragments (5). The fishtail deformity becomes radiologically visible as a characteristic form of the dis-

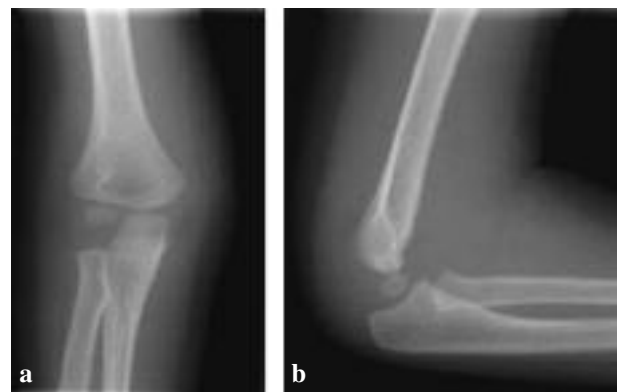

Fig. 1. – Anteroposterior (a) and lateral (b) radiographs of the elbow at time of trauma.

tal end of the humerus at the beginning of ossification of the trochlea between the age of 7 and 8 years (4).

Pathologic studies explained the aetiology of the deformity either by partial growth arrest of the epiphysis (3) or by vascular injury (6,8,9).

■ Daniel W. Schulte, MD, Resident.

Department of Paediatric Surgery, University Children's Hospital Zurich, Switzerland.

■ Leonhard E. Ramseier, MD, Orthopaedic Surgeon.

Division of Orthopaedics, University Children's Hospital Zurich, Switzerland.

Correspondence : L. Ramseier, Division of Orthopaedics, University Children's Hospital Zurich, Switzerland.

E-mail : leonhard.ramseier@kispi.uzh.ch

© 2009, Acta Orthopædica Belgica.

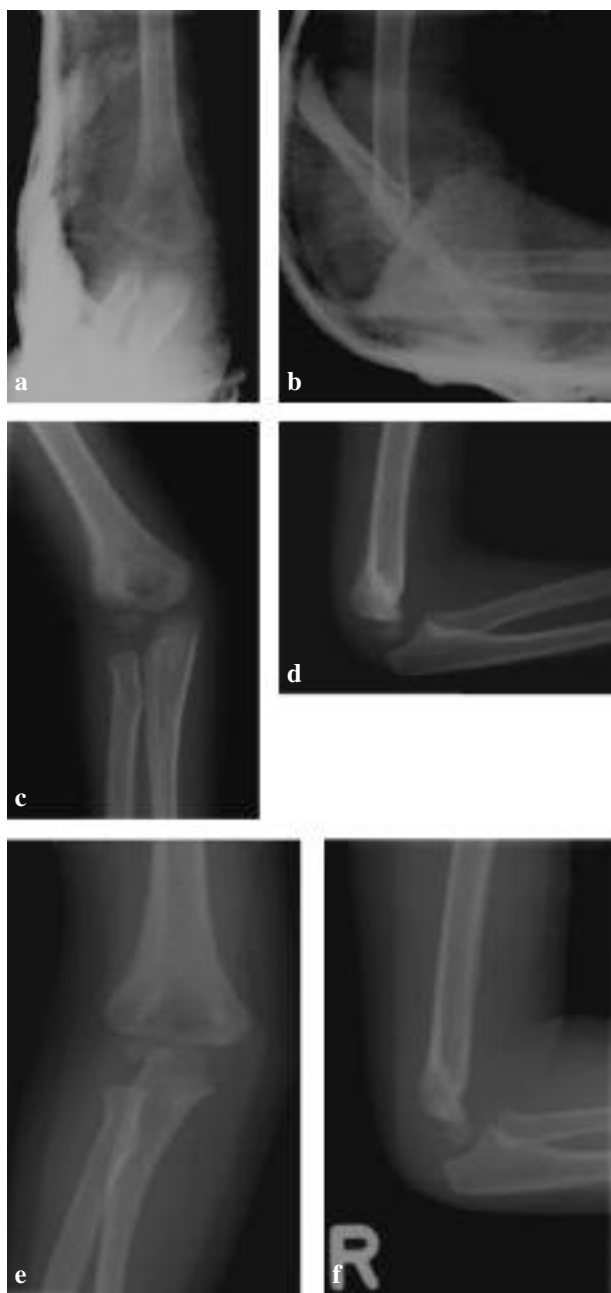

Fig. 2. – Anteroposterior and lateral radiographs 1 week (a, b), 3 weeks (c, d) and 4 weeks (e, f) after the initial injury ; consolidation in anatomic position.

CASE REPORT

At the age of two, a girl sustained a non-displaced supracondylar fracture of the right humerus (fig 1). It was treated with a cast and controlled with

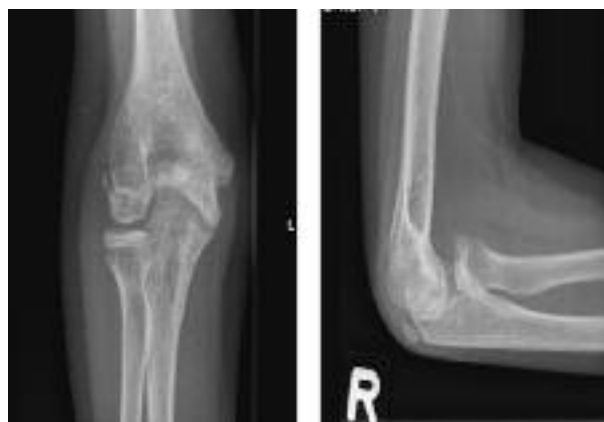

Fig. 3. – Radiograph of the distal humerus with fishtail deformity of the girl 8 years after trauma.

radiographs of the elbow after 1, 3 and 4 weeks (fig 2). At the 1-month follow-up the carrying angle and the range of motion were completely normal. Radiographs at follow-up showed a healed fracture with no secondary displacement. Eight years after the accident the girl consulted the outpatients' department because of a pain in the right elbow. The family denied any new trauma since the fracture 8 years previously. The mobility was 130° in flexion and -15° in extension. On the radiograph a fishtail deformity was evident (fig 3). Magnetic resonance imaging (MRI) also showed a small chondral defect of the capitulum humeri and the radial head (fig 4).

DISCUSSION

We report the case of a fishtail deformity of the distal humerus seen in a 10-year old girl, eight years after a non-displaced supracondylar fracture. Fishtail deformity is a very rare complication of fractures of the distal humerus in children, mostly seen after fractures of the radial condyle. The deformity is extremely rare after non-displaced fractures of the end of the humerus. There are only a few cases reported in literature. In 1984 Morrissy and Wilkins (5) reported 5 cases of complications which consisted of dissolution of a variable portion of the trochlea noted at different time intervals after the fracture, including one non-displaced supracondylar fracture. In that study the severity of the fracture

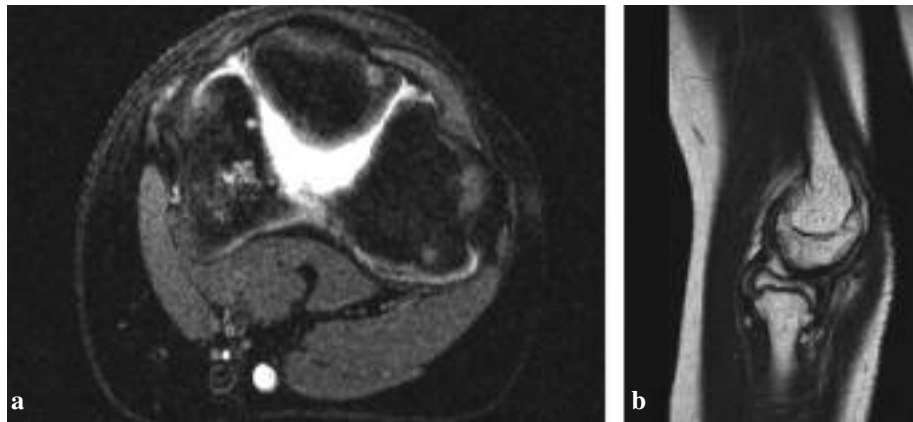


Fig. 4. – Coronal (a) and sagittal (b) MRI of the distal humerus demonstrate necrosis of the trochlea and radial head

did not correlate with the severity of the posttraumatic fishtail deformity.

Studies of the microcirculation of the distal end of the humerus (8), surgical observations (8,9) and MRI findings suggest vascular compromise as an explanation for this defect. Yang *et al* (8) have reported on the vascular supply to the distal end of the humerus. The vessels in the epiphyseal cartilage are end arteries and there is no communication between the ossification centers of the capitellum and the trochlea. Disruption of these vessels might disturb the growth of the epiphyseal cartilage. In some cases described in the literature, avascular necrosis was evident in combination with fishtail deformity (2).

In our case the fracture healed in a non-displaced position, and no primary or secondary displacement was seen. The deformity may thus also develop over time in non-displaced, well healed fractures. Considering the mild initial trauma, partial arrest of epiphyseal growth appears as an unlikely pathogenic mechanism. Most features lend support to the vascular hypothesis.

In the case reported here, the girl presented in our clinic only because of pain and functional limitation, eight years after the initial trauma. Because of the possibility of developing this deformity it is necessary to be aware of the possibility of a fishtail deformity if pain or loss of elbow motion occur in a child after any fracture involving the distal humerus.

REFERENCES

1. **Bhatnagar R, Nzegwu NI, Miller NH.** Diagnosis and treatment of common fractures in children : femoral shaft fractures and supracondylar humeral fractures. *J Surg Orthop Adv* 2006 ; 15 : 1-15.
2. **Bronfen CE, Geffard B, Mallet JF.** Dissolution of the trochlea after supracondylar fracture of the humerus in childhood : an analysis of six cases. *J Pediatr Orthop* 2007 ; 27 : 547-550.
3. **Fowles JV, Kassab MT.** Displaced fractures of the medial humeral condyle in children. *J Bone Joint Surg* 1980 ; 62-A : 1159-1163.
4. **McCarthy SM, Ogden JA.** Radiology of the postnatal skeletal development. V. Distal humerus. *Skeletal Radiol* 1982 ; 7 : 239-249.
5. **Morrissy RT, Wilkins KE.** Deformity following distal humeral fracture in childhood. *J Bone Joint Surg* 1984 ; 66-A : 557-562.
6. **Nwakama AC, Peterson HA, Shaughnessy WJ.** Fishtail deformity following fracture of the distal humerus in children : historical review, case presentations, discussion of etiology, and thoughts on treatment. *J Pediatr Orthop* 2000 ; 9-B : 309-318.
7. **von Laer LR.** [Fracture of the radial condyle of the humerus in the growth period.] (in German). *Unfallchirurg* 1998 ; 101 : 271-279.
8. **Yang Z, Wang Y, Gilula LA.** Microcirculation of the distal humeral epiphyseal cartilage : implications for post traumatic growth deformities. *J Hand Surg* 1998 ; 23 : 165-172.
9. **Yoo CI, Suh JT, Suh KT.** Avascular necrosis after fracture-separation of the distal end of the humerus in children. *Orthopedics* 1992 ; 5 : 959-963.