



Single-stage bilateral total hip arthroplasty in patients less than 35 years *Forty arthroplasties with 5-17 years follow-up*

Jean-Pierre SIMON, Evelyne ROBBENS, Michael MAES, Johan BELLEMANS

From the University Hospital Pellenberg, Leuven, Belgium

Between 1991 and 2003, the senior author performed 42 bilateral total hip arthroplasties as a single-stage procedure in 21 patients less than 35 years old. One patient was lost to follow-up, leaving 40 total hip arthroplasties in 11 male and 9 female patients for review, with a mean follow-up of 9.7 years (5-17 years). The mean age at the index operation was 25.2 years (range 17 to 34 years). The underlying hip disease was inflammatory arthritis in 13 patients and avascular necrosis in 7 patients. The femoral implants were cemented polished, tapered stems in all patients. Cementless porous-coated acetabular components were used in 34 hips, cemented metal backed cups in 4 hips and all polyethylene cemented cups in 2 hips. Clinical evaluation with the Charnley modification of the Merle-d'Aubigné Postel score showed significant improvement after surgery. In a questionnaire concerning their daily activities, professional occupation, social life and sexual activity all but one patient rated the result of their bilateral THA as good or excellent and stated they would have repeated the intervention if necessary. All patients were able to walk without any walking aid within 3 months after surgery. There were no differences in the outcome between the two groups of patients. Three metal backed cemented cups in 2 patients failed and had to be revised at 11, 13 and 16 years after the primary operation. Radiographic analysis of the surviving cups showed radiolucencies in one metal backed cemented and one uncemented socket. Femoral lucencies appeared in two hips, and calcar resorption in three femurs. With a mean follow-up of 9.7 years the survival of the

cemented polished femoral components is 100%. One patient had grade 2 heterotopic ossifications in both hips. There was one superficial wound infection. No other complications occurred. Bilateral single-stage conventional total hip arthroplasty provided favorable medium term results in patients less than 35 years-old without any major or minor complications.

Keywords : bilateral single-stage total hip arthroplasty ; young patients.

INTRODUCTION

A variety of diseases may affect the hip joint in children, in adolescents or in young adults, resulting in early secondary degenerative hip arthritis.

-
- Jean-Pierre Simon, MD, PhD, Professor in Orthopaedics.
 - Evelyne Robbens, MD, Orthopaedic Resident.
 - Michael Maes, MD, Orthopaedic Resident.
 - Johan Bellemans, MD, PhD, Professor in Orthopaedics and Chairman.

Department of Orthopaedic Surgery, University Hospital Pellenberg, Leuven, Belgium

Correspondence : Jean-Pierre Simon, University Hospital Pellenberg, Weligerveld 1, B-3212 Leuven, Belgium.

E-mail : jean-pierre.simon@uz.kuleuven.ac.be

© 2009, Acta Orthopædica Belgica.

*No benefits or funds were received in support of this study
This study has been approved by the Hospital Ethics
Committee.*

Pain, disability for activities of daily living, sexual problems and limitations to carry out a professional occupation may require a total hip arthroplasty (THA) in young patients with end-stage arthritis of one or both hips. Young age and high activity levels subject the implant to repetitive and longstanding stress, resulting in wear which may possibly lead to premature failure of the components. In addition, in patients with inflammatory arthritis, THA is compromised by the intake of non steroidal anti-inflammatory drugs (NSAID), steroid use and autoimmune disease which negatively affect the bone quality and may increase the risk for infection.

The results of conventional, non resurfacing THA in young patients reported in the literature are controversial. Some studies have shown poor or fair outcomes with high failure rates at medium term follow-up (42). Others have reported more favourable results with both cemented and uncemented implants (33,36). The optimal fixation method for a conventional THA remains debatable (1,2,8,27,33,38,40). By and large the acetabular component is the weakest part of the artificial construct, particularly if cemented, and there is a general tendency towards the use of uncemented cups (41). Another concern is the fact that in conditions such as inflammatory arthritis and avascular necrosis both hips are frequently involved. For that reason many patients require a bilateral THA and may benefit from a single-stage bilateral surgical intervention. The advantages of a single-stage THA in this population are obvious: one-time administration of anaesthesia, decreased overall hospital stay, a single recovery period, faster rehabilitation, reduction in cost and shorter absence from professional life. Especially patients with marked fixed flexion deformities of both hips and severe restriction of mobility are good candidates for a one-stage THA. Both problems are common in patients with early onset inflammatory arthritis.

A number of studies have shown that the complication rate is not significantly higher for a bilateral single-stage THA and that a single-stage bilateral THA is as safe as the staged procedure provided medically high-risk patients are excluded (4,34,35).

Our study was conducted to evaluate the subjective, clinical and radiographic results of a bilateral

single-staged THA in patients less than 35 years at the index operation.

PATIENTS AND METHODS

Demographics

Using the institutional database for THA we identified 21 patients who had a bilateral single-stage THA (42 hips) and who were younger than 35 years when they had their intervention between 1991 and 2003. One patient could not be traced for follow-up and was excluded from the study, leaving 20 patients with 40 THAs for review. One patient with a bilateral THA died in a car accident in 2005, 8 years after his operation with both hip prostheses working well. This was confirmed by the patients' parents. Radiological follow-up for this patient was 6 years. This patient was included in the study. The mean age of the patients at the time of surgery was 25.2 years (range 17 to 34 years). There were 11 male and 9 female patients. The mean height of the patients was 169 cm (range 158 to 180 cm). The mean weight at the time of surgery was 61 kg (range 45 to 95 kg) and the mean body mass index (BMI) was 21.6 kg/m² (range 16.1 to 34.9 kg/m²) (table I).

Preoperative diagnosis

The preoperative diagnosis was inflammatory disease in 13 patients and avascular necrosis of the femoral head in 7 patients. Of the 13 patients with inflammatory disease there were 2 patients with ankylosing spondylitis, 8 with juvenile onset rheumatoid arthritis, 1 with enteropathic related arthritis and 2 patients with rheumatoid arthritis. The causes of the avascular necrosis of the femoral head were steroid intake in 5 patients, alcohol abuse in 1 and idiopathic in 1 patient. In the entire group 9 patients used steroids preoperatively, while NSAID's were taken by 11 patients. Two patients with osteonecrosis of the femoral head had a core decompression of both hips before their total hip replacement. Three patients with inflammatory arthritis had received other joint replacements: one patient had bilateral total shoulder arthroplasty, another patient had unilateral total shoulder replacement and the third patient had unilateral total knee arthroplasty.

Surgical data

All patients had the same pre-, intra- and post-operative treatment. During the 24 hour perioperative

Table I. — Patient demographics

	Number	Mean Age (years)	Mean Weight (kg)	Mean Height (cm)	Mean BMI (kg/m ²)	Use of Steroids	Use of NSAID	Core Decompression	Other Arthroplasties
Male	11	25	63,2	170	22,0	7	8	0	4
Female	9	25,5	58,4	166	21,1	2	3	2	0
	20	25,2	61,1	169	21,6	9	11	2	4

period they all received 2 gram Na-cefalozine, IV tid. Thromboprophylaxis was started the day before surgery with 20 mg enoxaparine and was continued with a dose of 40 mg daily during 6 weeks in combination with compression stockings. To prevent heterotopic ossification, piroxicam was started with 20 mg the night before surgery and was continued for a period of 8-10 days. This was combined with ranitidine 75 mg once daily during 8-10 days which was also started the night before surgery to prevent gastro-intestinal ulceration. All operations were carried out under general anaesthesia by the same surgeon (JPS), in a clean air enclosure using total body exhaust suits. The patients were positioned in lateral decubitus and a posterolateral approach was used. After the first operation, the patient was repositioned on the contralateral side and newly draped. This obviously lengthens the procedure compared to single-stage THA through a lateral approach in dorsal decubitus. Modern cementing techniques were used, with the exception of vacuum mixing, for all femoral components. This included thorough bone bed preparation by pulsatile lavage, and a bone plug as distal cement restrictor. Simplex P™ (Stryker Inc) antibiotic hand mixed cement was used for all femoral components. Cement was applied in a retrograde fashion with a cement gun and was pressurised using a proximal Sorbothane® (Stryker Inc, Caen, France) seal.

Thirty-two femoral components were polished double tapered cemented Exeter™ (Stryker Inc, Caen, France) stems and 8 were polished triple tapered cemented MS 30™ (Zimmer Inc, Warsaw, Indiana) stems. Four types of acetabular components were used. Thirty-four cups were press fit porous coated, of which 20 Morscher™ cups (Zimmer Inc, Warsaw, USA, formerly Sulzer Orthopedics, Switzerland) and 14 Trilogy™ cups (Zimmer Inc, Warsaw, Indiana). One of the differences between the two uncemented cups is the presence of cluster holes for additional screw fixation in the Trilogy™ cup. The 6 remaining cups were cemented cups, of which 4 Exeter™ cemented metal backed

acetabular components (Stryker Inc, Caen, France) and 2 all polyethylene cups (Zimmer Inc, Warsaw, Indiana).

All patients were mobilized immediately ; full weight bearing was allowed from the first or second day postoperatively. All patients received daily physiotherapy during hospitalisation. Walking with 2 crutches was recommended for the first 6 weeks, although their use could be reduced progressively. Patients who had difficulties using two crutches because of upper limb involvement were allowed full weight bearing with a single crutch or without crutches.

Follow-up and functional evaluation

Patients were seen at 6 weeks, 3 months and 1 year postoperatively. Thereafter clinical and radiographic follow-up took place every 2 years. Clinical evaluation was done preoperatively and at each follow-up examination using the Charnley modification (6) of the Merle d'Aubigné-Postel (29) (CMD) grading system which registers pain, range of motion of the hip joint and function and has a maximum score of 18 points. Furthermore, a questionnaire was filled in by all patients, except the one who died, to reveal their impression about activities of daily life (ADL), the impact of the THA on personal hygiene, social and professional life and satisfaction level after surgery. A separate part was dedicated to the effect of THA on sexual activity. For the subjective evaluation of pain, a Visual Analogue Score (VAS) was used. Patients could indicate their level of pain in rest and during activity with the aid of a ruler on a scale from zero to 10, in which 10 means severely disabling, continuously present pain and zero no pain at all. This was done separately before and after surgery. Patients could grade their satisfaction level as excellent, good or poor.

Radiographic evaluation

Radiographic assessment was done by evaluating and comparing serial anteroposterior radiographs of the

pelvis and lateral radiographs of both hips taken at each visit. Special attention was given to the appearance and evolution of radiolucent lines between the 6 weeks and latest follow-up radiographs. The proximal femur was divided into 7 zones according to the method of Gruen *et al* (17). The circumference of acetabular bone cement interface or bone cup interface was divided in zones type I to III according to the classification of DeLee and Charnley (12). Heterotopic ossification was classified according to Brooker *et al* (5).

Statistical analysis

Survival probability of the implant was estimated including the patient who was lost to follow-up and thus censored (32). Both revision of acetabular and/or femoral component were taken as endpoint for the overall survival of the total hip replacement. When the survival probability of the acetabular or femoral implant was calculated separately, only failure of that specific component was considered as an endpoint. Student's t-test was used to evaluate the pre-and postoperative hip scores. The significant level was set at $p < 0.05$.

RESULTS

Functional outcome

The mean follow-up was 9.7 years (range 5-17 years, SD 3.3 years). The median follow-up was 9 years, with 9 patients having more than 9 years, 7 patients having less than 9 years and 3 patients having 9 years follow-up. The mean hospital stay was 13.4 days (range 5 to 22 days). We compared this to an age matched group of patients with comparable pathology during the same period, but who had a single-stage THA. The mean length of stay of the latter group was 11.5 days. Only one patient with alcohol induced avascular necrosis required a blood transfusion with 2 units of packed cells.

The overall preoperative CMD score for the entire group was 8.3 points. The mean preoperative CMD score was 7.42 points in patients with inflammatory disease and 10 points in patients with avascular necrosis of the femoral head. Furthermore, the patients were classified in category A, B or C, with A comprising all patients fit for age except for the affected hip, B all patients with both hips affected but otherwise fit for age and C all patients who had

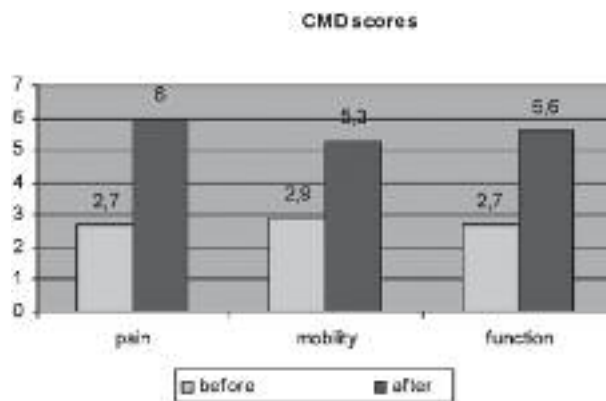


Fig. 1. — CMD scores pre- and postoperatively. Improvement after surgery is statistically significant.

limitations other than from the hips. All patients with inflammatory disease (13) were classified into category C, the others (7) into category B. The mean preoperative CMD scores in male and in female patients did not differ significantly. The mean postoperative CMD score was 16.9 points, which is an improvement of more than 50% in comparison with the overall preoperative score. Pain improved from 2.7 points preoperatively to 6.0 points postoperatively, range of motion improved from 2.9 to 5.3 points and function from 2.7 to 5.6 points (fig 1).

There was no statistically significant difference in the postoperative CMD score between the different subgroups. The average postoperative score was 16 points in patients with cemented cups and 16.7 points in patients with cementless press-fit porous cups. This difference was not statistically significant. The mean postoperative CMD score was 16.4 points in male and 16.9 points in female patients. Again, this difference was not statistically significant.

On the VAS score the mean rest pain was 7.6 preoperatively and 1.1 postoperatively. The mean pain during activity was 9.4 and 1.3 respectively. Improvement in the VAS scores after surgery was statistically significant (fig 2).

All patients voluntarily filled in a questionnaire concerning daily activities, professional life, social life and sexual activity. All but one patient were

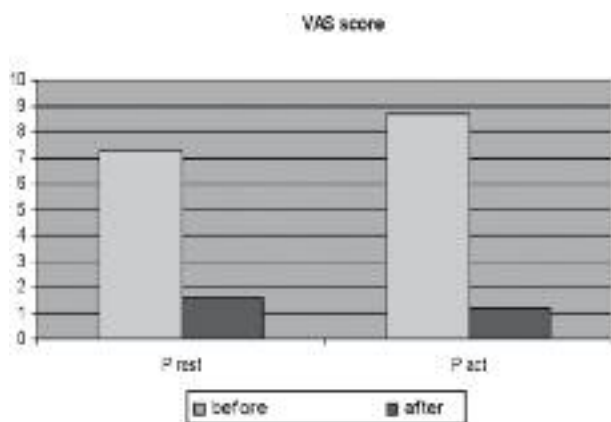


Fig. 2. — VAS scores pre- and postoperatively evaluating pain at rest and during activity. Improvement after surgery is statistically significant.

sexually active after surgery. Fourteen patients stated that total hip replacement had improved their sexual activities, while 3 answered that surgery did not have an influence on that domain. Two patients did not answer this question. Six patients had children, of which 4 female and 2 male patients. Two female patients already had two children and 1 female patient had 1 child before surgery. One woman gave birth to 4 children after her bilateral total hip replacement, including twins. Pregnancy in this patient was uncomplicated, and birth of all 4 children, including her twins was possible through vaginal delivery. One male patient fathered two children after surgery. Three patients were unemployed, of which two patients with severe juvenile rheumatoid arthritis and one male patient with Huntington's disease. All the other patients were employed, but two changed their occupation after surgery. All patients except two considered their social life to be improved since surgery. Sixteen patients considered the result of the procedure as excellent, while three patients rated the result as good and one as fair. All patients, except one, would have the procedure again as a single-stage operation. The only patient who was in doubt about repeating the surgery had a bilateral THA for alcohol induced avascular necrosis of the femoral head. This was the patient with bilateral heterotopic

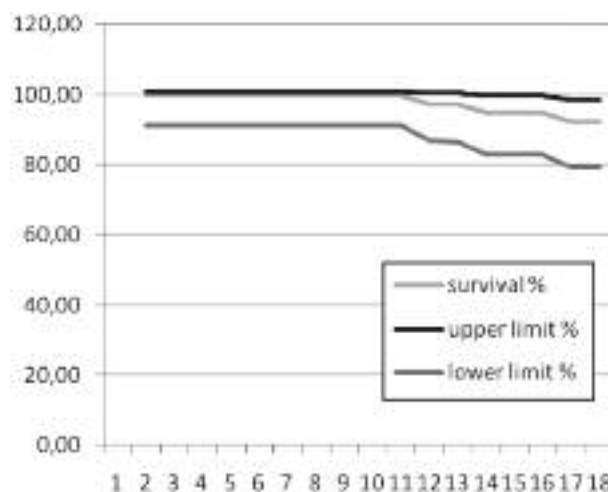


Fig. 3. — Survival analysis for the cups with 95% confidence interval.

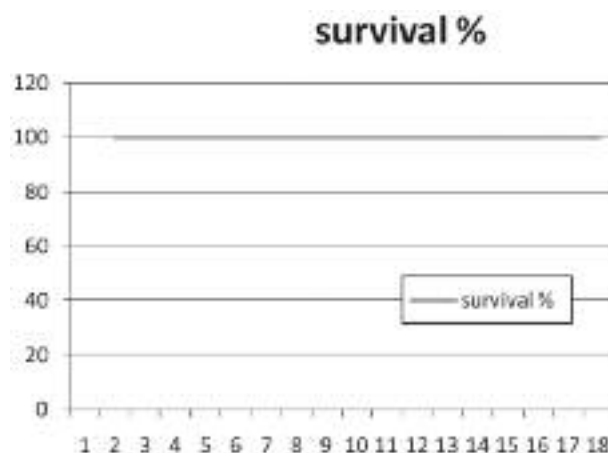


Fig. 4. — Survival analysis for the stem : 100% survival after 17 years.

ossifications. Hip joint mobility in this patient was restricted and he still had a limp 6 years after surgery.

Survivorship analysis, with revision as the end point for failure, revealed an overall survival of the total hip replacements of 100% at 10 years post-operatively, 94.8% at 15 years after surgery and 92% at 17 years. Survival rate of the acetabular components was 100%, 94.8% and 92% respectively. Survival rate of the femoral components was 100% at 10, 15 and 17 years after surgery (fig 3 & 4).

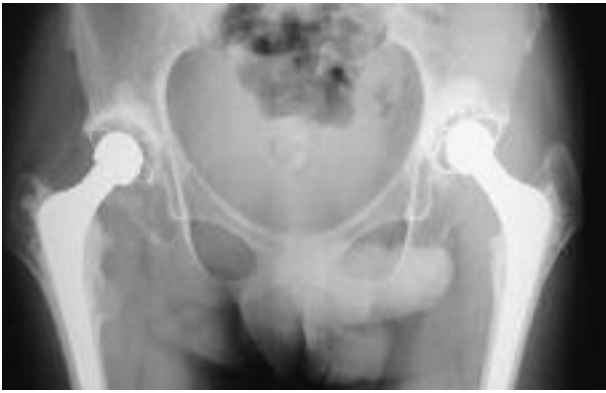

Fig. 5. — Sixteen year follow-up of a bilateral single-stage THA in a patient with juvenile arthritis.

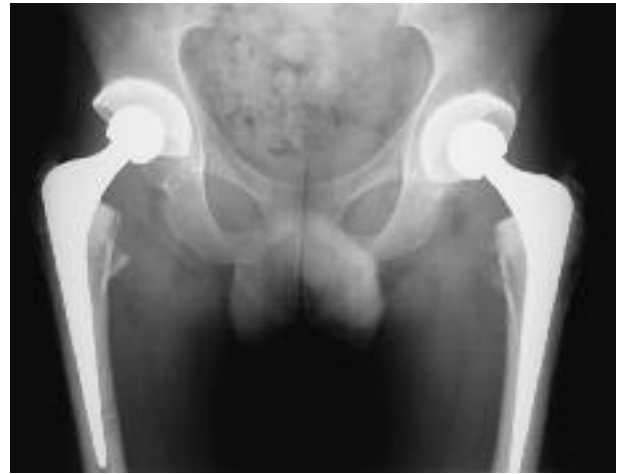

Fig. 6. — Ten year follow up of a bilateral single-stage THA for bilateral avascular necrosis.

Radiographic findings

A summary of the radiographic findings is presented in table II. No radiolucent lines were seen in Gruen zone I excluding the radiolucent line between the stem shoulder and cement, a normal observation due to subsidence of the polished wedge shaped stems. Seven proximal femurs showed calcar rounding off in zone 7. Three femurs had definite calcar resorption in zone 7 and this was associated with polyethylene wear and cup loosening of the metal backed cups for which revision was necessary at 11, 13 and 16 years postoperatively. Two femoral components were associated with non progressive radiolucent lines that were less than 2 mm wide and confined to 1 or 2 zones. In 95% of cases, no radiolucent lines were visible at the latest follow-up at the bone-cement or cement-prosthesis interface in the femur (fig 5 & 6).

Evaluation of the acetabulum according to the DeLee and Charnley classification revealed 3 loose metal backed cups with proximal migration and acetabular bone loss. These cups were revised. Radiolucencies were noted in zone I in 5 hips. Of these 5 cups that had radiolucent lines, 4 were Morscher™ cups and 1 was the unrevised metal backed cemented cup. In 5 cementless Morscher™ cups a demarcated osteolytic zone in the ilium was noted in zone 2 without the presence of a radio-

Table II. — Radiographic results

Radiolucencies acetabular component	Number
Zone I	5
Loosening	3
Subchondral stress shielding zone II	5
Radiolucencies femoral component	Number
Zone 1 + 2	1
Zone 1 + 7	1
Calcar resorption zone 7	3
Heterotopic ossifications	Number Hips
Grade II	1
Grade III	1

lucent line at the cup bone interface. Such radiolucent areas were not associated with any signs of cup loosening but were presumably due to stress shielding of the subchondral bone. Migration was seen only in cemented cups, while none of the press-fit cups had any evidence of definite or probable loosening radiographically.

Revisions and complications

As all cemented femoral components survived, no revisions occurred on the femoral side. There were 3 revisions for aseptic loosening of cemented metal backed acetabular components at 11, 13 and

16 years postoperatively. All failed acetabular components were replaced with an uncemented cup.

A superficial wound infection was noted in one patient. There were no deep infections. Hence the incidence of infection was very low in this series of THR's considering the immune-compromised condition of some of the patients. No complications were noted related to the use of NSAID or steroids. None of the patients developed deep venous thrombosis or pulmonary embolism during hospitalisation. No femoral fractures occurred intraoperatively with the insertion of the prosthesis, and no periprosthetic fractures or dislocations were identified later during the course of the study.

Brooker grade II heterotopic ossifications were found in both hips of one patient which led to restriction of active and passive mobility.

DISCUSSION

Total hip replacement for pain, disability for activities of daily life, sexual problems and limitations to carry out a normal profession caused by hip pathology in juvenile patients has been much debated in literature. The main concern remains the high activity level and repetitive loading that make the components more susceptible to wear, which may lead to accelerated failure. New bearing materials, such as large metal-on-metal articulations, cross-linked polyethylene and more fracture resistant ceramic-on-ceramic bearings attempt to overcome these problems. At the present time no long term, even not medium term follow-up studies are available for these articulations in very young people, while longer outcome studies only reveal results on conventional THA.

In conventional THA mediocre results are particularly due to a high rate of aseptic loosening of cemented acetabular components, usually beginning at five years postoperatively and increasing thereafter. Collis (9) reported a 15 year survival rate of only 69% of cemented acetabular components in patients younger than 50 years old. Barrack *et al* (2), in a study of 50 total hip arthroplasties performed with second generation cementing techniques, reported that 22 hips (44%) had radiographic signs of loosening of the acetabular implant and that 11

(22%) had a revision of the cup after a mean follow-up of 12 years. Ballard *et al* (1) reported that improved cementing techniques did not decrease the rate of aseptic loosening of cemented acetabular implants in young patients. In a population of 42 patients less than 50 years old, they had an overall acetabular failure rate of 36% and an acetabular revision rate of 24% after a minimum duration of follow-up of 10 years. Dorr *et al* (13) reported a revision rate of 12% at 4.5 years, 33% at 9.2 years and 67% at 16.2 years in 49 cemented hips in patients less than 45 years old. The revision rate for patients less than 30 years old at index total hip arthroplasty was 82% compared with 56% for patients older than 30 years. Therefore, in the mid and late 80's, uncemented porous-coated acetabular implants gained in popularity. Several studies have demonstrated lower rates of loosening and have showed excellent results for uncemented porous-coated cups in younger patients. Berger *et al* (3), in a study of 78 total hip replacements performed with porous-coated acetabular implants in 66 patients younger than 50 years old, reported that none of the hips had acetabular loosening and only 7.4% had osteolysis after a mean follow-up of 8.8 years. Crowther *et al* (10), in a study of 56 hips in 44 patients less than 50 years treated with press-fit uncemented porous-coated acetabular implants with additional fixation with multiple screws, reported a survival rate of 98% after a mean follow-up of eleven years. None of the cups were revised because of aseptic loosening but pelvic osteolysis was seen in 23% and radiolucent lines were seen in 29% of the hips, although these were asymptomatic. Duffy *et al* (15), in a study of 72 patients less than 40 years old treated with uncemented first generation porous-coated implants, reported higher failure rates of the acetabular component. Modern second generation uncemented implants, however, have improved designs. Kim *et al* (22,23), in a study of 118 second generation cementless total hip replacements in 80 patients younger than 50 years old, reported that only one hip (1%) had a revision of both components because of recurrent dislocation. Kaplan-Meier survival analysis showed a survival rate of 99% of acetabular and femoral components with revision as endpoint, and a

survival rate of 100% with aseptic loosening as endpoint. There was, however, a high rate of polyethylene wear, which remains a major concern in young patients, but there was a low prevalence of osteolysis (12%).

One of the most frequent causes for hip joint destruction in young individuals is inflammatory disease such as juvenile or adult-onset rheumatoid arthritis and ankylosing spondylitis. These have a detrimental effect on the quality of life of the patient. The hip may be involved in 30 to 60 per cent of the cases (20), and total hip replacement is the only ultimate solution to improve pain and restore function in these young patients. Several studies have reported inferior results of total hip arthroplasty in this population. The higher failure rate has been attributed to the deficiencies of bone stock, the higher rate of polyethylene wear and therefore a higher rate of osteolysis, a higher rate of aseptic loosening, the intake of systemic medication and the younger age of the patients at the time of surgery, placing higher demands on the prostheses. Furthermore, there is also a higher risk of infection due to the disease itself. Traditionally, cemented total hip arthroplasty was considered the gold standard for patients with inflammatory disease, because of the inferior bone quality in these patients. Aseptic loosening of the acetabular component was the most frequent cause of failure, but loosening of the femoral component was also often seen. Chmell *et al* (8), in a study of 66 hips in 39 patients less than 30 years old, reported a failure rate of 44% of the acetabular components and 18% of the femoral components, with revision or radiographic loosening as the end point. Revision rate was 35% for the acetabular components and 18% for the femoral components. The 15 year survival rate was 70% for the acetabular implants and 85% for the femoral implants. Lehtimäki *et al* (27), in a study of 186 total hip replacements in 116 patients with a mean age of 31 years (range 14 to 67 years), reported an overall survival rate of 91.9% at 10 years and 83.0% at 15 years. The survival rate of the femoral components was 95.6% at 10 years and 91.9% at 15 years, while that of the acetabular components was 95.0% and 87.8% respectively. The use of steroids significantly impaired the survival in this

study. Because of the high failure rates of cemented implants, other surgeons have focused on the use of uncemented implants in patients with inflammatory disease. Initially, there was a concern that patients with inflammatory disease might not be good candidates for uncemented total hip replacement, because of the inferior bone quality and the use of systemic medication, which was believed to impair bone growth. Lachiewicz *et al* (25), in a study of 62 hips in 34 patients with juvenile and adult-onset rheumatoid arthritis, reported excellent clinical and radiographic results. Revision was performed in 2 hips (3.2%), one for aseptic loosening of the acetabular component and one for fracture of the femoral component. Eskelinen *et al* (16) reported a similar survival rate of press-fit porous-coated uncemented cups and all-poly cemented cups at 5 (98%) and 10 years (92%) postoperatively, but at 12 years the survival rate of the uncemented cups was 79% versus 86% for the cemented cups. Thus, the uncemented implants appeared to achieve good results, even in patients with deficient bone stock, such as in rheumatoid arthritis. Nevertheless, in recent literature, the results of cemented femoral implants, fixed with third generation cementing techniques, seem to be markedly better than those fixed with first generation cementing techniques. The results of cemented acetabular implants, however, remain poor. Sarmiento *et al* (38) in a study of 34 patients with rheumatoid arthritis less than 50 years and 74 patients older than 50 years, reported an overall survival rate of 82% in patients younger than 50 and 86% in patients older than 50 years at a mean follow-up of 7.7 years. This was mostly determined by the survival of the acetabular component, as the survival of the femoral component was almost 100%.

Another indication for total hip arthroplasty in young patients is avascular necrosis of the femoral head, which can be steroid induced, alcohol related, posttraumatic or idiopathic (14). Total hip replacement has been accepted as a valuable treatment for advanced stages of osteonecrosis, with collapse of the femoral head. Reports using first-generation cementing and cemented implants did not show good results. Saito *et al* (37), in a study of 29 total hip replacements in 23 patients with avascular

necrosis, reported unsatisfactory clinical results in 14 hips (48%), which all showed radiographical evidence of component loosening. Revision rate was 28% (8 hips), all for aseptic loosening. Ortiguera *et al* (33) compared the results of total hip replacement in patients with osteonecrosis and primary osteoarthritis (94 matched pairs) with a minimum follow-up of 10 years. Revision rate and mechanical failure rate were significantly higher in the osteonecrosis group younger than 50 years than in all the other groups. Among the patients older than 50 years, there was no significant difference between the osteonecrosis and osteoarthritis groups in revision rate or mechanical failure rate. Second-generation cementing techniques have improved the results of cemented total hip arthroplasty, as shown in the study of Kantor *et al* (21), who reported an overall revision rate of 12.5% at a mean follow-up of 7.5 years in 28 hips in 20 patients with non-traumatic avascular necrosis of the femoral head.

Because of the higher failure rate of cemented total hip arthroplasties in patients with avascular necrosis, more recent studies have focused on the use of cementless implants. Kim *et al* (24), in a study of 78 total hip arthroplasties in 61 patients with a mean age of 48 years (range 20 to 73 years) still reported a failure rate of 20.5%. The failure rate for the 7 total hip replacements performed in patients less than 30 years was 100% and that for the 11 prostheses in patients between 30 and 39 years old was 45.5%. Thus, age was an important prognostic factor in this study. Chiu *et al* (7) reported on 62 patients younger than 60 years old, of whom 29 with osteonecrosis (36 hips) and 33 with other diagnoses (36 hips). There were no statistical differences between the clinical and radiological results of the two groups, but patients with alcohol related avascular necrosis of the femoral head had less favorable results. Mont *et al* (31) compared the results of 52 total hip replacements in 41 patients with osteonecrosis to an equal number of total hip arthroplasties in 40 patients of the same age with osteoarthritis. At 50 months postoperatively, the survival rate was 96.1% in the osteonecrosis group and 98% in the osteoarthritis group. The excellent results in this study may be partially

attributed to the short duration of follow-up. Stulberg *et al* (40), in a study of 87 uncemented total hip replacements in 57 patients with osteonecrosis, reported an overall revision rate of 20.6%. Revision rate of the acetabular component was 16.1% and that of the femoral component was 8.0%. The average time to acetabular component failure was 7.6 years. There is still a lot of debate about the most optimal implants for this population. Kim *et al* (23) compared the results of third-generation cemented and second generation cementless total hip replacements in a prospective study including 148 hips in 98 patients. The mean follow-up was 9 years. The clinical results in both groups were excellent and there was no statistical difference between them. However, the mean age of their patients included was 47 years.

Many articles define young as being less than 50 years old at the time of surgery (9,13,22,28). In our review we only included patients younger than 35 years at the index arthroplasty (mean age 25.2 years). Acetabular component loosening was indeed the main cause of failure, but this was only seen in the cemented metal backed cups after 10 years. The survival of the cemented femoral components was 100%. Similar excellent survival of polished tapered stems have previously been reported in the literature (19,28). Clinical results in our group of patients are favourable. There was a significant improvement in pain, range of motion of both hips and function after surgery. This also considerably improved the quality of life of these patients. Sexual activity is a difficult subject to bring on, and only few studies have focused on this subject (11,18,26,30,39,43). Almost all patients stated that surgery had improved their sexual activity.

Finally, especially in young and healthy patients with bilateral symptomatic hip joint disease, bilateral total hip replacement performed in one stage is a valuable option. The potential advantages are obvious: a single anaesthesia, a shorter than cumulative hospital stay and therefore reduced costs and better functional recovery in patients with severe bilateral involvement. Nevertheless, concerns have been raised about the safety of such a procedure. Recent studies (4,34,35) show no statistical differences in postoperative complications

when comparing one-stage versus two-stage bilateral total hip replacements and show excellent clinical and radiographic results in both groups. This is confirmed in our study, as no major complications occurred. All our patients rehabilitated well and were able to walk when they went home. The mean duration of hospital stay in the single-stage bilateral group of patients was only slightly longer than that of a matched group of patients who received a unilateral total hip replacement.

A common finding in single-stage bilateral THA is an increased need for blood transfusions postoperatively. This can be reduced by the use of a cell saver intra-operatively. Although cell saving was not performed in all our patients, only one patient required blood transfusion.

In conclusion, this paper addresses three issues concerning THA in very young patients with a mean age of 25 : the use of a cemented polished femoral component, the use of cemented versus uncemented cups and the advantages of a single-staged bilateral THA. Cemented polished tapered stems have an excellent (100%) survival in very young individuals. Uncemented cups seem to perform better than their cemented opponents, a finding that is in accordance with the literature. Bilateral single-stage THA offers many advantages for young individuals without any major complications, even in those with an immune-compromised status.

REFERENCES

- Ballard WT, Callaghan JJ, Sullivan PM, Johnston RC.** The results of improved cementing techniques for total hip arthroplasty in patients less than fifty years old. A ten-year follow-up study. *J Bone Joint Surg* 1994 ; 76-A : 959-964.
- Barrack RL, Mulroy RD, Harris WH.** Improved cementing techniques and femoral component loosening in young patients with hip arthroplasty. A 12-year radiographic review. *J Bone Joint Surg* 1992 ; 74-B : 385-389.
- Berger RA, Jacobs JJ, Quigley LR, Rosenberg AG, Galante JO.** Primary cementless acetabular reconstruction in patients younger than 50 years old. 7- to 11 year results. *Clin Orthop* 1997 ; 344 : 2216-2226.
- Bhan S, Pankaj A, Malhotra R.** One- or two-stage bilateral total hip arthroplasty. A prospective, randomised, controlled study in an Asian population. *J Bone Joint Surg* 2006 ; 88-B : 298-303.
- Brooker AF, Bowerman JW, Robinson RA, Riley LH.** Ectopic ossification following total hip replacement. *J Bone Joint Surg* 1973 ; 55-A : 1629-1632.
- Charnley J.** The long-term results of low-friction arthroplasty of the hip performed as a primary intervention. *J Bone Joint Surg* 1972 ; 54-B : 61-76.
- Chiu KH, Shen WY, Ko CK, Chan KM.** Osteonecrosis of the femoral head treated with cementless total hip arthroplasty. A comparison with other diagnoses. *J Arthroplasty* 1997 ; 12 : 683-688.
- Chmell MJ, Scott RD, Thomas WH, Sledge CB.** Total hip arthroplasty with cement for juvenile rheumatoid arthritis. Results at a minimum of ten years in patients less than thirty years old. *J Bone Joint Surg* 1997 ; 79-A : 44-52.
- Collis DK.** Long-term (twelve to eighteen-year) follow-up of cemented total hip replacements in patients who were less than fifty years old. A follow-up note. *J Bone Joint Surg* 1991 ; 73-A : 593-597.
- Crowther JD, Lachiewicz PF.** Survival and polyethylene wear of porous-coated acetabular components in patients less than fifty years old : Results at nine to fourteen year. *J Bone Joint Surg*. 2002 ; 84-A : 729-735.
- Currey HL.** Osteoarthritis of the hip joint and sexual activity. *Ann Rheum Dis* 1970 ; 29 : 488-493.
- DeLee JG, Charnley J.** Radiological demarcation of cemented sockets in total hip replacement. *Clin Orthop* 1976 ; 121 : 20-32.
- Dorr LD, Kane TJ, Conaty JP.** Arthroplasty in patients 45 years old or younger. A 16-year follow-up study. *J Arthroplasty* 1994 ; 9 : 453-456.
- Dudkiewicz I, Covo A, Salai M et al.** Total hip arthroplasty after avascular necrosis of the femoral head : Does etiology affect the results ? *Arch Orthop Trauma Surg* 2004 ; 124 : 82-85.
- Duffy GP, Berry DJ, Rowland C, Cabanela ME.** Primary uncemented total hip arthroplasty in patients < 40 years old. 10- to 14-year results using first-generation proximally porous-coated implants. *J Arthroplasty* 2001 ; 16 : 140-144.
- Eskelinen A, Paavolainen P, Helenius I, Pulkkinen P, Remes V.** Total hip arthroplasty for rheumatoid arthritis in younger patients. 2,557 replacements in the Finnish Arthroplasty Register followed for 0-24 years. *Acta Orthop* 2006 ; 77 : 853-865.
- Gruen TA, McNeice GM, Amstutz HC.** "Modes of failure" of cemented stem-type femoral components. A radiographic analysis of loosening. *Clin Orthop* 1979 ; 141 : 17-27.
- Hill J, Bird H, Thorpe R.** Effects of rheumatoid arthritis on sexual activity and relationships. *Rheumatology* 2003 ; 42 : 280-286.
- Hook S, Moulder E, Yates PJ et al.** The Exeter Universal Stem. A minimum ten-year review from an independent centre. *J Bone Joint Surg* 2006 ; 88-B : 1584-1590.

20. **Joshi AB., Markovic L, Hardinge K, Murphy JC.** Total hip arthroplasty in ankylosing spondylitis : An analysis of 181 hips. *J Arthroplasty* 2002 ; 17 : 427-433.
21. **Kantor SG, Huo MH, Huk OL, Salvati EA.** Cemented total hip arthroplasty in patients with osteonecrosis : A 6-year minimum follow-up study of second-generation cementing techniques. *J Arthroplasty* 1996 ; 9 : 267-271.
22. **Kim YH, Kook HK, Kim JS.** Total hip replacement with a cementless acetabular component and a cemented femoral component in patients younger than fifty years of age. *J Bone Joint Surg* 2002 ; 84-A : 770-774.
23. **Kim YH, Oh SH, Kim JS.** Primary total hip arthroplasty with a second-generation cementless total hip prosthesis in patients younger than fifty years of age. *J Bone Joint Surg* 2003 ; 85-A : 109-114.
24. **Kim YH, Oh SH, Kim JS, Koo KH.** Contemporary total hip arthroplasty with and without cement in patients with osteonecrosis of the femoral head. *J Bone Joint Surg* 2003 ; 85-A : 675-681.
25. **Lachiewicz PF, McCaskill B, Inglis A, Ranawat CS, Rosenstein BD.** Total hip arthroplasty in juvenile rheumatoid arthritis. Two- to eleven-year results. *J Bone Joint Surg* 1986 ; 68-A : 502-508.
26. **Lafosse JM, Tricoire JL, Chiron P, Puget J.** Sexual function before and after primary total hip arthroplasty. *Joint Bone Spine* 2008 ; 75 : 189-194. Epub 2007 Aug 30.
27. **Lehtimäki MY, Lehto MUK, Kautiainen H, Savolainen HA, Hamalainen MM.J.** Survivorship of the Charnley total hip arthroplasty in juvenile chronic arthritis. A follow-up of 186 cases for 22 years. *J Bone Joint Surg* 1997 ; 79-B : 792-795.
28. **Lewthwaite S, Squires B, Gie G, Timperley A, Ling R.** The Exeter™ Universal Hip in patients 50 years or younger at 10-17 years' follow up. *Clin Orthop* 2008 ; 466 : 324-331.
29. **Merle d'Aubigné R, Postel M.** Functional results of hip arthroplasty with acrylic prosthesis. *J Bone Joint Surg* 1954 ; 36-A : 451-475.
30. **Meyer H, Stern R, Fusetti C et al.** Sexual quality-of-life after hip surgery. *J Orthopaed Traumatol* 2003 ; 4 : 21-25.
31. **Mont MA, Seyler TM, Plate J, Delanois R, Parvizi J.** Uncemented total hip arthroplasty in young patients with osteonecrosis of the femoral Head : A comparative study. *J Bone Joint Surg* 2006 ; 88-A : 104-109.
32. **Murray DW, Britton AR, Bulstrode CJK.** Loss to follow-up matters. *J Bone Joint Surg* 1997 ; 79-B : 254-257.
33. **Ortiguera DJ, Pulliam IT, Cabanela ME.** Total hip arthroplasty for osteonecrosis. Matched-pair analysis of 188 hips with long-term follow-up. *J Arthroplasty* 1999 ; 14 : 21-28.
34. **Parvizi J, Pour AE, Peak EL et al.** One-stage bilateral total hip arthroplasty compared with unilateral total hip arthroplasty. A prospective study. *J Arthroplasty* 2006 ; 21 : 26-31.
35. **Parvizi J, Tarity TD, Sheikh E et al.** Bilateral total hip arthroplasty. One-stage versus two-stage procedures. *Clin Orthop* 2006 ; 453 : 137-141.
36. **Restrepo C, Lettich T, Roberts N, Parvizi J, Hozack WJ.** Uncemented total hip arthroplasty in patients less than twenty-years. *Acta Orthop Belg* 2008 ; 74 : 615-622.
37. **Saito S, Saito M, Nishina T, Ohzono K, Ono K.** Long-term results of total hip arthroplasty for osteonecrosis of the femoral head. A comparison with osteoarthritis. *Clin Orthop* 1989 ; 244 : 198-207.
38. **Sarmiento A, Ebramzadeh E, Cogan WJ, McKellop HA.** Total hip arthroplasty with Cement. A long-term radiographic analysis in patients who are older than fifty and younger than fifty years. *J Bone Joint Surg* 1990 ; 72-A : 1470-1476.
39. **Stern SH, Fuchs MD, Ganz SB et al.** Sexual function after total hip arthroplasty. *Clin Orthop* 1991 ; 269 : 228-235.
40. **Stulberg BN, Singer R, Goldner J, Stulberg J.** Uncemented total hip arthroplasty in osteonecrosis. A 2- to 10-year evaluation. *Clin Orthop* 1997 ; 334 : 116-123.
41. **Thanner J, Kärrholm J, Herberts P, Malchau H.** Hydroxyapatite and tricalcium phosphate coated cups with and without screw fixation. A randomized study of 64 hips. *J Arthroplasty* 2000 ; 15 : 405-412.
42. **Torchia ME, Klassen RA, Bianco AJ.** Total hip arthroplasty with cement in patients less than twenty years old. *J Bone Joint Surg* 1996 ; 78-A : 995-1003.
43. **van Berlo WTM, van de Wiel HBM, Taal E et al.** Sexual functioning of people with rheumatoid arthritis : A multicenter study. *Clin Rheumatol* 2007 ; 26 : 30-38.