



## Treatment of acute and chronic elbow instability with a hinged external fixator after fracture dislocation

Christoph ZILKENS, Markus GRAF, Alexandros ANASTASIADIS, Samir SMAJIC, Gert MUHR, Thomas KÄLICKE

*From BG University Hospital Trauma Center "Bergmannsheil", Bochum Germany*

**This is a retrospective analysis of the clinical and radiological outcome in 24 patients with acute or chronic posttraumatic elbow instability, who were treated with open reduction, internal fixation and a hinged external fixator. The instability was acute after elbow fracture dislocation in 11 cases ; the other 13 had chronic posttraumatic instability of the elbow. Concentric stability and a sufficient range of motion of the elbow joint were achieved in all cases. The addition of a hinged external fixator in non-compliant patients, who underwent open reduction and internal fixation of an acute or chronic post-traumatic unstable elbow, allows early intensive mobilisation and can improve the clinical outcome after these complex elbow injuries.**

**Keywords :** elbow ; trauma ; instability ; hinged external fixator ; fracture dislocation.

### INTRODUCTION

Dislocation of the elbow is the second most frequent joint dislocation in adults, next to shoulder dislocation. In most cases the mechanism is a hyperextension injury following a fall on the outstretched arm, a motor vehicle accident or a direct trauma. The resulting dislocation is dorsal or dorso-radial in 80-90% of cases (15,31). There is in all cases an associated injury of the capsular and ligamentous structures, and an additional bony injury is present in about 50% of dislocations. Concomitant radial head and coronoid process fractures are of

particular importance for joint stability (8,18). Up to 70 % of patients suffer severe restriction of range of motion after fracture dislocation of the elbow. The risk of persistent instability and osteoarthritis increases significantly with the severity of the concomitant bony injury (4,15).

In contrast to simple dislocation without bony injury, which usually does not require surgery, the aim of treatment after elbow fracture dislocation is early open reduction, internal fixation and restoration of stability including reconstruction of capsular and ligamentous structures, to allow early mobilisation (15,18,24,28,31).

- 
- Christoph Zilkens, MD, Orthopaedic surgeon.
  - Markus Graf, MD, Orthopaedic surgeon.
  - Alexander Anastasiadis, MD, Orthopaedic surgeon.
  - Samir Smajic, MD, Orthopaedic surgeon.
  - Gert Muhr, MD, PhD, Professor and Head of the Department.
  - Thomas Kälicke, MD/PhD, Orthopaedic surgeon.
- Department of Surgery and Orthopaedic Surgery, BG University Hospital Trauma Center "Bergmannsheil", Bochum, Germany.*
- Correspondence : Christoph Zilkens, MD, BG University Hospital "Bergmannsheil", Department of Surgery and Orthopaedic Surgery, Bürkle-de-la-Camp-Platz 1, 44789 Bochum, Germany. E-mail : christoph@zilkens.net
- © 2009, Acta Orthopædica Belgica.
-

The duration of postoperative immobilisation with a cast, brace or external fixation device is determined by the clinical stability of the joint. Prolonged splinting jeopardizes early rehabilitation and recovery of joint function.

Chronic unreduced dislocation and recurrent instability of the elbow complicate fracture dislocation in up to 16% of patients and often require the use of a hinged external fixator to hold the elbow in a reduced position (1,5,27,29, 32-34,36,40,45,50,54,59).

The combination of stable reduction of the joint and possibility of concentric (isometric) early functional mobilisation is achieved using different types of external fixation devices offering controlled hinged motion (2,7,11-13,16,19,20,22,23,25,35,39,42-44,46,47,51-53,55,56).

Indisputably, stable reduction following open reduction and internal fixation can be achieved in some cases without the use of an external fixator, even after complex injuries of the elbow (3,6,9,10,17,18,21,26,30,31,41,57,58). However, in non-compliant patients and in those who are likely to be non-compliant after surgery, it may be necessary to secure the operative result with an external fixator.

In the present study we have assessed the clinical and radiological outcome of treatment of acute and chronic instability of the elbow after fracture dislocation with use of the Orthofix® (Orthofix, Verona, Italy) external fixator.

## PATIENTS AND METHODS

We retrospectively analyzed from the record notes, the clinical and radiographic results of 24 patients (12 female, 12 male), who were treated at our institution with a hinged external Orthofix®-fixator following open reduction and internal fixation, within the past four years.

The device was applied during reduction and stabilisation surgery. In the acute fracture dislocations however the application was delayed 9 to 19 days in 4 patients (N°. 1/A, 5/A, 6/A and 11/A) because the compliance of the patient was not correctly evaluated at the time of surgery. In two patients with chronic elbow instability, an Orthofix® external fixator was applied primarily because of insufficient restoration of capsular stability. Here, the fixator was not used as a motion

fixator but was locked. These two patients were excluded from the study group.

The average age was 55 years  $\pm$  15.3 (range, 27.1 to 82.6 years). Acute instability due to fracture dislocation was present in 11 patients; 13 patients were transferred to our institution for chronic elbow instability 5.2 months  $\pm$  3.8 (range, 1.2-14.3 months) after their index trauma and had an average of 2.4 (1 to 4) prior surgeries on the elbow. Patient outcome at the latest follow-up visit was assessed clinically in terms of stability and range of motion.

The score of Jäger and Wirth (14) was used to classify stiffness: grade I, *minor stiffness*:  $> 90^\circ$  extension/flexion mobility, grade II, *moderate stiffness*:  $60-90^\circ$ , grade III, *severe stiffness*:  $30-60^\circ$ , grade IV, *very severe stiffness*:  $< 30^\circ$ .

All surgical procedures were carried out under general or regional anaesthesia. After joint reduction and fracture reposition the capsulo-ligamentous structures were reconstructed. The application technique of the Orthofix® external fixator is described in detail elsewhere (37,51). A K-wire was drilled from lateral to medial through the centre of rotation of the elbow joint. This centre of rotation was identified using fluoroscopy as the circle produced when the lateral and medial epicondyles overlapped on a true lateral view of the elbow. When the K-wire was following the centre of rotation, it appeared as a dot in the middle of the condyles. The wire was advanced into the medial epicondyle without penetrating the medial cortex. The fixator was then attached to the wire and the proximal pins were placed, guided by the proximal jaws of the fixator. A mini open approach on the lateral aspect of the humerus allowed visualisation of the radial nerve. Placement of the distal, ulnar pins was again guided by the distal jaws in maximal flexion of the elbow joint in order to keep the fracture reduced. The K-wire was then removed. A dynamic check of the joint congruency was done under fluoroscopy.

In order to prevent heterotopic ossification, patients were given indomethacin 25 mg twice a day for two weeks.

## Statistical analysis

Student's t-test was used to determine the significance of differences between groups. Correlations between two continuous variables were assessed using Pearson's linear regression. A p-value less than 0.05 was considered a statistically significant result. All statistical analysis was performed using SPSS software package (version 12.0, SPSS Inc., Chicago, IL).

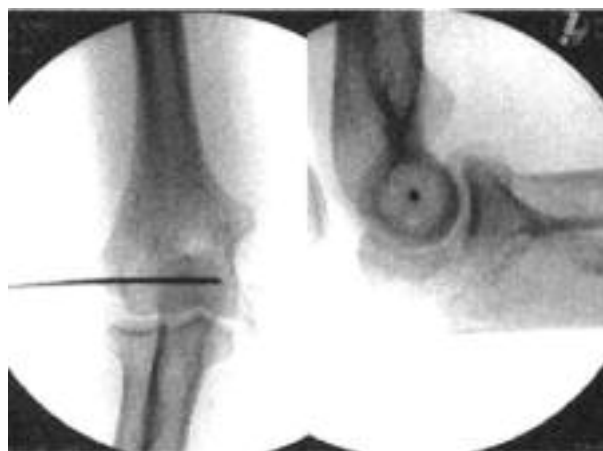## RESULTS

The average time in external fixation was 7.0 weeks  $\pm$  3.0 (range, 1.1-16.1 weeks). Within the follow-up period of 10.6 months  $\pm$  6.9 (range, 2.9-27.7 months) the final extension deficit of the elbow joint averaged  $27^\circ \pm 11$  (range, 0-40 $^\circ$ ), flexion averaged  $112^\circ \pm 13$  (range, 80-130 $^\circ$ ), pronation  $61^\circ \pm 20$  (range, 30-90 $^\circ$ ) and supination  $61^\circ \pm 24$  (range, 5-90 $^\circ$ ). In every patient, a concentric and stable elbow joint could be restored.

Table I and II show the results for the groups with acute and chronic instability in detail. The time in external fixation and the rate of complications were significantly higher in the group with chronic instability than in the group with acute instability ( $p < 0.001$ ). There was a statistically significant difference in the final range of motion between the groups: in the group with acute instability, 5 patients achieved Jäger/Wirth Grade I *minor stiffness*, whereas in the group with chronic instability, only one patient achieved Jäger/Wirth Grade I *minor stiffness* ( $p < 0.001$ ). No patient was graded Jäger/Wirth Grade III or IV. In all but two patients there was an extension-deficit of 20-40 $^\circ$ . In the group with acute instability the external fixator was applied 5.5 days  $\pm$  5.8 after injury (range, 0-19 days); in the group with chronic instability, it was applied 5.2 months  $\pm$  3.8 (range, 1.2-14.3 months) after the index injury.

A radial head prosthesis was implanted in one patient with acute instability (patient No. 5/A) and in 3 patients with chronic instability (patients No. 6/C, 11/C, 13/C). Three patients with chronic instability presented with a posttraumatic chronic infection, which was successfully treated with open debridement and antibiotic treatment.

In the group with acute instability, soft tissue damage caused the early removal of the fixator (patient No. 9/A) and in the group with chronic instability we had two cases of pin tract infection (patients No. 4/C and 12/C), one pin breakage (patient No. 8/C) and one breakage of an axis element of the fixator (patient No. 2/C) leading to repeat surgery. Four patients had pre-existing nerve damage (patients No. 1/C, 4/C, 7/C, 10/C); no further nerve compromise related to the application of



**Fig. 1.** — The transfixing 2 mm Kirschner wire is supposed to appear as a dot in the centre of the condyles in the lateral fluoroscopic view.

the fixator was noted. None of the pre-existing nerve damages recovered completely during the follow-up period.

Figure 2 shows the clinical picture of the immediate postoperative course of an open fracture dislocation in patient No. 8/A. Figure 3 is an example of chronic instability and pseudoarthrosis after fracture dislocation; figure 4 shows the favourable clinical and radiological outcome of the same patient 30 months after last surgery (patient No. 5/C).

## DISCUSSION

In the hands of the experienced surgeon, even complex fracture dislocations of the elbow or their sequelae can be reconstructed and can eventually achieve a good clinical outcome (15,18,24,28,31). Reconstruction of the radial head, coronoid process and capsulo-ligamentous structures is of paramount importance (18). Another important factor, frequently underestimated, for a favourable clinical outcome is the *patient-factor*: If the patient does not cooperate postoperatively, even a good surgical result with anatomic reduction and reconstruction of the joint will lead to an unfavourable clinical result. In our institution an external fixator is applied primarily, not to achieve stability, but to protect the internal fixation and maintain concentric

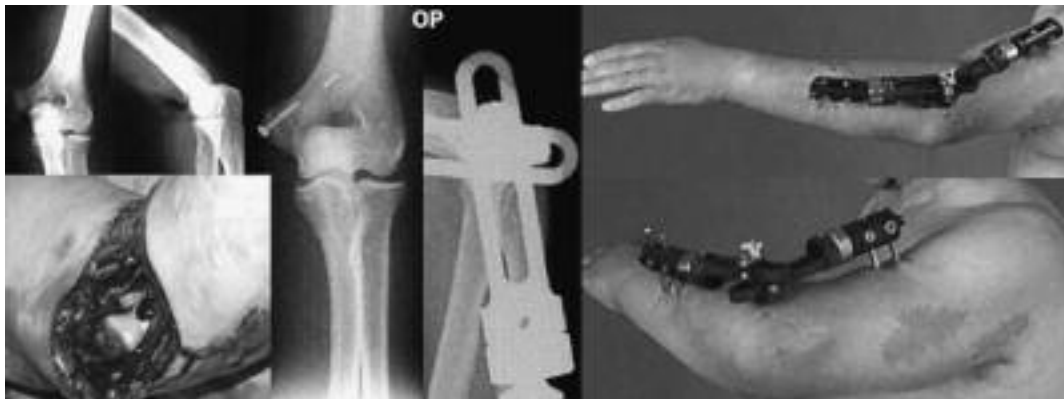Table I. — Acute elbow instability

Case (No)	sex	Age (y)	Diagnosis	Therapy	Time in fixex (weeks)	Follow-up (months)	Extension deficit (°)	Flexion (°)	Stiffness (°)	Pronation (°)	Supination (°)	Complications
1	f	59.8	Disloc-#, avulsion CP, RH #	ORIF, rec. CP, fixex	7.1	5.4	20	130	I	90	40	
2	f	55.2	Disloc-#, divulsion EU	ORIF, rep. CL, fixex	8.0	5.0	0	130	I	90	90	
3	f	51.7	Disloc-#, avulsion CP, RH #	ORIF, rec. CP, rep. CL, fixex	5.4	12.8	25	120	I	90	80	
4	m	58.8	Disloc-#, avulsion CP, RH #, Olecr. #	ORIF, rec. CP, rep. CL, fixex	3.9	25.6	30	100	II	40	30	
5	m	48.5	Disloc-#, avulsion CP, RH #	ORIF, prosthesis RH, rep. CL, fixex	4.6	3.1	40	120	II	60	40	
6	m	30.7	Disloc-#, avulsion CP, RH #	ORIF, rec. CP, rep. CL, fixex	11.1	10.2	30	90	II	50	5	
7	m	40.9	Disloc-#	ORIF, rep. CL, fixex	7.6	9.9	40	110	II	60	60	
8	m	68.1	Disloc-#, III° open	ORIF, rep. CL, fixex	3.9	5.2	15	120	I	80	80	
9	f	80.8	Disloc-#, avulsion CP, RH #	ORIF, rec. CP, rep. CL, fixex	1.1	13.0	30	100	II	40	40	Soft-tissue, early removal
10	f	69.3	Disloc-#, avulsion CP	ORIF, rec. CP, rep. CL, fixex	6.6	8.1	30	110	II	90	90	
11	m	44.9	Disloc-#	ORIF, rep. LCL, fixex	4.9	7.6	0	95	II	50	60	
					<b>55.3</b>	<b>9.4</b>	<b>24</b>	<b>112</b>	<b>1.45*</b>	<b>64</b>	<b>53</b>	

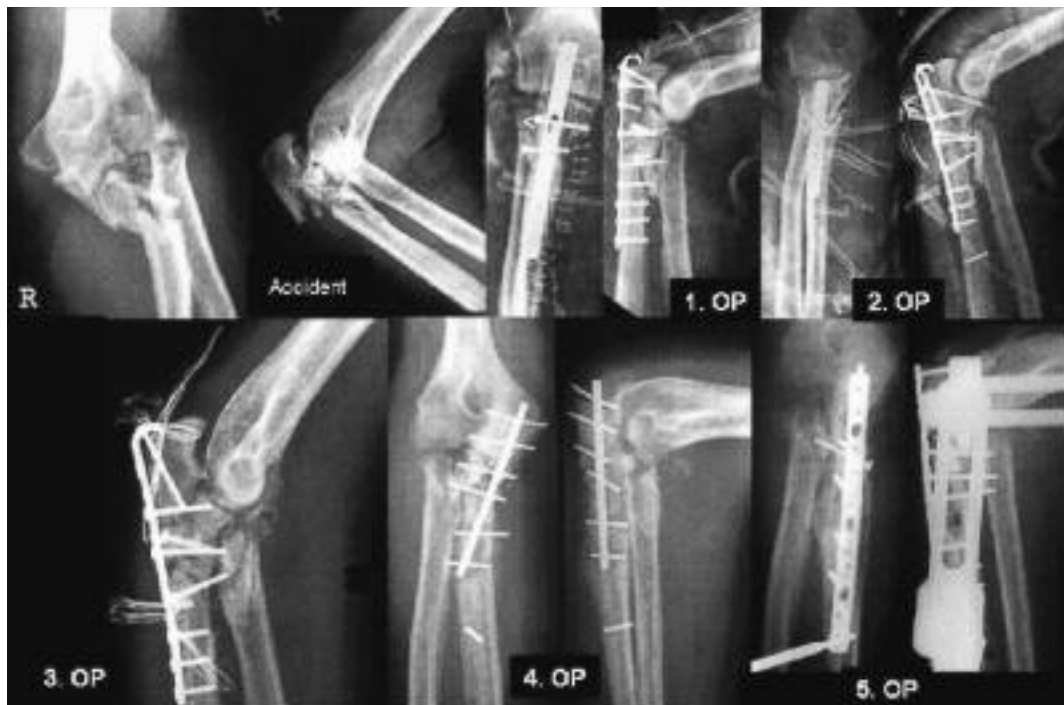**Disloc-#** -fracture-dislocation, **fixex**-external fixator, **RH**-radial head, **CP**-coronoid process, **EU**-Epicondylus Ulnaris, **Par**- paralysis, **Inf**-infection, **N.U.** - ulnar nerve, **N.R.** - radial nerve, \* - p<0.001; **ORIF** : open reposition internal fixation of the fracture ; **CL** : medial/lateral collateral ligament complex ; **rec.**-reconstruction ; **rep.**-repair ; **Deb.**-debridement, **AE**-axis element of fixator.

Table II. — Chronic elbow instability

Case (No)	sex	Age (y)	Diagnosis	Therapy	surgeries before fixex	Time in fixex (weeks)	Follow-up (months)	Ext.-deficit (°)	Flexion (°)	Stiffness (°)	Pronation (°)	Supination (°)	Complications
1	m	41.6	Disloc-#, Inf., par. N.U.	Deb., ORIF, rec. CP, rep. CL, fixex	2	11.6	12.8	30	120	II	90	80	
2	m	46.8	Disloc-#	ORIF, rec. CP, rep. CL, fixex	2	8.0	2.9	30	110	II	30	70	Breakage of AE
3	f	82.6	Disloc-#, avulsion CP, RH #	ORIF, rec. CP, rep. CL, fixex	3	5.0	14.2	30	120	II	60	90	
4	f	73.5	Disloc-#, Inf.	Deb., ORIF, fixex	2	16.1	8.7	30	100	II	60	60	Pin tract infection
5	m	42.2	Disloc-#, pseudarthrosis	ORIF, rep. CL, fixex	4	12.3	21.1	40	120	II	60	60	
6	m	27.1	Disloc-#, Inf.	Deb., ORIF, prosthesis, fixex	1	6.4	29.7	30	110	II	40	10	
7	f	53.7	Disloc-#, Inf.	Deb., ORIF, fixex	4	6.7	8.1	30	110	II	90	90	
8	f	73.4	Disloc-#	ORIF, rep. CL, fixex	2	8.9	7.3	40	100	II	60	60	
9	f	63.4	Disloc-#	ORIF, rep. CL, fixex	3	4.6	7.9	20	110	II	80	80	Breakage of pin
10	m	68.3	Disloc-#, Inf., par. N.U. + N.R.	Deb., ORIF, fixex	2	4.3	5.6	30	100	II	30	40	
11	m	34.6	Disloc-#	ORIF, prosthesis, fixex	2	6.3	18.5	20	110	II	40	60	
12	f	48.5	Disloc-#	ORIF, rep. CL, fixex	1	6.0	7.9	30	130	I	40	80	Pin tract infection
13	f	58.6	Disloc-#	ORIF, prosthesis, fixex	3	6.7	6.9	30	120	II	80	90	
					<b>2.4</b>	<b>7.6*</b>	<b>11.6</b>	<b>30</b>	<b>112</b>	<b>1.92*</b>	<b>56</b>	<b>66</b>	



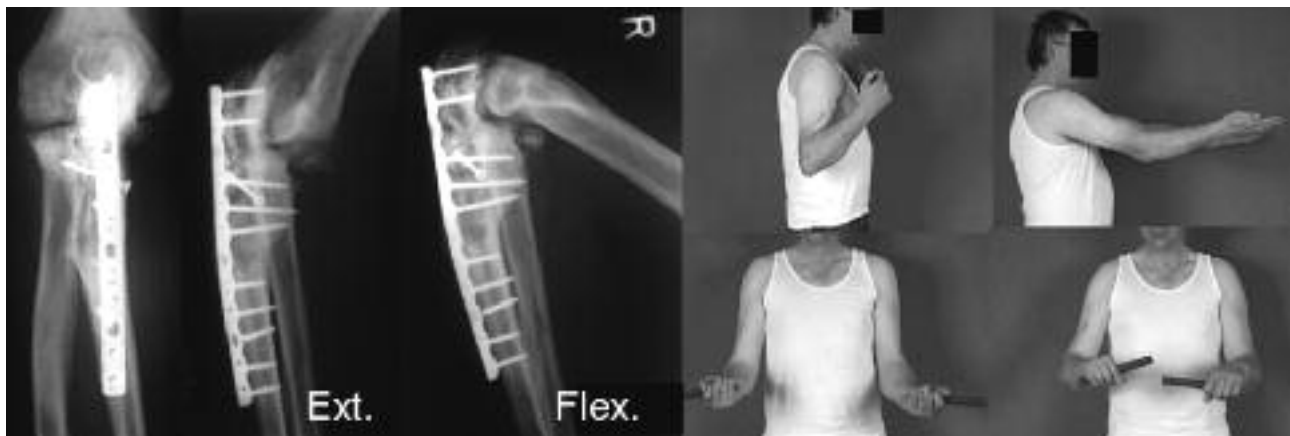
**Fig. 2.** — Open fracture-dislocation (patient No. 8/A). Post-reduction radiographs, clinical picture and picture after application of the external fixator.



**Fig. 3.** — Radiographic course of patient No. 5/C, who presented with chronic instability and pseudarthrosis after fracture-dislocation of the elbow.

reduction during the early postoperative physical therapy. The fixator is applied if the patient has proved to be non-cooperative or if the surgeon is unsure about the future patient's compliance. In our group of patients with chronic unstable elbow joints, the clinical behaviour of the patients was

known since the average time elapsed after fracture dislocation was 5.2 months and the patients had undergone an average of 2.4 surgeries. The surgeon rated each patient as not compliant or not able or not willing to cooperate postoperatively for various reasons such as alcoholism, drug abuse, mental



**Fig. 4.** — Radiographic and clinical outcome of patient No. 5/C, 30 months after last surgery

defects, cerebral trauma or senile dementia. This evaluation remains of course largely subjective. In the group of patients with acute instability after trauma, decision making was not so easy because in most of the cases, the patient was not known preoperatively. As a result, application of an external fixator was deemed necessary after a delay of 9 to 19 days after initial surgery in four patients.

The Orthofix® elbow external fixator must respect the normal ulnohumeral kinematics of a hinge joint. If the normal rotational axis is reconstructed, concentric ulnohumeral motion is possible while the periarticular soft tissues are protected against strain which would compromise correct healing. Favourable short and intermediate-term clinical results have been reported for the treatment of complex elbow injuries with different hinged elbow fixators (11,37,38,46,47,51,56). Recent publications indicate the growing interest in and use of external fixation devices for the postoperative treatment of complex elbow injuries with moderate and good short- and intermediate-term results (11,16,44,47-49,51,53,56).

We wish to warn, however, against uncritical application of this device. The correct application of the external fixator is technically demanding. In order to reduce frictional resistance and to avoid loosening, the axis pin has to be placed correctly at the centre of rotation. A deviation of only 5° from the centre results in a 3.7 fold increase in kinetic energy, and a deviation of 10° in a 7.1 fold

increase (23). In a kinematic study of 8 elbow preparations, made unstable after ligament section, Stavlas *et al* concluded that the Orthofix® external fixator efficiently stabilised the unstable elbow joint, but at the expense of changes in the physiologic motion pattern (52). This underlines the need for a correct placement of the device.

This study has some major shortcomings. It was conducted retrospectively using the record notes made at the occasion of routine follow-up-examinations. We also realise that the lack of a functional outcome score such as a Dash score is a deficiency of the study. However, we believe to have demonstrated that concentric stability of the elbow joint and a satisfactory overall clinical and radiological outcome can be achieved in every patient. No patient had to be re-operated on due to recurrent instability. No severe elbow stiffness (Grade III-IV) was recognised at the latest follow-up (14). With Stavlas *et al* we share the finding that most (22 out of 24) of our patients were unable to achieve the final degrees of extension. This might be partially due to the design of the fixator (51). In 4 patients (16.6%) fixator-associated complications were observed, leading to further surgery. In one case, the fixator had to be removed after one week, because of the soft-tissue status. Due to these relatively frequently associated complications, we warn against the uncritical use of the external fixator. In compliant patients with a complex acute or chronic

instability, the joint stability achieved after open reduction and internal fixation is sufficient to allow early functional mobilisation of the joint and to achieve a favourable clinical result.

## REFERENCES

1. **Ball CM, Galatz LM, Yamaguchi K.** Elbow instability : treatment strategies and emerging concepts. *Instr Course Lect* 2002 ; 51 : 53-61.
2. **Bottlang M, O'Rourke MR, Madey SM et al.** Radiographic determinants of the elbow rotation axis : experimental identification and quantitative validation. *J Orthop Res* 2000 ; 18 : 821-828.
3. **Breitfuss H, Muhr G, Neumann K et al.** [Arthrolysis of post-traumatic stiff elbow. Which factors influence the end result ?] (in German). *Unfallchirurg* 1991 ; 94 : 33-39.
4. **Broberg MA, Morrey BF.** Results of treatment of fracture-dislocations of the elbow. *Clin Orthop* 1987 ; 216 : 109-119.
5. **Chapman CB, Su BW, Sinicropi SM et al.** Vitallium radial head prosthesis for acute and chronic elbow fractures and fracture-dislocations involving the radial head. *J Shoulder Elbow Surg* 2006 ; 15 : 463-473.
6. **Eberl R, Kaminski A, Reckwitz N et al.** [The tele-visit as a telemedical technique in daily clinical practice. First results for elbow joint arthrolysis.] (in German). *Unfallchirurg* 2006 ; 109 : 383-390.
7. **Haasper C, Jagodzinski M, Krettek C, Zeichen J.** Hinged external fixation and closed reduction for distal humerus fracture. *Arch Orthop Trauma Surg* 2006 ; 126 : 188-191.
8. **Habermeyer P.** [Conservative treatment of elbow dislocations] (in German) *Orthopäde* 1988 ; 17 : 313-319.
9. **Hahn MP, Ostermann PA, Richter D, Muhr G.** [Elbow arthrodesis and its alternative.] (in German). *Orthopäde* 1996 ; 25 : 112-120.
10. **Hahn MP, Richter D, Ostermann PA, Muhr G.** [Injury pattern after fall from great height. An analysis of 101 cases.] (in German). *Unfallchirurg* 1995 ; 98 : 609-613.
11. **Hall J, Schemitsch EH, McKee MD.** Use of a hinged external fixator for elbow instability after severe distal humeral fracture. *J Orthop Trauma* 2000 ; 14 : 442-445.
12. **Hausman MR, Birnbaum PS.** Interposition elbow arthroplasty. *Tech Hand Up Extrem Surg* 2004 ; 8 : 181-188.
13. **Hildebrand KA, Patterson SD, King GJ.** Acute elbow dislocations : simple and complex. *Orthop Clin North Am* 1999 ; 30 : 63-79.
14. **Fuchs S, Wallstabe S, Gerlach U et al.** [Secondary intervention after elbow trauma.] (in German). *Trauma Berufskrankh* 2007 ; 9 : 202-209.
15. **Josefsson PO, Gentz CF, Johnell O, Wendeberg B.** Surgical versus nonsurgical treatment of ligamentous injuries following dislocations of the elbow joint. *Clin Orthop* 1987 ; 214 : 165-169.
16. **Jupiter JB, Ring D.** Treatment of unreduced elbow dislocations with hinged external fixation. *J Bone Joint Surg* 2002 ; 84-A : 1630-1635.
17. **Kalicke T, Muhr G, Frangen TM.** Dislocation of the elbow with fractures of the coronoid process and radial head. *Arch Orthop Trauma Surg* 2007 ; 127 : 925-931.
18. **Kalicke T, Westhoff J, Wingenfeld C et al.** [Fracture dislocation of the elbow involving the coronoid process.] (in German). *Unfallchirurg* 2003 ; 106 : 300-305.
19. **Kesmezacar H, Ogut T, Yucel I et al.** [Defective forearm pseudoarthrosis with a neglected elbow dislocation.] (in Turkish). *Ulus Travma Acil Cerrahi Derg* 2003 ; 9 : 218-221.
20. **Koslowsky TC, Mader K, Siedek M, Pennig D.** Treatment of bilateral elbow dislocation using external fixation with motion capacity : a report of 2 cases. *J Orthop Trauma* 2006 ; 20 : 499-502.
21. **Lahoda LU, Klapperich T, Hahn MP, Muhr G.** [Results of posttraumatic elbow arthrolyses : a prospective study.] (in German). *Chirurg* 1999 ; 70 : 1302-1306
22. **Lerner A, Stein H, Calif E.** Unilateral hinged external fixation frame for elbow compression arthrodesis : the stepwise attainment of a stable 90-degree flexion position : a case report. *J Orthop Trauma* 2005 ; 19 : 52-55.
23. **Madey SM, Bottlang M, Steyers CM et al.** Hinged external fixation of the elbow : optimal axis alignment to minimize motion resistance. *J Orthop Trauma* 2000 ; 14 : 41-47.
24. **McKee MD, Jupiter JB.** A contemporary approach to the management of complex fractures of the distal humerus and their sequelae. *Hand Clin* 1994 ; 10 : 479-494.
25. **McKee MD, Pugh DM, Wild LM et al.** Standard surgical protocol to treat elbow dislocations with radial head and coronoid fractures. Surgical technique. *J Bone Joint Surg* 2005 ; 87-A Suppl 1 : 22-32.
26. **Meyer-Marcotty MV, Lahoda LU, Hahn MP, Muhr G.** [Differential therapy of radial head fracture : a critical analysis based on outcome of 53 patients] (in German). *Unfallchirurg* 2002 ; 105 : 532-539.
27. **Moritomo H, Tada K, Yoshida T, Kawatsu N.** Reconstruction of the coronoid for chronic dislocation of the elbow. Use of a graft from the olecranon in two cases. *J Bone Joint Surg* 1998 ; 80-B : 490-492.
28. **Morrey BF.** Complex instability of the elbow. *Instr Course Lect* 1998 ; 47 : 157-164.
29. **Morrey BF, An KN.** Articular and ligamentous contributions to the stability of the elbow joint. *Am J Sports Med* 1983 ; 11 : 315-319.
30. **Muhr G, Kayser M.** [The infected elbow joint fracture.] (in German). *Orthopäde* 1988 ; 17 : 279-286.
31. **Muhr G, Wernet E.** [Ligament injuries and dislocations of the elbow joint] (in German). *Orthopäde* 1989 ; 18 : 268-272.
32. **O'Driscoll SW.** Elbow instability. *Acta Orthop Belg* 1999 ; 65 : 404-415.

33. **O'Driscoll SW.** Elbow instability. *Hand Clin* 1994 ; 10 : 405-415.
34. **Pacelli LL, Guzman M, Botte MJ.** Elbow instability : the orthopedic approach. *Semin Musculoskelet Radiol* 2005 ; 9 : 56-66.
35. **Paksima N, Panchal A.** Elbow fracture-dislocations : the role of hinged external fixation. *Bull Hosp Jt Dis* 2004 ; 62 : 33-39.
36. **Papandrea RF, Morrey BF, O'Driscoll SW.** Reconstruction for persistent instability of the elbow after coronoid fracture-dislocation. *J Shoulder Elbow Surg* 2007 ; 16 : 68-77.
37. **Pennig D, Gausepohl T, Mader K.** Transarticular fixation with the capacity for motion in fracture dislocations of the elbow. *Injury* 2000 ; 31 Suppl 1 : 35-44.
38. **Pennig D, Gausepohl T, Mader K, Wolfgarten B.** [Distraction arthrolysis with humero-ulnar motion fixator.] (in German). *Orthopade* 2001 ; 30 : 635-644.
39. **Pugh DM, Wild LM, Schemitsch EH et al.** Standard surgical protocol to treat elbow dislocations with radial head and coronoid fractures. *J Bone Joint Surg* 2004 ; 86-A : 1122-1130
40. **Regan W, Lapner PC.** Prospective evaluation of two diagnostic apprehension signs for posterolateral instability of the elbow. *J Shoulder Elbow Surg* 2006 ; 15 : 344-346.
41. **Richter D, Hahn MP, Ostermann PA et al.** Vertical deceleration injuries : a comparative study of the injury patterns of 101 patients after accidental and intentional high falls. *Injury* 1996 ; 27 : 655-659.
42. **Ring D, Hannouche D, Jupiter JB.** Surgical treatment of persistent dislocation or subluxation of the ulnohumeral joint after fracture-dislocation of the elbow. *J Hand Surg* 2004 ; 29-A : 470-480.
43. **Ring D, Hotchkiss RN, Guss D, Jupiter JB.** Hinged elbow external fixation for severe elbow contracture. *J Bone Joint Surg* 2005 ; 87-A : 1293-1296.
44. **Ring D, Jupiter JB.** Compass hinge fixator for acute and chronic instability of the elbow. *Oper Orthop Traumatol* 2005 ; 17 : 143-157.
45. **Ring D, Jupiter JB.** Reconstruction of posttraumatic elbow instability. *Clin Orthop* 2000 ; 370 : 44-56.
46. **Ruch DS, Triepel CR.** Hinged elbow fixation for recurrent instability following fracture dislocation. *Injury* 2001 ; 32 Suppl 4 : SD 70-78.
47. **Schmickal T, Hoentzsch D, Wentzensen A.** [A hinged external fixator for treatment of complex elbow joint injuries.] (in German). *Unfallchirurg* 2007 ; 110 : 320-326.
48. **Schmickal T, Parekh A, Hoentzsch D et al.** Subtotal amputation injuries in the elbow region treated with a hinged external fixator. *Orthopedics* 2007 ; 30 : 432-438.
49. **Schmickal T, Wentzensen A.** [Treatment of complex elbow injuries by joint-spanning articulated fixator.] (in German). *Unfallchirurg* 2000 ; 103 : 191-196.
50. **Sheps DM, Hildebrand KA, Boorman RS.** Simple dislocations of the elbow : evaluation and treatment. *Hand Clin* 2004 ; 20 : 389-404.
51. **Stavlas P, Gliatis J, Polyzois V, Polyzois D.** Unilateral hinged external fixator of the elbow in complex elbow injuries. *Injury* 2004 ; 35 : 1158-1166.
52. **Stavlas P, Jensen SL, Sojbjerg JO.** Kinematics of the ligamentous unstable elbow joint after application of a hinged external fixation device : A cadaveric study. *J Shoulder Elbow Surg* 2007 ; 16 : 419-426.
53. **Tan V, Daluiski A, Capo J, Hotchkiss R.** Hinged elbow external fixators : indications and uses. *J Am Acad Orthop Surg* 2005 ; 13 : 503-514.
54. **Tashjian RZ, Katarincic JA.** Complex elbow instability. *J Am Acad Orthop Surg* 2006 ; 14 : 278-286.
55. **Ullmann Y, Fodor L, Soudry M, Lerner A.** The Ilizarov technique in joint contractures and dislocations. *Acta Orthop Belg* 2007 ; 73 : 77-82.
56. **von Knoch F, Marsh JL, Steyers C et al.** A new articulated elbow external fixation technique for difficult elbow trauma. *Iowa Orthop J* 2001 ; 21 : 13-19.
57. **Weber O, Burger C, Graf M et al.** [Bipolar dislocation injury of the forearm.] (in German). *Unfallchirurg* 2006 ; 109 : 600-604.
58. **Wick M, Lies A, Muller EJ, Hahn MP, Muhr G.** [Prostheses of the head of the radius. What outcome can be expected ?] (in German). *Unfallchirurg* 1998 ; 101 : 817-821.
59. **Zeier FG.** Recurrent traumatic elbow dislocation. *Clin Orthop* 1982 ; 169 : 211-214.