



## Bilateral combined fractures of the scaphoid and distal radius in a 13-year-old male

Lars Petter BJØRNSSEN

*From Lofoten Hospital, Gravdal, Norway*

**The scaphoid is the most common of the carpal bones to fracture ; upper limb fractures are associated in 5-10% of cases, and around 2% of the concomitant fractures are of the distal radius. One case of bilateral carpal scaphoid fractures associated with bilateral distal radius fractures is presented. Radiographs showed displaced Salter-Harris Type II radius fracture and nondisplaced transverse midscaphoid fracture on both sides. Conservative treatment with scaphoid casts on both arms was inconvenient for the patient, but gave complete union of the fractures and functionally, painless full range of motion.**

**Keywords :** radius ; scaphoid ; combined fracture ; wrist injury.

### INTRODUCTION

The scaphoid is the most common of the carpal bones to fracture (3,6). Upper limb fractures are associated in 5-10% of cases (5,9,13,22). Around 2% of the described concomitant fractures are of the distal radius (20,22) and this combination of fractures has been well described in adults (18). Scaphoid fractures, divided into fracture of distal pole, mid-waist, and proximal pole, have a peak incidence between the ages 15 and 30 years and are rare prior to the age of 15. Ossification of the scaphoid begins at 5 to 6 years and is not complete until 13 to 15 years of age. Because the scaphoid is largely cartilaginous in children, it is rarely injured (1). However, although carpal fractures in

children are rare, the scaphoid is the most frequently fractured carpal bone in children (12,14,15,21) accounting for 3 percent of the hand and wrist fractures in people younger than fifteen years.

Only a few cases with combined fracture of the distal radius and scaphoid have been reported in the literature (1,4,8,19,21). To the best of our knowledge, this is the first time a case of bilateral concomitant distal radius and carpal scaphoid fractures in a skeletally immature patient has been reported.

### CASE REPORT

Following a bicycle accident with a fall on outstretched hands, a 13-year-old boy was evaluated at

---

■ Lars Petter Bjørnsen, MD.

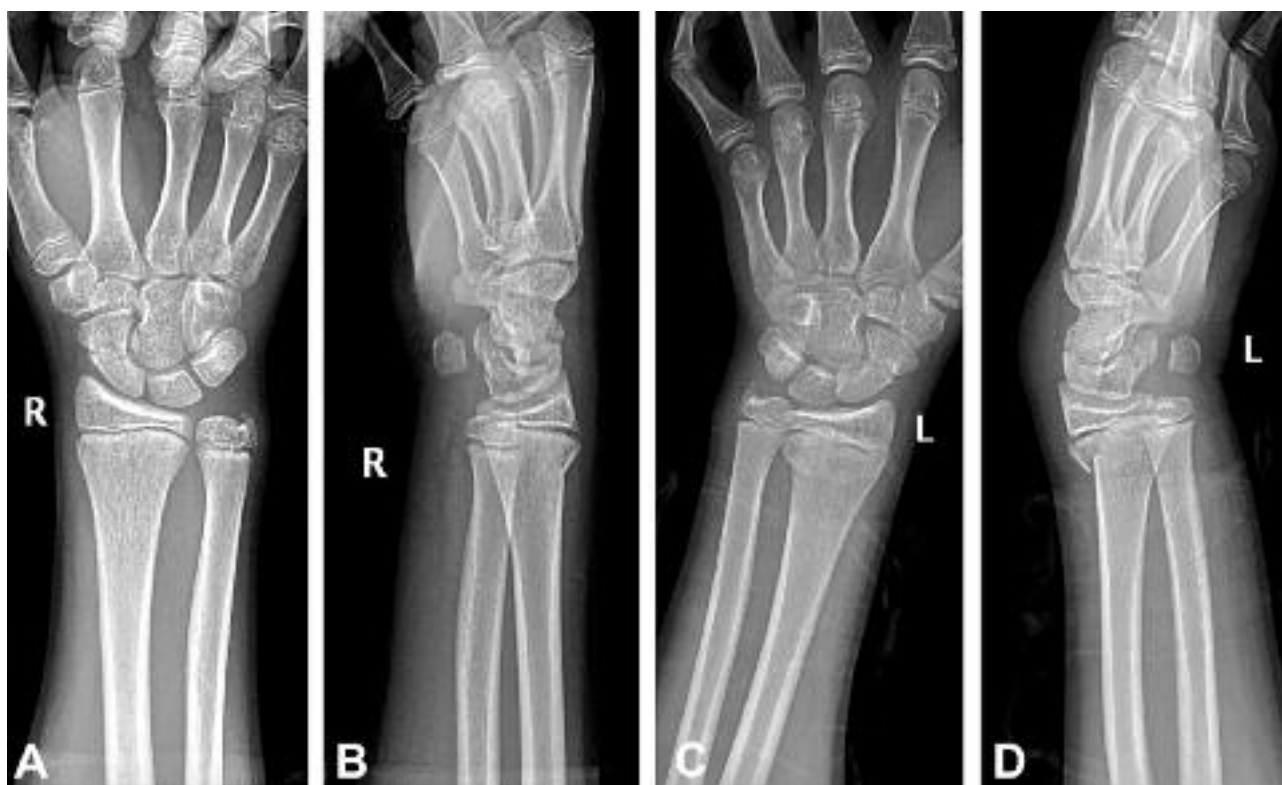Department of Surgery, Lofoten Hospital, Gravdal, Norway and Section of Emergency Medicine, Department of Medicine, University of Wisconsin Hospital & Clinics, USA.

Correspondence : Lars Petter Bjørnsen, MD, Section of Emergency Medicine, Department of Medicine, University of Wisconsin Hospital & Clinics, 600 Highland Avenue, Madison, WI 53792-3280, USA. E-mail : lbjoernsen@uwhealth.org

© 2008, Acta Orthopædica Belgica.

---

*No financial support of this research project occurred. The author has received nothing of value. This manuscript does not contain information about medical devices. The patient and his family were informed that data from the case would be submitted for publication, and gave their consent.*



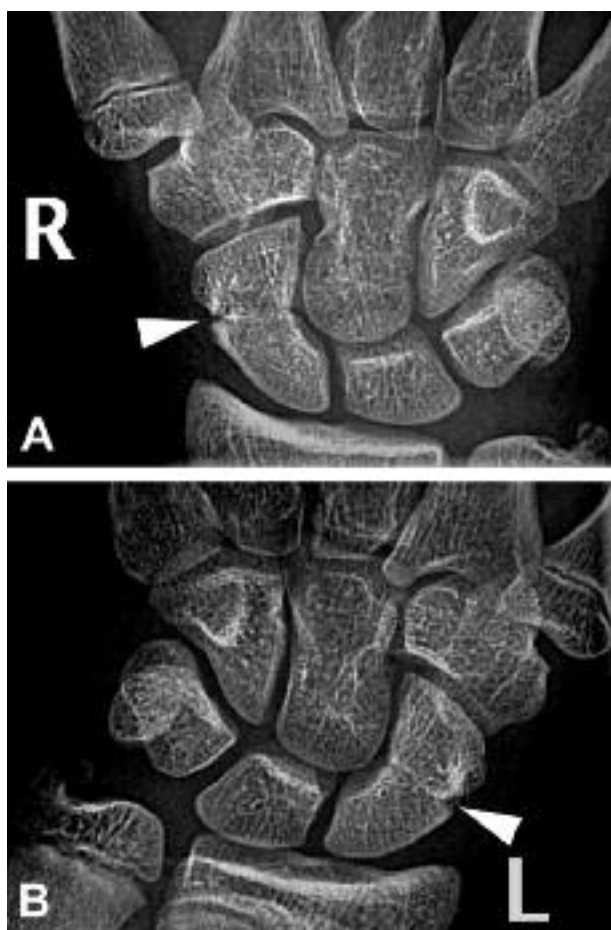
**Fig. 1.** — AP and lateral radiographs of the right (A, B) and left (C, D) wrist at the time of injury. A Salter-Harris type II fracture of the distal radius can be seen on both left and right side. The fracture of the left wrist is more dorsally displaced than on the right side. The midscaphoid bilateral fractures can also be seen (A, D).

our hospital. He complained of local pain and deformity of the distal end of the left forearm and pain in the right wrist. Clinical examination revealed swelling over the dorsal aspect of the left wrist and discoloration. The right wrist was less swollen, but there was a blue discoloration on the dorsal side. No obvious deformity was seen on the right forearm. Both wrists were tender to palpation and had decreased range of motion. The neurovascular status was normal. No other injuries were found. Anteroposterior and lateral radiographs of the wrists showed displaced Salter-Harris Type II fractures (11,16) on both sides (fig 1). The fracture of the left wrist was more dorsally displaced than on the right side. A nondisplaced transverse midscaphoid fracture was seen in both hands (fig 2). The fractures were in good position and were immobilized with a cast below the elbow including the thumb (scaphoid cast) on both arms for 6 weeks. The conservative treatment was inconven-

ient for the patient, but gave complete union of the fracture and functionally, painless full range of motion was obtained. The patient and his family were informed that data from the case would be submitted for publication, and gave their consent.

## DISCUSSION

Fractures of the carpal scaphoid associated with distal radius fracture are remarkably rare in skeletally immature subjects. Only a few cases have been reported in the literature (1,7,8,21), but now this type of combined fracture seems to be more and more frequently recognized (17). Waist scaphoid fractures, like in this case, are more common in adults than in children; however, scaphoid waist fracture are increasing in frequency as participation in contact athletics is occurring at a younger age (10). Even though fracture of the carpal scaphoid associated with fracture of the distal radius is a highly



**Fig. 2.** — AP radiographs of the carpal bones at the time of injury. A transverse midscaphoid fracture (arrowhead) was diagnosed on the right (A) and left (B) side. Both fractures healed uneventfully. No signs of scaphoid avascular necrosis were appreciated after 6 weeks. The patient regained full and painless motion.

unusual combination of injuries in skeletally immature patients, it is important to have a high index of suspicion for their association. A scaphoid fracture may have an associated injury in 12 percent of cases, involving either the radius, neighbouring carpal bones, a carpal instability pattern, or dislocation (11). The mechanism of injury is similar for both scaphoid and distal radial fracture and this should be kept in mind when the very common distal radius fracture is diagnosed. The diagnosis is made by a correlation of the clinical and radiographic findings. Examining the wrist in ulnar deviation exposes more of the scaphoid to direct

palpation in the anatomic snuffbox. Eliciting pain in this area when the patient resists supination or pronation of the hand, or pain with axial pressure directed along the thumb's metacarpal, is also suggestive of injury (11).

Scaphoid fractures are usually not as obvious as in this case and they are often not visible on initial radiographs. Standard and scaphoid views should be carefully examined for any cortical disruption. Standard anteroposterior and lateral views are usually adequate, but if a patient presents with pain at the radial side of the wrist, more specifically in the "anatomic snuffbox", a scaphoid view of the wrist should be added to the wrist series (2). This is a PA radiograph with the wrist extended 30° and deviated ulnarly 20°. This view helps to stretch out the scaphoid and is also used for assessing the degree of scaphoid fracture angulations.

The physician should be aware of structures in the scaphoid bone, like partial division, incomplete clefts, cysts, and trabecular pattern that might simulate a fracture (10). Incomplete ossification might further complicate radiological diagnosis. If no fracture is seen on initial x-ray examination but the patient has pain at the scaphoid, treatment should be as for nondisplaced scaphoid fracture with immobilization.

Nondisplaced fractures and those that are only clinically suspected can be treated in a short-arm thumb spica splint. Splinting in dorsiflexion and radial deviation helps to compress the fracture fragments. Radiographs out of plaster should be repeated in 7 to 10 days to ensure alignment and then monthly to union. If radiographs show no fracture and the pain has resolved, the cast can be left off. Persistent pain with normal radiographs requires continued immobilization and advanced imaging studies, such as bone scan, CT-scan, or MRI-scan (10).

A scaphoid fracture is considered unstable if it is oblique; if there is as little as 1 mm of displacement; if there is rotation or comminution; or if a carpal instability pattern is present. Patients with unstable fractures should be placed in a long-arm thumb spica splint and should be seen promptly by an orthopaedic surgeon for definitive treatment. All displaced fractures should be treated with open

reduction and internal fixation or with arthroscopic surgery.

Even with optimal cast treatment, some of these fractures will be complicated by delayed union, nonunion, or avascular necrosis. A scaphoid fracture can develop avascular necrosis of the proximal fracture segment that can lead to disabling arthritis (11). In general, the more proximal, oblique, or displaced the fracture, the greater the risk of developing avascular necrosis.

Distal radial fractures are common and the peak incidence is in the preadolescent growth spurt (10). Plain AP and lateral films are usually diagnostic of the fracture type and deformity. The Salter-Harris system (16) is the basis of classification of the distal radial physeal fractures, and most are, as in this case, Salter-Harris type II fractures. If the acute fracture is unrecognized, a late-appearing periosteal reaction may indicate the fracture. CT scans may be necessary to define the fracture pattern and degree of intra-articular displacement. Treatment options include no reduction, closed reduction and cast immobilization, closed reduction and pin fixation, and open reduction (10). Here the nondisplaced radius fractures were immobilized until appropriate healing and pain resolution had been achieved.

As a summary, the patient in this case was immobilized with a cast on both arms for six weeks, allowing uncomplicated healing of the fractures. Both scaphoid bones went on to complete union. The outcome was excellent, with full and painless range of motion of the wrist. We suggest that initial splinting may be done by the emergency physician, but, since complications can occur even with optimal treatment, close follow-up by an orthopaedic surgeon is recommended.

#### Acknowledgements

I would like to thank Benno Röper at the Department of Surgery and Jon Heger at the Department of Radiology, both at Lofoten Hospital, Norway, for support and guidance.

## REFERENCES

1. **Albert M, Barre PS.** A scaphoid fracture associated with a displaced distal radial fracture in a child. *Clin Orthop* 1989 ; 240 : 232-235.
2. **American College of Radiology.** Acute hand and wrist trauma. *Expert Panel on Musculoskeletal Imaging* 1998.
3. **Borgeskov S, Christiansen B, Kjaer A, Balslev I.** Fracture of the carpal bones. *Acta Orthop Scand* 1966 ; 37 : 277-287.
4. **Compson JP.** Trans-carpal injuries associated with distal radial fractures in children : a series of three cases. *J Hand Surg* 1992 ; 17-B : 311-314.
5. **Dickinson J, Shannon JG.** Fractures of the carpal scaphoid in the Canadian army. *Surg Gynaec Obst* 1944 ; 79 : 225-239.
6. **Dunn AW.** Fractures and dislocations of the carpus. *Surg Clin North Am* 1972 ; 52 : 1513-1538.
7. **Gamble J, Simmons SC.** Bilateral scaphoid fractures in a child. *Clin Orthop* 1982 ; 162 : 125-128.
8. **Hernán-Prado M, Laplaza FJ.** Distal radius epiphysiolysis associated with scaphoid fractures in immature patients : Report of two cases and review of literature. *J Orthop Trauma* 2001 ; 15 : 73-77.
9. **Hove LM.** Simultaneous scaphoid and distal radius fractures. *J Hand Surg* 1994 ; 19-B : 384-388.
10. **Kozin S.** Fractures and dislocations of the hand and carpus in children. In : Beaty JH, Kasser JR (Eds) *Rockwood and Wilkins' Fractures in Children*, Sixth Edition, Lippincott Williams & Wilkins, Philadelphia, 2001, pp 257-336.
11. **Krasin E, Goldwirth M, Gold A, Goodwin DR.** Review of the current methods in the diagnosis and treatment of scaphoid fractures. *Postgrad Med J* 2001 ; 77 : 235-237.
12. **Light TR.** Injury to the immature carpus. *Hand Clin* 1988 ; 4 : 415-424.
13. **Möller BN.** Simultaneous fracture of the carpal scaphoid and adjacent bones. *Hand* 1983 ; 15 : 258-261.
14. **Mussbichler H.** Injuries of the carpal scaphoid in children. *Acta Radiol* 1961 ; 56 : 110-115.
15. **Nafie SA.** Fractures of the carpal bones in children. *Injury* 1987 ; 18 : 117-119.
16. **Salter R.** Injuries involving the epiphyseal plate. *J Bone Joint Surg* 1963 ; 45-A : 587.
17. **Smida M, Nigrou K, Soohun T et al.** Combined fracture of the distal radius and scaphoid in children. Report of 2 cases. *Acta Orthop Belg.* 2003 ; 69 : 79-81.
18. **Stoother IG.** A report of three cases of simultaneous Colles' and scaphoid fractures. *Injury* 1976 ; 7 : 185-188.
19. **Tawil H, Daumas L, Zerkly B et al.** [Scaphoid fracture associated with displaced fracture of the distal end of the radius in children : a propos of a case.] (in French). *Rev Chir Orthop* 1995 ; 81 : 741-744.
20. **Tountas A, Waddell JP.** Simultaneous fracture of the distal radius and scaphoid. *J Orthop Trauma* 1988 ; 4 : 312-317.
21. **Vahvanen V, Westerlund M.** Fracture of the carpal scaphoid in children : a clinical and roentgenological study of 108 cases. *Acta Orthop Scand* 1980 ; 51 : 909-913.
22. **Wildin C, Bhowal B, Dias JJ.** The incidence of simultaneous fractures of the scaphoid and radial head. *J Hand Surg* 2001 ; 26 : 25-27.