



## Total hip arthroplasty following failure of dynamic hip screw fixation of fractures of the proximal femur

Akram HAMMAD, Ahmed ABDEL-AAL, Hatem G. SAID, Hatem BAKR

*From Mansoura and Assiut University Hospitals, Egypt*

Thirty-two patients (11 male, 21 female) with a mean age of 64 years were prospectively studied after undergoing total hip replacement after failed treatment of intertrochanteric fractures. One patient had bilateral surgery. The mean time from primary surgery to the salvage arthroplasty was 15 months (range, 4 to 32 months). The mean follow-up period was 57 months (range, 30 to 108 months).

Intraoperative femoral fracture occurred in one patient and postoperative dislocation in another. Three patients had deep venous thrombosis, two had gastrointestinal bleeding and one had a non fatal pulmonary embolism.

At the last follow-up, we were able to review 26 patients with 27 arthroplasties; the other 6 patients had died. The majority had good pain relief and marked functional improvement. Twenty-two patients had either no or mild pain and 24 patients were able to walk freely with or without support. Almost 78% of patients had either excellent or good clinical results based on Harris hip score. Heterotopic ossification was noted in 8 hips.

Total hip arthroplasty was found in this study to be an effective salvage procedure after failed treatment of intertrochanteric fracture in elderly patients.

**Keywords:** trochanteric fracture; DHS; failure; total hip arthroplasty.

### INTRODUCTION

Most intertrochanteric hip fractures can be treated successfully with internal fixation (8,13). Union

rates as high as 100% have been reported with well-reduced, stable fractures treated with optimal implant placement (1). Failure rates up to 56% have been reported, related with certain problematic fracture patterns, comminution, poor bone quality and suboptimal fixation (8).

Failed treatment of intertrochanteric fractures typically leads to profound functional disability and pain. Hip arthroplasty is considered as a salvage procedure for older patients, patients with poor bone stock, avascular necrosis of the femoral head, or patients with damaged acetabular articular cartilage (12,16,18). However, for physiologically younger patients with good bone quality, preservation of the patient's femoral head is preferable to prosthetic replacement (6).

---

■ Akram Hammad, MD, Assistant Professor in Orthopaedic Surgery.

*Orthopaedic Department, Mansoura University Hospital, Egypt.*

■ Ahmed Abdel-Aal, MD, Professor.

■ Hatem G. Said, MD, Lecturer.

■ Hatem Bakr, MD, Lecturer.

*Orthopaedic Department, Assiut University Hospital, Egypt.*

Correspondence: Dr. Akram Hammad, MD, Orthopaedic Department, Mansoura University Hospital, Mansoura 35516, Egypt. E-mail: akram\_hammad@hotmail.com

© 2008, Acta Orthopædica Belgica.

---

There is a number of technical hurdles to a successful arthroplasty in this group of patients, including presence of the fixation device, hip stiffness, bone deformity, non-union site, trochanteric problem and poor bone stock (5).

The aim of the current study is to evaluate the short-term clinical and radiological results of total hip replacement as a salvage procedure for failed treatment of intertrochanteric fracture.

### PATIENTS AND METHODS

Between 1999 and 2005, 32 patients underwent total hip arthroplasty for salvage of failed treatment of intertrochanteric fractures ; one case was bilateral.

There were 21 women and 11 men with a mean age of 64 years (range, 46 to 85 years). All patients had their fractures originally fixed with a Dynamic Hip Screw (DHS). The mean time from primary fixation to the salvage arthroplasty was 15 months (range, 4 to 32 months).

The indication for salvage was either one or a combination of the following : non-union, loss of fixation, avascular necrosis of the femoral head, or fixation failure such as screw cut out from the femoral head.

The salvage procedure was carried out through a posterolateral exposure in 18 hips and through a lateral exposure in 15 hips. Trochanteric slide was used in five patients. The hip was dislocated before removing the implant to avoid intraoperative femoral shaft fracture, as the hip is usually quite stiff and the bone is of poor quality.

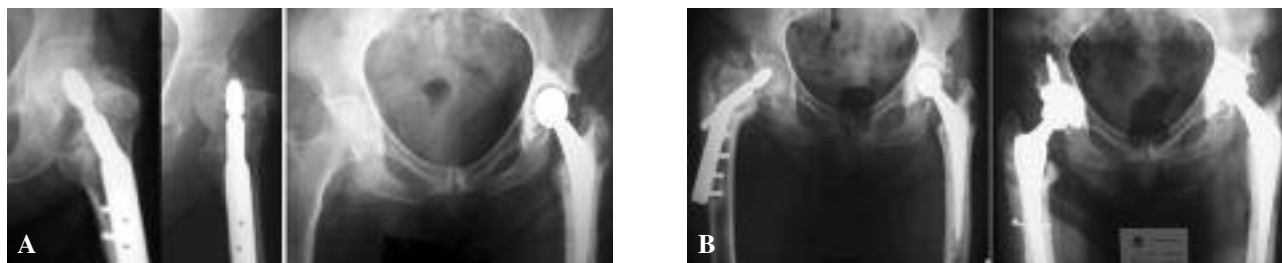
A cemented prosthesis was used in 21 hips, a cementless prosthesis in 5 hips and a hybrid prosthesis in 7 hips. There were five long stemmed prostheses and three extended neck prostheses. We used the principle of

Patterson *et al* (17) to avoid cement extrusion through the screw hole with subsequent fracture through this stress riser. Harris hip score (HHS) (9) was used for clinical evaluation preoperatively, postoperatively and at last follow-up. Radiological evaluation of the integrity of the fixation was done at every follow-up visit. We used the criteria of Engh *et al* (3) for evaluation of bone ingrowth for cementless stems. Cementless cup loosening was defined as implant migration, a complete radiolucent line at the implant-bone interface, or fixation screws breakage (5). The criteria of Harris *et al* (10) were used for evaluation of cemented stems and those of Hodgkinson *et al* (11) criteria for evaluation of cemented cups. Brooker's classification (2) was used to grade any heterotopic new bone formation.

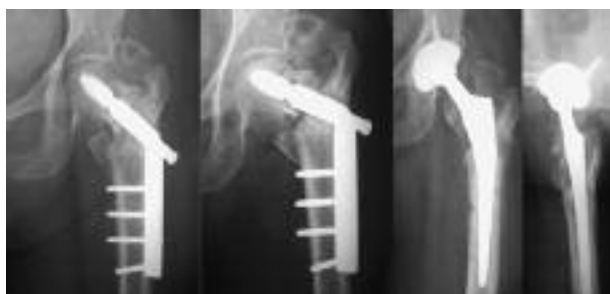### RESULTS

The mean operative time was 190 minutes (range, 120 to 280 minutes) with a mean estimated external blood loss of 1150 ml (range, 700 to 3000 ml). The mean follow-up period was 57 months (range, 30 to 108 months).

One patient had an intraoperative non displaced proximal femoral fracture which was managed by using a long-stem prosthesis and cerclage wiring. Six patients had a total of seven postoperative complications. One patient had early postoperative dislocation which was reduced by closed manipulation with no recurrence thereafter ; deep venous thrombosis was noted in in three patients, non fatal pulmonary embolism in one and upper gastrointestinal bleeding in two, one of which had upper gastrointestinal endoscopy and blood transfusion. We had no early postoperative mortality.



**Fig. 1.** — A : 67-year-old man with a failed DHS on the left side, which was salvaged by a cemented total hip replacement. B : 32 months later he had a trochanteric fracture on the right side, which was fixed with a DHS ; this fixation failed and the hip was also salvaged by total hip replacement. Both hips had excellent results at 82 and 34 months.



**Fig. 2.** — This 58-year-old man with failed DHS had a cementless hip replacement with excellent clinical result at 48 months.

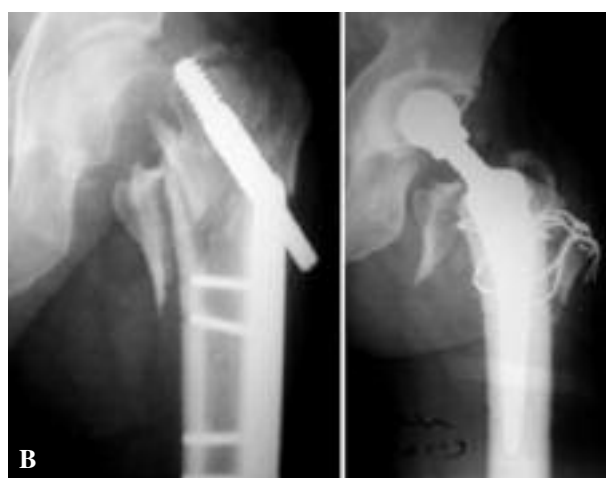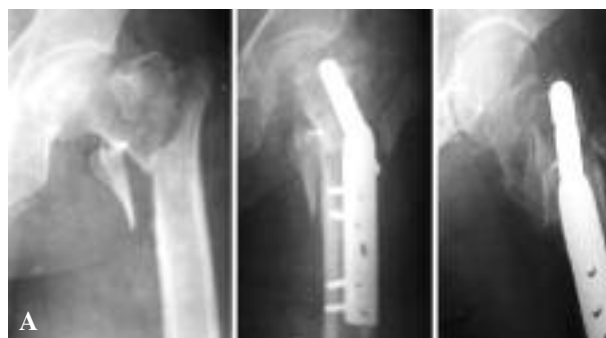At the end of follow-up, six patients had died, all with their implant in place, after an average follow-up of 26 months (range, 22 to 40 months). We had 26 patients alive with 27 arthroplasties for review by the end of this study.

Preoperatively, all patients had either moderate or severe pain and were unable to walk except 9 patients who had a limited walking ability with use of either two arm supports in seven patients or a walker in another two patients.

At the last follow-up, there were 15 hips out of 27 (55.5%) pain free, 8 hips (29.6%) with mild pain, 4 with moderate pain and none with severe pain. The pain was in the region of the greater trochanter. All patients were able to walk with different walking ability. Twenty three patients (88.4%) could walk outdoors freely; eleven of them (42.3%) were using either one cane or one elbow crutch. Three patients had a limited walking ability with use of two axillary crutches. One of them was able to walk indoors only.

The mean preoperative Harris hip score was 26 points and improved to a mean of 84 points at the latest follow-up. At the end of follow-up, we had 21 hips (77.7%) with good or excellent results, four hips (14.8%) with fair results and two hips with poor results.

Radiological evaluation at latest follow-up showed that there were two cemented stems with probable loosening at 4 and 6 years, with minimal discomfort. Neither of them had a revision to date. There were four patients with trochanteric non union.



**Fig. 3.** — A : 72-year-old man with poorly fixed intertrochanteric fracture. B : secondary hip replacement with good result at 40 months. There was persistent mild pain over the greater trochanter.

Heterotopic ossification was found in 8 hips (29.6%) out of 27 : five were type I, one was type II and two were type III according to Brooker's grading.

## DISCUSSION

An intertrochanteric fracture for which treatment has failed presents a difficult challenge to the orthopedic surgeon. In younger patients, salvage typically involves efforts to preserve the hip joint with repeat internal fixation, whereas in older patients, prosthetic replacement is a reliable salvage option (7). Hip arthroplasty dramatically alleviated pain and allowed most patients to regain function that otherwise had been lost, which is the hallmark of an effective salvage procedure (5,6,7,16).

There are few published series on the results of hip arthroplasty for salvage of failed internal fixation of intertrochanteric fracture. Mariani and Rand (15) reported on nine patients with intertrochanteric non union treated with hip arthroplasty. All patients had functional improvement at an average follow-up of 6.6 years. Mehlhoff *et al* (16) reported on 13 patients followed for a mean of 34 months: five patients had good to excellent results, three had dislocation, of which two required revision for instability. Stoffelen *et al* (18) reported on seven hip arthroplasties for intertrochanteric non union: five out of seven had good or excellent results after a mean duration of follow-up of thirty-four months.

Haidukewych and Berry (5) reported on 60 patients, 32 of whom had total hip replacement. Forty-four patients were followed for a mean of five years. Two hips were revised for aseptic loosening at 8 and 10 years. There was one patient with dislocation. The 7-year survivorship of arthroplasties free of revision for any reason was 100% and 88% at 10 years.

Recently, Laffosse *et al* (14) reported on 29 patients who had surgery for early fixation failure. All had the same cementless modular femoral stem; only 7 patients had a total hip replacement. Twenty-three patients were followed for a mean of five years with satisfactory results as regard pain and mobility. There were two cases with dislocated hemiarthroplasty, one of them reduced by manipulation and one patient with heterotopic ossification.

Tabsh *et al* (19) compared the results of 53 routine total hip arthroplasties with those of 53 total hip arthroplasties performed after failed treatment of proximal femoral fracture (only 6 patients had failed treatment of intertrochanteric fracture). They found increased prevalence of complications and surgical difficulties in the group of patients who had had a previous hip fracture.

When arthroplasty is performed as salvage of failed internal fixation of intertrochanteric fractures, a number of technical difficulties must be overcome. Dislocation of the hip may carry the risk of a shaft fracture as the hip is usually stiff in this group of patients, so it is safer to dislocate the hip prior to implant removal (7). Cortical holes left by

previous screws should be plugged when a cemented stem is used. Patterson *et al* (17) described an easy and smart method to sort this problem by blocking these holes by short cortical screws till cement is injected and pressurized. Cortical holes are considered as stress risers and can lead to femoral shaft fracture with uncemented stems (4). Cortical holes as well as the DHS barrel hole should be grafted with bone from the excised proximal fragment (7).

The proximal fragment is usually in a distorted position due to fracture medialization. Mobilization of this fragment should be careful to avoid injury of adjacent neurovascular structures. Understanding the existing deformity of the proximal part is essential to allow preparation of the medullary canal safely without perforation or fracture. Bone loss below the level of resection of standard total hip replacement is a common occurrence (6,7). A calcar replacement or extended neck prosthesis may be needed to restore leg length and to achieve hip stability (5).

The greater trochanter warrants special care as it may be a separate ununited fragment or a malunited fragment that prevents entrance into the medullary canal (5). Under these circumstances the use of a trochanteric slide technique may be of great help.

For many older patients, cemented fixation is advantageous, particularly with poor bone quality and wide medullary canal (5,7).

The strengths of the present study include a relatively large number of patients and an excellent rate of follow-up in this elderly population. Also, all procedures were performed at a time when hip arthroplasty techniques and implants had evolved sufficiently to treat this challenging problem effectively. The weakness of this study includes the multiple prosthetic designs used and the subjectivity of the choices between the methods of fixation made by the surgeon.

Hip arthroplasty performed after failed treatment of an intertrochanteric fracture is technically more difficult than routine primary total hip arthroplasty. The majority of patients included in this study had good pain relief and marked functional improvement. Despite the technical difficulties encountered,

there were surprisingly few major complications. Therefore, we conclude that total hip arthroplasty is an effective salvage procedure after failed treatment of intertrochanteric fracture in elderly patients.

## REFERENCES

1. **Baumgaertner MR, Solberg BD.** Awareness of tip-apex distance reduces failure of fixation of trochanteric fractures of the hip. *J Bone Joint Surg* 1997 ; 79-B : 969-971.
2. **Brooker AF, Bowerman JW, Robinson RA et al.** Ectopic ossification following total hip replacement. Incidence and a method of classification. *J Bone Joint Surg* 1973 ; 55-A : 1629-1632.
3. **Engh CA, Bobyn JD, Glassman AH.** Porous-coated hip replacement. The factors governing bone ingrowth, stress shielding, and clinical results. *J Bone Joint Surg* 1987 ; 69-B : 45-55.
4. **Eschenroeder HC jr, Karackow KA.** Late onset femoral stress fracture associated with extruded cement following hip arthroplasty. A case report. *Clin Orthop* 1988 ; 236 : 210-213.
5. **Haidukewych GJ, Berry DJ.** Hip arthroplasty for salvage of failed treatment of intertrochanteric hip fractures. *J Bone Joint Surg* 2003 ; 85-A : 899-904.
6. **Haidukewych GJ, Berry DJ.** Salvage of failed internal fixation of intertrochanteric hip fractures. *Clin Orthop* 2003 ; 412 : 184-188.
7. **Haidukewych GJ, Berry DJ.** Salvage of failed treatment of hip fractures. *J Am Acad Orthop Surg* 2005 ; 13 : 101-109.
8. **Haidukewych GJ, Israel TA, Berry DJ.** Reverse obliquity of fractures of the intertrochanteric region of the femur. *J Bone Joint Surg* 2001 ; 83-A : 643-650.
9. **Harris WH.** Traumatic arthritis of the hip after dislocation and acetabular fracture : treatment by mold arthroplasty. *J Bone Joint Surg* 1969 ; 51-A : 737-755.
10. **Harris WH, McCarthy JC Jr, O'Neill DA.** Femoral component loosening using contemporary techniques of femoral cement fixation. *J Bone Joint Surg* 1982 ; 64-A : 1063-1067.
11. **Hodgkinson JP, Shelley P, Wroblewski BM.** The correlation between the roentgenographic appearance and operative findings at the bone-cement junction of the socket in Charnley low friction arthroplasties. *Clin Orthop* 1988 ; 228 : 105-109.
12. **Kim YH, Oh JH, Koh YG.** Salvage of neglected unstable intertrochanteric fractures with cementless porous-coated hemiarthroplasty. *Clin Orthop* 1992 ; 277 : 182-187.
13. **Kyle RF, Gustilo RB, Premer RF.** Analysis of six hundred and twenty-two intertrochanteric hip fractures. *J Bone Joint Surg* 1979 ; 61-A : 216-221.
14. **Laffosse JM, Molinier F, Tricoire JL et al.** Salvage hip arthroplasty for trochanteric osteosynthesis failure in the elderly. *Acta Orthop Belg* 2007 ; 73 : 729-736.
15. **Mariani EM, Rand JA.** Nonunion of intertrochanteric fractures of the femur following open reduction and internal fixation. Result of second attempt to gain union. *Clin Orthop* 1987 ; 218 : 81-89.
16. **Mehlhoff T, Landon GC, Tullos MH.** Total hip arthroplasty following failed internal fixation of hip fractures. *Clin Orthop* 1991 ; 269 : 32-37.
17. **Patterson BM, Salvati EA, Huo MH.** Total hip arthroplasty for complications of intertrochanteric fracture. A technical note. *J Bone Joint Surg* 1990 ; 72-A : 776-777.
18. **Stoffelen D, Haentjens P, Reynders P et al.** Hip arthroplasty for failed internal fixation of intertrochanteric and subtrochanteric fractures in the elderly patient. *Acta Orthop Belg* 1994 ; 60 suppl 1 : 135-139.
19. **Tabsh I, Waddell JP, Morton J.** Total hip arthroplasty for complications of proximal femoral fractures. *J Orthop Trauma* 1997 ; 11 : 166-169.