



Outcome of proximal humerus fractures treated by PHILOS plate internal fixation Experience of a District General Hospital

Rizwan SHAHID, Abid MUSHTAQ, Julian NORTHOVER, Mohammad MAQSOOD

From Lincoln County Hospital, Lincoln, United Kingdom

Proximal humerus fractures have been a challenge to achieve stable fixation. PHILOS (Proximal Humerus internal locking system) is part of the latest generation of locking compression plates for proximal humeral fracture fixation. We aim to assess the clinical and functional outcome of proximal humeral fractures (2-part, 3-part and 4-part) treated with the PHILOS plate.

We prospectively reviewed 50 patients who had a proximal humeral fracture treated with the PHILOS plate from September 2002 to September 2006 in our institution. Clinical outcome was measured using the patient-based Oxford shoulder and DASH scoring systems.

Five patients died and four were lost to follow-up. Eleven patients had 2-part, eleven 3-part and eighteen 4-part fractures. Mean follow-up time was 21.7 months (range : 6-44 months). Radiological union was achieved within 8 weeks in 40/41 fractures ; complications were noted in four cases. Better results were achieved in younger than in older patients, and in male than in female patients. The number of fracture fragments did not appear to affect the results, but associated dislocation of the humeral head was a pejorative factor.

Our study has shown that the PHILOS plate is a reliable implant. A direct correlation was observed between Oxford shoulder and DASH scores.

Keywords : PHILOS plate ; proximal humerus fracture.

INTRODUCTION

Fractures of the proximal humerus represent approximately 4% of all fractures and 26% of humerus fractures (7). Three and four-part fractures (13-16% of proximal humerus fractures) have been a challenge to achieve stable fixation. Difficulties have been multifactorial, including osteoporotic bone, angular instability, implant impingement, loss of reduction and backing out of screws.

The aims of treatment for proximal humerus fractures are a pain free shoulder and restoration of activities of daily living. The operating surgeon must have a formal discussion with the patient regarding the treatment, rehabilitation and expected

-
- Rizwan Shahid, MRCS, Orthopaedic Surgeon.
 - Abid Mushtaq, MRCS, Orthopaedic Surgeon.
 - Julian Northover, MRCS, Orthopaedic Surgeon.
 - Mohammed Maqsood, FRCS (T&O), Orthopaedic Surgeon.

Department of Orthopaedic Surgery, Lincoln County Hospital, United Kingdom.

Correspondence : Rizwan Shahid, 31, Kingswood road, Wollaton, Nottingham, United Kingdom NG8 1LD.

E-mail : dr_rizwan12@hotmail.com

© 2008, Acta Orthopædica Belgica.

outcome. It is important to understand the injury including the patient's age, expectations, medical conditions, bone quality and pros and cons of different modalities of treatment.

There are different techniques available for fixation of these fracture including bone sutures, cerclage wires, K-wires, tension band wires, T-plates, intramedullary devices, double tubular plates, the Polaris nail, the Plan Tan Humerus Fixator Plate and prosthetic replacements (16,18,20,22,23,24,25). Many complications of proximal humeral fracture fixation have been reported. These include non-union, malunion, avascular necrosis, rotator cuff impingement and implant failure. The osseous architecture of the humeral head with poor central cancellous bone stock particularly in elderly patients, leads to a high risk of fixation failure with conventional plate-and-screw fixation (10,11,14). The PHILOS plate has been introduced to reduce these complications but there are few studies published on the results of this device.

The PHILOS plate (Synthes Stratec Medical Ltd., Philadelphia, USA) is a part of the latest generation of locking compression plates that is designed specifically for fractures of the proximal humerus. The PHILOS plate has locking screws that provide angular stability and better hold even in osteoporotic bone. The screws are placed in converging and diverging directions to provide an optimal repartition of the screws and a stable fixation. Biomechanical studies have confirmed this to be of benefit over conventional plate fixation via unlocked screws (4). This secure reduction allows early postoperative mobilisation. Multiple holes in the proximal part of the plate are also available for suture anchors to the rotator cuff to help the soft tissue augmentation. The PHILOS plate can therefore provide an excellent stable construct even in multifragmented osteoporotic proximal humerus fractures.

MATERIALS AND METHODS

Inclusion criteria for the study were patients with proximal humerus fractures treated with a locking compression (PHILOS) plate at Lincoln County Hospital between September 2002 and September 2006. This included patients with associated dislocation of the shoulder, failure of conservative treatment and patients undergoing revision surgery for failure of other implants. Exclusion criteria were pathologic fractures from primary or metastatic tumours and age under 18 years.

There were 50 patients meeting our inclusion and exclusion criteria. Four patients were lost to follow-up and 5 died leaving 41 patients (table I). All patients were followed up for a minimum of 6 months. All patients were operated on by one senior orthopaedic surgeon with an interest in trauma surgery.

Anteroposterior, lateral and axillary radiographs were taken preoperatively. These were reviewed by two senior authors to determine the Neer's classification (15) of the fracture. The fracture pattern was also confirmed intra-operatively. In selected cases CT scan was done in order to know the extent of articular surface involved.

Basic patient demographics, mechanism of injury and Neer's fracture classification (15) were recorded. The functional outcome of patients was assessed by using the Oxford shoulder scoring system (8) and DASH (Disability of arm, shoulder and hand) scoring system (12). Post operative radiographs were reviewed for evidence of bony union or complications (non-union, avascular necrosis, implant failure, etc.). This information was entered into a Microsoft Excel database for statistical analysis.

Of the 41 patients in our study 9 were males and 32 were females. Male patients were significantly younger, with an average age of 46.8 years, compared to female patients (average age 66.8 years).

Operative Technique

All operations were performed under general anaesthesia with the patient in the "beach chair" position. Patients received 1.5 grams of Cefuroxime intravenously

Table I. — Correlation between fracture type and outcome

	No. of patients	Average age (years)	Oxford score	DASH score	Complications
2 - part	11	61.9	35.1	40.3	0
3 - part	11	65.5	24.4	22.8	1
4 - part	19	60.8	31.4	31.3	3

at the induction of anaesthesia. A deltopectoral approach was used, and the conjoint tendon was retracted medially. The fragments were indirectly reduced and temporarily fixed with the help of K-wires under image intensifier control. After obtaining acceptable reduction, the PHILOS plate was placed at least 8 mm distal to the upper end of the greater tuberosity (by using the insertion guide). The long head of the biceps tendon was identified and preserved. The plate was then placed lateral to the long head of the biceps without compromising its function. The humeral head fragment as well as the metaphyseal shaft fracture was fixed with locking head screws. Standard length wires were inserted into the humeral head through a guide and the length of screw required was determined by placing a measuring device over the protruding wire. The corresponding length locking screw was then inserted using a specially designed star drive screwdriver. A 4Nm torque wrench was used to prevent cold welding. The final position of the implant was checked with the image intensifier in multiple planes. The shoulder was checked for stability of fixation, range of movements and absence of impingement. None of our patients required bone grafting. Closure was with 2/0 vicryl to muscle, fascia and subcutaneous tissue and 3/0 monocryl subcuticular sutures to the skin. A Lancaster sling was used postoperatively in every patient. All patients started early passive and active assisted mobilisation within the first 24 hours under close supervision of a specialist shoulder physiotherapist. They were discharged within 24-48 hours postoperatively unless there were any other associated co-morbidities or social circumstances preventing this.

Patients were followed up at 2 weeks, 6 weeks, 3, 6 and 12 months. Radiographical examination was performed at the six-week appointment to assess bony union and was repeated at three months if union had not been achieved.

RESULTS

In 40 of our 41 patients (97.6%) the fracture had progressed to radiological union within 8 weeks. Four patients developed complications or adverse events of varying degrees. One patient developed non-union. The second patient developed shoulder stiffness and was taken back to theatre for removal of the implant and manipulation under anaesthesia. The third patient also underwent removal of the implant as one of the screws was protruding

through the articular surface. The fourth patient had removal of one of the screws which was also protruding through the articular surface. These four patients had poorer outcome scores than the others, in both Oxford (33.3 vs 30.2) and DASH (43.4 vs. 30.2) scoring systems.

Male patients achieved slightly better outcomes with an average Oxford score of 29.3 (range 51-13) and an average DASH score of 26.6 (range 0-55) compared to 30.8 (range 12-58) and 32.8 (range 0-87.1) respectively for females. All four of the complications that were observed occurred in the female patient group.

Eleven patients had 2-part fractures (fig 1), eleven had 3-part fractures (fig 2) and nineteen had 4-part fractures. The ages of patients sustaining 2, 3, and 4-part fractures were similar. There did not seem to be any correlation between the number of fracture fragments and the functional outcome score (table I), however it was noted that the complication rate seemed to rise with an increasing number of fracture parts.

Five of the 41 patients sustained a dislocation of the gleno-humeral joint at the time of injury. The outcome for these patients was not as good as those who did not sustain a dislocation, with higher Oxford (37.8 vs. 29.5) and DASH (43.1 vs. 29.8) scores.

Out of the 41 patients, 21 were less than 65 years and 20 were 65 years of age or more. There were more male patients in the younger age group (8 vs. 1) and more females in the older age group (19 vs. 13). The numbers of 2, 3, and 4-part fractures in each age group were similar. Patients in the younger age group had better outcomes than those in the older age group, with both Oxford (28.0 vs. 33.1) and DASH (25.7 vs. 37.5) scoring systems.

We did not experience any cases of neurovascular deficit, infection or avascular necrosis postoperatively.

DISCUSSION

The majority of our patients have been satisfied with the outcome of their surgery. Fracture union was achieved in 40 out of 41 patients (97.6%) with an overall average Oxford score of 30.5 (range 12 to

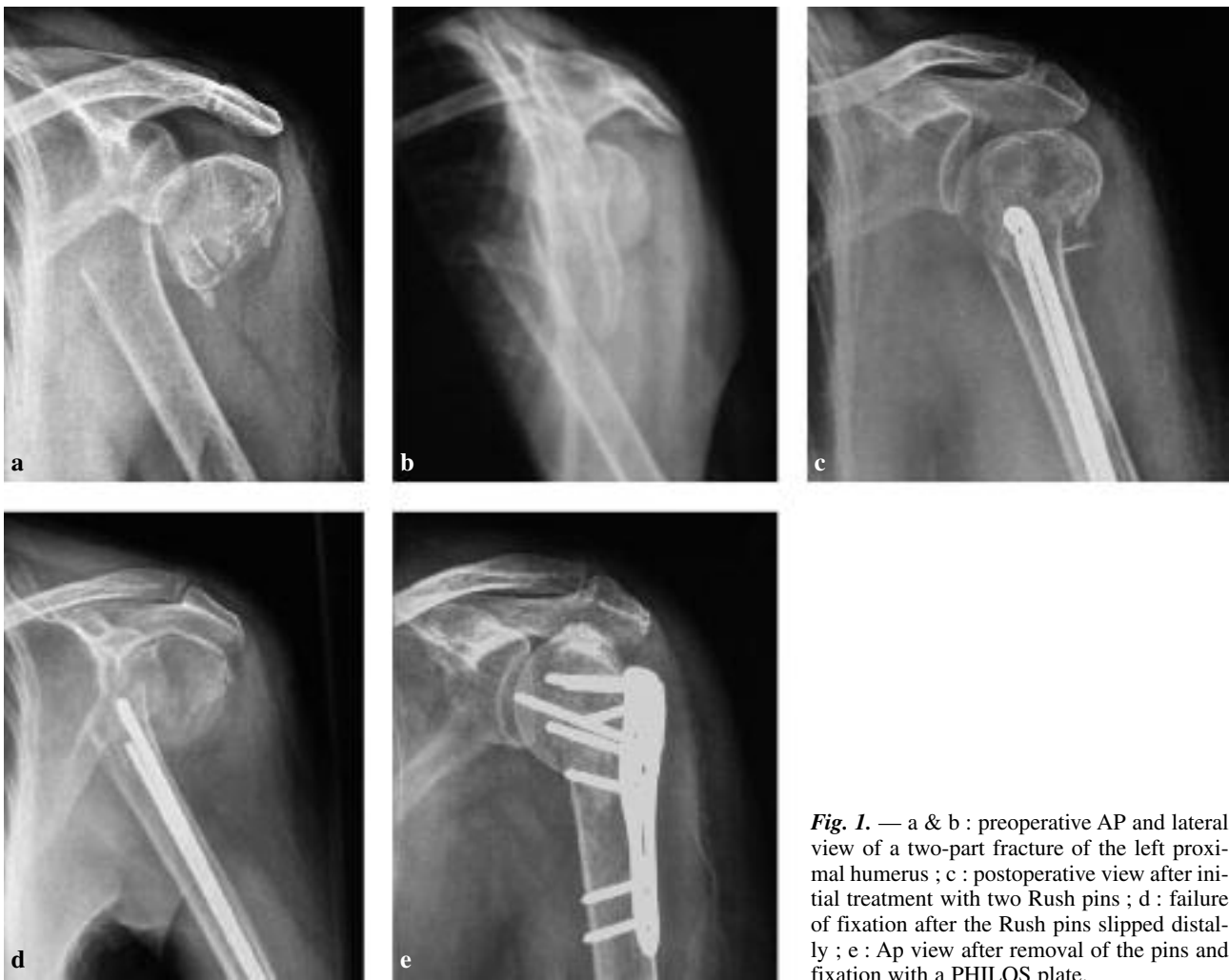

Fig. 1. — a & b : preoperative AP and lateral view of a two-part fracture of the left proximal humerus ; c : postoperative view after initial treatment with two Rush pins ; d : failure of fixation after the Rush pins slipped distally ; e : Ap view after removal of the pins and fixation with a PHILOS plate.

58) and DASH score of 31.5 (range 0 to 87.1). The only patient who did not progress to full union declined further surgery as she felt that she was able to perform all activities necessary for daily living without undue discomfort.

Analysis of the data has revealed that older patients tended to have worse results from surgery than younger patients, as did patients suffering complications or requiring revision surgery.

Patients with an associated dislocation of the glenohumeral joint did not fare as well as those that did not. This is thought to be due to the greater force of injury sustained and consequently greater soft tissue damage and stripping. Interestingly the increasing number of parts of the fracture did not seem to have any correlation to the final functional

outcome score. However, the complication rate did seem to increase with the increasing number of fracture parts, reflecting the difficulty of treatment of more complex fracture configurations.

We were unable to demonstrate any convincing correlation between the time from injury to surgery and functional outcome although surgery on a relatively new fracture is undoubtedly easier.

It has been difficult to compare the results of our study to those of other studies, owing to differing inclusion and exclusion criteria and to the variety of shoulder scoring systems used. We feel that our inclusion criteria have been very broad, including very elderly patients and patients who have failed operative and non-operative treatments. Even in spite of this we feel that our results are comparable

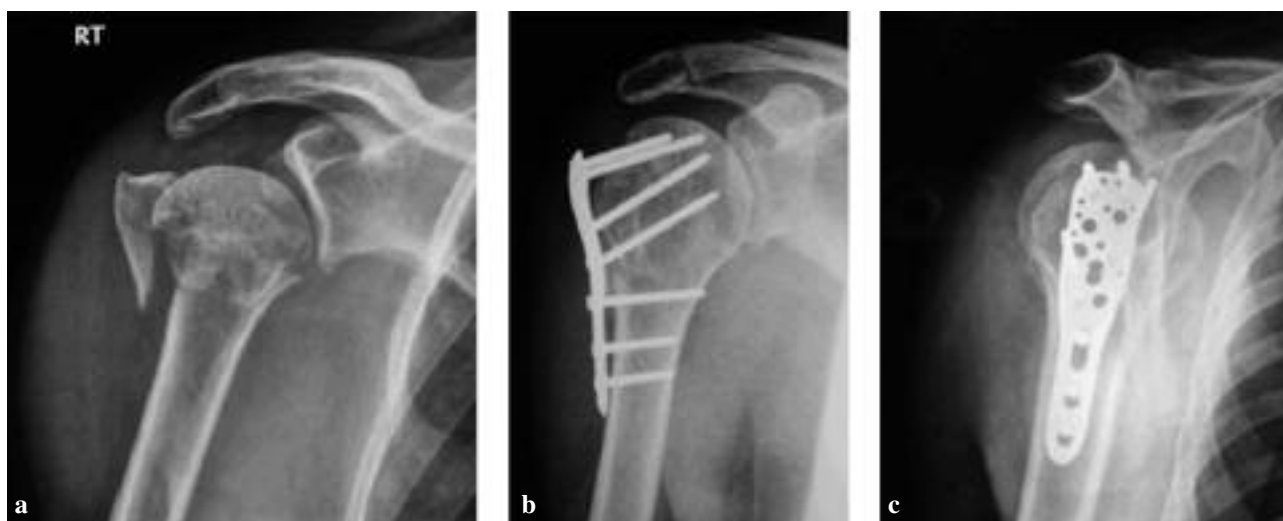

Fig. 2. — a : Preoperative AP view of a three-part proximal humeral fracture ; b & c : postoperative AP and lateral view of the same patient after fixation with a PHILOS plate.

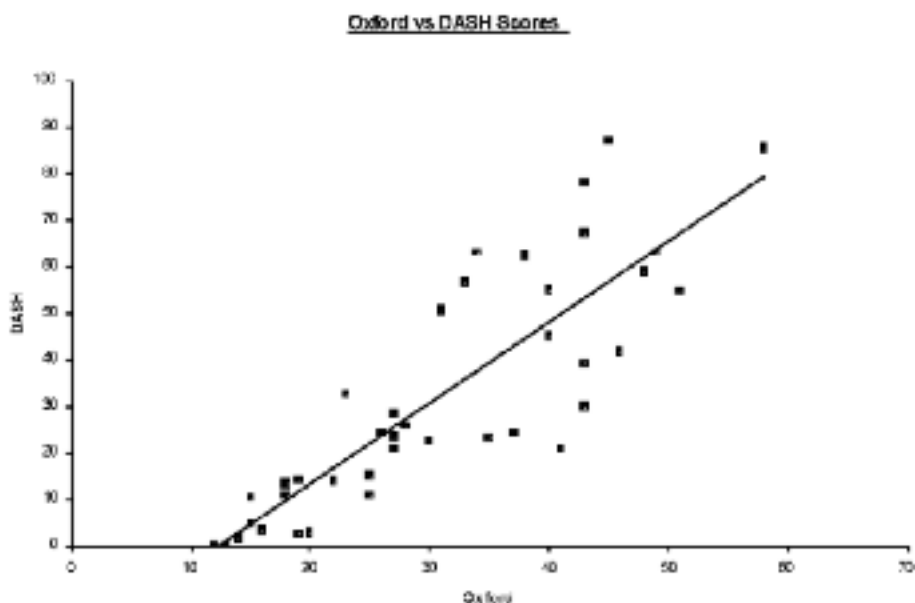


Fig. 3. — Correlation between the Oxford scoring system and DASH score

to other similar publications. In the study of Atalar *et al* (1), 10 patients treated with minimally invasive bone grafting and suturing had an average DASH score of 23.0. This is comparable to our younger age group of under 65 year olds (average age 51.2) who had a DASH score of 25.7. Plecko and Kraus (17) reported good results with a Locking

Proximal Humeral Plate (LPH). Their series of 36 patients (average age 57.5 years) had a DASH score of 18.0. However, it appears that they were more selective about the patients included in their study, choosing to exclude “comminuted humeral head fractures in old patients that cannot be reconstructed properly”.

The rate of union in our series (40/41 or 97.6%) is more favourable than the published results of both Bjorkenheim *et al* (2) and Charalambous *et al* (3) with the PHILOS plate, achieving union in 70/72 (97.2%) and 20/25 (80%) respectively. These papers also noted problems with implant failure, screw protrusion and backing-out at rates of 3% (2/72) and 16% (4/25) respectively, compared to 5% (2/41) our study.

The conventional plate osteosynthesis has been associated with frequent hardware impingement (6) but Bjorkenheim *et al* (2) found no such complication with the PHILOS plate in their study. The main advantage of the PHILOS plate is apparent in elderly patients, as Bjorkenheim *et al* found no failure of the internal fixation in this particular group and they could attain an activity level that was sufficient to satisfy their patients' needs regarding independent daily living. The plate can even withstand a new fall (2). Rose *et al* (21) reported good anatomical reduction that was achieved in the majority of the patients with near anatomic fixation being achieved in the remainder.

To our knowledge, there are only few studies in the English literature on the PHILOS plate. We are presenting the largest series of cases from the UK. We have used Oxford shoulder score and DASH score to assess the functional outcome of our patients. We believe that these scoring systems provide a realistic outcome of these patients which has not been used in other studies of this implant. This is partly represented by the very good correlation between the two scoring systems (fig 3).

CONCLUSION

The results of management of proximal humeral fractures with the PHILOS plate were equally good in all the patients but the functional outcome was better in younger patients. If there was an associated dislocation of the glenohumeral joint the results of surgery significantly deteriorated. Delay in the surgical treatment and increasing number of parts of the fracture did not appear to be detrimental to the end result.

REFERENCES

1. **Atalar AC, Demishan M, Uysal M, Seyahi A.** [Treatment of Neer type 4 impacted valgus fractures of the proximal humerus with open reduction, elevation and grafting.] (in Turkish). *Acta Orthop Traumatol Turc* 2007 ; 41 : 113-119.
2. **Bjorkenheim JM, Pajarinen J, Savolainen V.** Internal fixation of proximal humeral fractures with a locking compression plate : a retrospective evaluation of 72 patients followed for a minimum of 1 year. javascript : AL_get(this, 'jour', 'Acta Orthop Scand.'). *Acta Orthop Scand* 2004 ; 75 : 741-745.
3. **Charalambous CP, Siddique I, Valluripalli K et al.** Proximal humeral internal locking system (PHILOS) for the treatment of proximal humeral fractures. *Arch Orthop Trauma Surg.* 2007 ; 127 : 205-210.
4. **Chudik SC, Weinhold P, Dahners LE.** Fixed-angle plate fixation in simulated fractures of the proximal humerus : a biomechanical study of a new device. *J Shoulder Elbow Surg* 2003 ; 12 : 578-588.
5. **Cofield RH.** Comminuted fractures of the proximal humerus. *Clin Orthop* 1988 ; 230 : 49-57.
6. **Cordasco FA, Bigliani LU.** Complications of proximal humerus fractures. *Tech Orthop* 1997 ; 12 : 50.
7. **Court-Brown CM, Garg A, McQueen M.** The epidemiology of proximal humeral fractures. *Acta Orthop Scand* 2001 ; 72 : 365-371.
8. **Dawson J, Fitzpatrick R, Carr A.** Questionnaire on the perception of patients about shoulder surgery. *J Bone Joint Surg* 1996 ; 78-B : 593-600.
9. **Frigg R.** Development of the locking compression plate. *Injury* (Suppl 2) 2003 ; 34 : 6-10.
10. **Hall MC, Rosser M.** The structure of the upper end of the humerus with reference to osteoporotic changes in senescence leading to fractures. *Can Med Assoc J* 1963 ; 88 : 290-294.
11. **Hawkins RJ, Bell RH, Gurr K.** The three-part fracture of the proximal part of the humerus. Operative treatment. *J Bone Joint Surg* 1986 ; 68-A : 1410-1414.
12. **Hudak PL, Amadio PC, Bombardier C.** Development of an upper extremity outcome measure : the DASH (disabilities of the arm, shoulder and hand). *Am J Ind Med* 1996 ; 29 : 602-608.
13. **Ko JY, Yamamoto R.** Surgical treatment of complex fractures of the proximal humerus. *Clin Orthop* 1996 ; 327 : 225-237.
14. **Kristiansen B, Christensen SW.** Plate fixation of proximal humeral fractures. *Acta Orthop Scand* 1986 ; 57 : 320-323.
15. **Neer CS 2nd.** Displaced proximal humeral fractures. I. Classification and evaluation. *J Bone Joint Surg* 1970 ; 52-A : 1077-1089.
16. **Park MC, Murthi AM, Bigliani LU.** Two-part and three-part fractures of the proximal humerus treated with suture fixation. *J Orthop Trauma* 2003 ; 17 : 319-325.

17. **Pleko M, Kraus A.** Internal fixation of proximal humeral fractures using the locking proximal humeral plate. *Oper Orthop Traumatol* 2005 ; 17 : 25-50.
18. **Rajasekhar C, Ray PS, Bhamra MS.** Fixation of proximal humeral fractures with the Polaris nail. *J Shoulder Elbow Surg* 2001 ; 10 : 7-10.
19. **Ring D, Jupiter JB.** Internal fixation of the humerus with locking compression plates. *Tech Shoulder and Elbow Surg* 2003 ; 4 : 169-171.
20. **Robinson CM, Page RS.** Severely impacted valgus proximal humeral fractures. Results of operative treatment. *J Bone Joint Surg* 2003 ; 85-A : 1647-1655.
21. **Rose PS, Adams CR, Torchia ME et al.** Locking plate fixation for proximal humeral fracture : Initial results with the new implant. *J Shoulder Elbow Surg* 2007 ; 16 : 202-207.
22. **Sadowski C, Riand N, Stern R, Hoffmeyer P.** Fixation of fractures of the proximal humerus with the PlantTan Humerus Fixator Plate : Early experience with a new implant. *J Shoulder Elbow Surg* 2003 ; 12 : 148-151.
23. **Sehr JR, Szebo RM.** Semitubular blade plate for fixation in the proximal humerus. *J Orthop Trauma.* 1988 ; 2 : 327-332.
24. **Seidel H.** Humeral locking nail : A preliminary report. *Orthopaedics* 1989 ; 12 : 219-226.
25. **Wanner GA, Wanner-Schmid E, Romero J et al.** Internal fixation of displaced proximal humeral fractures with two one-third tubular plates. *J Trauma* 2003 ; 54 : 536-544.