



## Self-reported shoulder function following massive rotator cuff tear reconstruction using a triceps brachii interposition flap

Brian SCHULZ, John NYLAND, Jeff KEEN, Arthur MALKANI

From the Department of Orthopaedic Surgery, University of Louisville, Louisville, KY, USA

This retrospective study evaluated patient shoulder function and general health at a minimum of two-years following massive rotator cuff reconstruction using the long head of the triceps brachii muscle. Fourteen patients completed the Disabilities of the Arm, Shoulder, and Hand scale (DASH), the Shoulder Pain and Disability Index (SPADI), and Medical Outcomes Survey Short Form 36 (SF-36). Five others provided shoulder function and pain relief satisfaction data. Mean DASH score was 15.6 (SD : 12.1). Greatest disability was with placing an object on an overhead shelf, heavy household chores, carrying an object > 4.54 kg (10 lbs), and recreational activities with upper extremity impact or free movements. Mean SPADI disability score was 15.7 (SD : 16.3). Greatest disability was with placing an object on a high shelf, carrying a 4.54 kg (10 lb) object, and washing the back. Patients were satisfied, but disability remained with overhead tasks, carrying heavy objects, sudden upper extremity movements and impact forces.

**Keywords :** shoulder ; rotator cuff reconstruction ; triceps brachii ; survey research ; patient function.

### INTRODUCTION

As many as 60% of individuals who are older than 75 years at the time of death have partial thickness or small full-thickness rotator cuff tears (28). Tempelhof *et al* (31) reported that 23%

of 411 volunteer healthy subjects had ultrasound verified asymptomatic full thickness rotator cuff tears. When grouped by age, 13% were between 50-59 years old, while 51% of individuals > 80 years old had full thickness tears. Although to some extent asymptomatic rotator cuff tears should be regarded as “normal” degenerative attrition that does not necessarily cause pain or functional impairment, individuals who desire to perform overhead tasks or carry heavy objects generally experience considerable disability, particularly with larger tears (31). Non-operative treatment of patients with symptomatic full-thickness rotator cuff tears

- 
- Brian Schulz, Medical Student.  
*School of Medicine, University of Louisville, Louisville, Kentucky, USA.*
  - John Nyland, EdD, Associate Professor.
  - Arthur Malkani, MD, Professor.  
*Department of Orthopaedic Surgery, University of Louisville, Louisville, Kentucky, USA.*
  - Jeff Keen, MD, Orthopaedic Surgery Residency Program.  
*University of Florida, Jacksonville, Florida, USA.*
- Correspondence : John Nyland, Department of Orthopaedic Surgery, University of Louisville, 210 East Gray St., Suite 1003, Louisville, KY, USA 40202.  
E-mail : john.nyland@louisville.edu  
© 2008, Acta Orthopædica Belgica.
-

usually results in continued pain and shoulder dysfunction, therefore it is generally reserved for patients who have functional goals that are below shoulder level (4) or for patients with medical comorbidities that create unreasonable anaesthesia risks (27).

While it is generally agreed that patients who desire optimal function should undergo surgery (4), "massive" tears of  $> 5 \text{ cm}^2$  in diameter as described by Cofield (7) are not as amenable to repair as smaller tears. Bigliani *et al* (3) reported that the most common factors associated with primary rotator cuff repair failure were massive tears and persistent subacromial impingement. In their report approximately 50% of patients who underwent revision surgery for massive rotator cuff tears continued to have unsatisfactory results. Factors associated with unsatisfactory results were previous lateral acromionectomy, previous detachment of the deltoid muscle origin, and poor rotator cuff musculotendinous tissue quality at the time of revision (3). McCabe *et al* (20) in a prospective cohort study of 61 patients with a rotator cuff tear who were scheduled for surgery, reported that shoulder abduction strength deficits of 50% relative to the non-impaired, contralateral shoulder when tested at  $10^\circ$  shoulder abduction were highly indicative of a massive rotator cuff tear verifying the true functional significance of larger tears.

In addition to attempted primary repair, widely ranging massive rotator cuff tear repair or reconstruction methods have been developed including debridement and subacromial decompression (10), arthroscopic repair (6), use of a synthetic interposition graft (1), subscapularis transfer (17), latissimus dorsi transfer (9,13), deltoid transfer (32), pectoralis major transfer (16), biceps brachii transfer (14), trapezius transfer (21), or teres minor transfer (24). From the overall number and variety of these surgical approaches one can infer no clearly superior procedure for treating patients who have massive rotator cuff tears (13).

Gerber *et al* (13) proposed that use of a vascularised, autogenous latissimus dorsi tendon transfer to reconstruct a massive rotator cuff tear would convert the latissimus dorsi muscle into a humeral head depressor and shoulder external rotator. It was how-

ever recommended that further electrophysiologic, biomechanical, and clinical investigations were needed to confirm this functional restoration (13). In a later report they reported that although latissimus dorsi tendon transfer provided complete pain relief at rest among 11 shoulders at 6-9 months post-surgery, it was not able to reverse superior humeral head migration, and it was still undetermined if it provided more of an active or tenodesis type shoulder external rotation effect (11). This latter point was later verified via *in vitro* biomechanical (34) and clinical (12) studies. Gerber *et al* (12) reported that reduced shoulder pain and improved range of active shoulder elevation and external rotation were not of sufficient magnitude to fully explain patient subjective results. Pain relief effectiveness is the most commonly reported finding following latissimus dorsi tendon transfer, even when radiographic evidence of progressive glenohumeral joint osteoarthritis exists (12). From the standpoint of pain relief effectiveness, reconstruction of a massive rotator cuff tear using the long head of the triceps brachii muscle has also been reported to be effective (18,22,30).

Hartrampf *et al* (15) first proposed the use of a triceps brachii musculocutaneous flap to reconstruct a massive rotator cuff defect. Miller *et al* (22) reported good pain relief and improved function in 31 patients with an average follow-up of 25 weeks post-surgery; however patients continued to experience shoulder weakness, particularly with overhead tasks. Based on this finding they suggested that patients who would benefit most from this procedure would be those whose main complaint was severe shoulder pain.

In addition to decreasing pain, optimal surgical and rehabilitative interventions for massive rotator cuff tears should improve shoulder function. The Disabilities of the Arm, Shoulder and Hand questionnaire (DASH), and the Shoulder Pain and Disability Index (SPADI) are valid and reliable patient self-report methods for determining shoulder functional disability (19,23,25,26,29). Skutek *et al* (29) performed a prospective evaluation of 7 women and 16 men (mean age of 55.3 years; SD: 10) with combined supraspinatus-infraspinatus tears who underwent primary open repair (right shoulder = 14,

left shoulder = 9) with an average follow-up time of  $57.8 \pm 15.7$  weeks. In their study rotator cuff tears were graded by diameter as described by Bateman (2) : Grade I =  $< 1 \text{ cm}^2$  (n = 0) ; Grade II =  $1-3 \text{ cm}^2$  (n = 9) ; Grade III =  $3-5 \text{ cm}^2$  (n = 7) ; and Grade IV =  $> 5 \text{ cm}^2$  (n = 6). Grade II and III tears underwent primary repair. Grade IV tears were reconstructed using a deltoid flap. They reported pre-operative DASH scores of  $49.6 \pm 8.5$  and post-operative DASH scores of  $21.6 \pm 13$  (56.5% improvement). They did not however report their findings based on rotator cuff tear size (29).

MacDermid *et al* (19) prospectively evaluated 149 consecutive patients with rotator cuff tears ranging in size from  $< 1 \text{ cm}^2$  to  $> 5 \text{ cm}^2$ . Using the Simple Shoulder Test, the Western Ontario Rotator Cuff questionnaire, and the DASH, they compared patient scores pre-operatively and at 6 months following surgery. Patients were divided into 3 groups based on surgical effectiveness. Positive responders represented patients who had a change  $> zero$  across all three scales. Equivocal responders were patients where there was disagreement in the direction of the response across scales. Negative responders had a negative change across all three scales ( $p < 0.01$ ). Those who responded positively to surgical intervention (n = 86), age =  $58 \pm 12$  years, had comorbidities including heart disease (14%), arthritis (26%), and diabetes (7%). Equivocal responders (n = 36), age =  $54 \pm 14$  years, had comorbidities including heart disease (15%), arthritis (12%), and diabetes (15%). Negative responders (n = 15), age =  $53 \pm 11$  years, had comorbidities including heart disease (15%), arthritis (31%), and diabetes (23%). Pre- and post-operative DASH scores were  $50.6 \pm 18.5$  and  $26.3 \pm 19$  (+ 48% change), respectively for the positive responders,  $50.7 \pm 19.1$  and  $46 \pm 19.8$  (+ 9.3% change), respectively for the equivocal responders, and  $48.5 \pm 20.8$  and  $62 \pm 21.2$  (- 27.8% change), respectively for the negative responders. Of the 19 patients in their series who had a massive rotator cuff tear ( $> 5 \text{ cm}^2$ ), approximately 63.2% (12 of 19) were positive responders, 31.5% (6 of 19) were equivocal responders, and only 5.3% (1 of 19) were negative responders. It must be noted however that only 39.6% (59 of 149) of the patients in their study had rotator cuff tear size recorded at

the time of surgery, and the number with massive tears who complied with follow-up measurements was not reported (19). Although their study did not specify which surgical procedure was used to repair or reconstruct rotator cuff tears based on tear size, the latissimus dorsi tendon transfer from their reported surgery type list was likely used for patients with massive  $> 5 \text{ cm}^2$  diameter tears. With this assumption, equivocal responders (17%) and negative responders (14%) had a considerably higher percentage of patients who underwent latissimus dorsi tendon transfer than the positive responder group (6%) (19). Additionally, a higher percentage of negative responders (40%) had failed primary surgical interventions compared to equivocal responders (36%) and positive responders (13%). In using the SPADI to determine the subjective disability levels of 21 patients (mean age : 62.5 years ; range : 33 to 81) who underwent primary massive rotator cuff tear repair, Moser *et al* (23) reported a function score of 10.2 for individuals who received a complete repair, but only 18.6 for individuals who received a partial repair. These findings strongly support the need for selecting the most appropriate surgical intervention at the time of the initial rotator cuff repair or reconstruction.

In evaluating 108 patients following arthroscopic rotator cuff tear repair, Roddey *et al* (25) reported that shoulder strength and range of motion impairment measures and SPADI scores had very weak relationships only explaining about 8% of the total variance. From these findings they suggested a greater complexity regarding patient qualitative perceptions of shoulder functional capabilities and satisfaction following rotator cuff surgery and a need for further research in this area.

Although these reports provided valuable information regarding patient progress (19,23,25,29), they provide limited information regarding what specific shoulder disabilities remain for these patients. Additionally, no previous study has used the DASH, SPADI and Medical Outcomes Study Short Form 36 (SF-36) to detail shoulder specific function and general health outcomes following massive rotator cuff tear reconstruction using a triceps interposition flap. The purpose of this retrospective study was to use the DASH and SPADI to specify

functional shoulder ability and SF-36 to report the overall health status of patients who underwent massive unilateral rotator cuff tear ( $> 5 \text{ cm}^2$ ) reconstruction performed by one surgeon, using the long head of the triceps brachii muscle at a minimum of two years post-surgery.

## METHODS

### Subjects

Following medical institutional review board study approval subjects were contacted to schedule an appointment to complete the DASH, SPADI, and SF-36 surveys. Twenty-four subjects who underwent long head of the triceps brachii muscle interposition flap transfer for massive rotator cuff tear reconstruction by the same surgeon were identified. Previous failed attempts at primary rotator cuff repair occurred in 18 of 24 (75%) patients. Of all patients, five either could not be located ( $n = 3$ ), or were not interested in study participation ( $n = 2$ ). Of the 19 remaining patients, five did not participate due to co-morbidities (heart transplant, recent coronary bypass, myocardial infarction, reflex sympathetic dystrophy, lumbar spine fusion) that they believed might affect their ability to safely participate in the clinical examination portion of the study, which included isometric and isokinetic strength testing (18). Fourteen patients who were a minimum of two years post-surgery completed the surveys. The five patients who chose not to participate due to co-morbidity concerns provided information regarding their level of satisfaction regarding shoulder pain and function. Prior to surgery all patients had MRI confirmed massive rotator cuff tears ( $> 5 \text{ cm}^2$ ) involving both the supraspinatus and infraspinatus tendons. Musculo-tendinous retraction to at least the glenoid rim was evident in all tears. Direct repair was not possible due to the inability to adequately mobilise the tear edges. Fatty infiltration was evident in most patients (71%, 10 of 14). Patients were equally divided between men ( $n = 7$ ) and women ( $n = 7$ ), age =  $63.1 \pm 11$  years (range : 38 to 79).

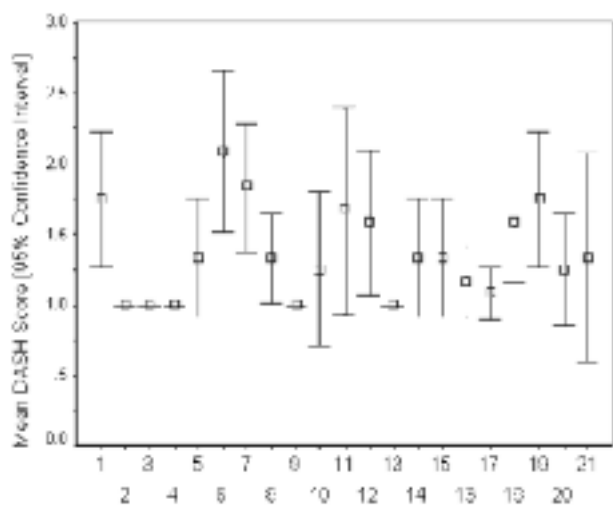
### Surgical Technique

The surgical procedure has been previously described in detail (15,18,22,30). In summary, a vertical incision was made over the deltoid beginning at the anterior aspect of the acromion process and extending distally. The deltoid was split and the subacromial bursa was entered and debrided. If significant subacromial spurring was

observed an acromioplasty was performed. An attempt was made to mobilise and primarily repair the rotator cuff. The rotator cuff margins were debrided and tagged with non-absorbable suture. A long posterior arm incision was used to harvest the long head of the triceps brachii muscle. The long head was isolated from the medial and lateral heads down to the level of the olecranon and the tendon was divided approximately 1.5 cm proximal to the olecranon process. The long head was then isolated up to the main pedicle, approximately 2-3 cm distal to the teres major tendon. Care was taken to protect the two arterial branches that originate from the profunda brachii artery that split to supply the deltoid and the long head of the triceps brachii muscle proximal to the main pedicle. Blunt dissection was performed over the superior surface of the long head of the triceps brachii muscle until the spine of the scapula could be palpated and was then carried along the lateral aspect of the scapular spine until the undersurface of the acromion was reached. Communication between the arm and shoulder incisions was created by similar dissection through the deltoid incision. A clamp passed through the dissected tunnel was used to grasp the end of the long head of the triceps brachii tendon. With care to not tension the pedicle, the tendon was transferred through the tunnel and attached to the humeral head using bone anchors. Flap placement simulated the alignment of the infraspinatus tendon. Following surgery patients were placed in a sling. Passive range of motion exercises were initiated on the first post-operative day. Patients were typically discharged from the hospital 2-3 days post-surgery. Physical therapy consisted of gradually increasing active shoulder range of motion and progressive resistance exercises over a 10-12 week period.

### Surveys

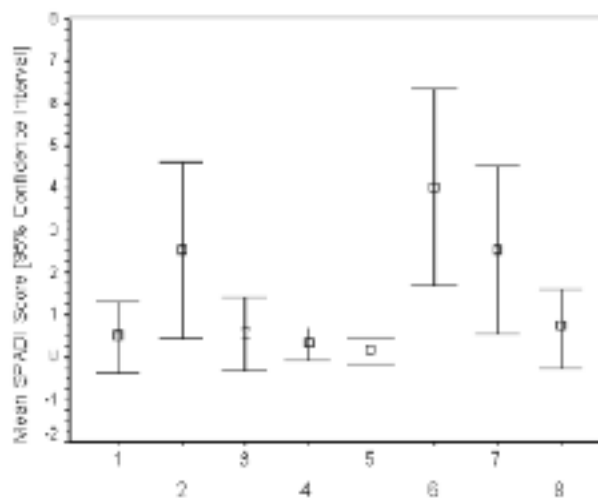
Subjects completed the DASH, SPADI, and SF-36 surveys in the presence of an independent licensed physical therapist that answered questions as needed regarding survey item interpretation. Upon completion, survey scores were compared with previously published reports using the DASH or SPADI surveys for patients who underwent rotator cuff repair or reconstruction (19,23,29). From these data shoulder specific functional disabilities that remained by the second post-operative year were identified. Descriptive, non-parametric gender comparison (Mann Whitney U Test), and correlative (Spearman Rho) statistics were performed using SPSS version 11.0 software (SPSS, Chicago, IL). An alpha level of  $P < 0.05$  was selected to indicate statistical significance.



**Fig. 1.** — DASH item results. 1. open a tight or new jar ; 2. write ; 3. turn a key ; 4. prepare a meal ; 5. push open a heavy door ; 6. place an object on a shelf above your head ; 7. do heavy household chores (e.g., wash walls, wash floors) ; 8. garden or do yard work ; 9. make a bed ; 10. carry a shopping bag or briefcase ; 11. carry a heavy object (> 4.54 kg) ; 12. change a lightbulb overhead ; 13. wash or blow dry your hair ; 14. wash your back ; 15. put on a pullover sweater ; 16. use a knife to cut food ; 17. recreational activities which require little effort (e.g., card playing, knitting, etc.) ; 18. recreational activities in which you take some force or impact through your arm, shoulder or hand (e.g., golf, hammering, tennis, etc.) ; 19. recreational activities in which you move your arm freely (e.g., playing Frisbee, badminton, etc.) ; 20. manage transportation needs (getting from one place to another) ; and 21. sexual activities.

## RESULTS

Six patients were being treated for hypertension (42.9%), four had a previous history of total knee arthroplasty (28.6%), four had a history of lumbar spine degenerative disk disease (28.6%), two had hip or knee osteoarthritis (14.3%), one had coronary artery disease (7.1%), and one had undergone mitral valve replacement (7.1%). Subject total DASH scores were  $15.6 \pm 12.1$ . Specific DASH item subject responses with 95% confidence intervals are presented in fig 1. Subject perceptions of greatest functional shoulder disability was with placing an object on an overhead shelf, doing heavy household chores, carrying a heavy object > 4.54 kg (10 lbs), recreational activities in which impact



**Fig. 2.** — SPADI item results. 1. washing your hair ? ; 2. washing your back ? ; 3. putting on an undershirt or pullover sweater ? ; 4. putting on a shirt that buttons down the front ? ; 5. putting on your pants ? ; 6. placing an object on a high shelf ? ; 7. carrying a heavy object of 4.54 kg (10 lbs) ? ; 8. removing something from your back pocket ?

forces are transmitted through the arm, shoulder or hand, and recreational activities in which the arm freely moves. The average SPADI disability score was  $15.7 \pm 16.3$ . Specific DASH item subject responses with 95% confidence intervals are presented in fig 2. Subject perceptions of greatest functional shoulder disability were observed for placing an object on a high shelf, carrying an object of 4.54 kg (10 lbs), and washing their back. Subscale scores for SF-36 are presented in fig 3 and are compared with the results of MacDermid *et al* (19), and with age-related normative values (33). All subjects who completed the surveys in addition to four of five individuals who declined to participate in the study stated that they were satisfied with the shoulder function and pain relief provided by the surgery and would undergo the procedure again if faced with a similar situation in their uninvolved shoulder (94.7%, 18 of 19). Gender differences were not observed for SPADI, DASH, or SF-36 survey scores with the exception of poorer general health among male subjects  $44.7 \pm 24.4$  vs. female subjects  $79.3 \pm 13.5$ , Mann Whitney U Statistic = 2,

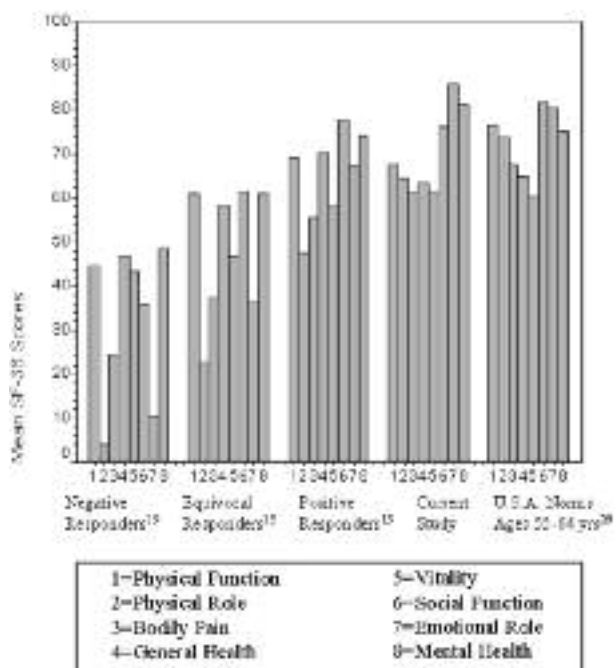


Fig. 3. — SF-36 results compared to those of MacDermid *et al* (19) and to age-related nonimpaired men and women (33).

$p = 0.005$ ). Component SF-36 scores did not display significant correlations with SPADI or DASH scores.

### DISCUSSION

Sundine and Malkani (30) examined 10 patients at one year after massive rotator cuff tear reconstruction using an interposition flap transfer of the long head of the triceps brachii muscle and reported significant UCLA Shoulder Score improvement. Independent review of patient outcomes at two years following this procedure by Keen *et al* (18) during the initial phase of this current study, reported reduced pain and improved shoulder function, however residual strength deficits in shoulder abduction and external rotation and elbow extension were evident. Patients had improved their pre-operative UCLA Shoulder Score by an average of 60%, however a detailed assessment of which specific tasks contributed to remaining shoulder functional disability was not performed (18).

Study findings for shoulder function following this surgical procedure compare favourably with other patient outcome reports following surgery for massive rotator cuff tears (19,23,29). At two years post-surgery the vast majority of patients were satisfied with shoulder function and pain relief and stated they would undergo the procedure again if faced with a similar situation in the uninvolved shoulder. Despite the massive rotator cuff tear size in our patients, the average post-operative DASH score was lower (less disability) than the average post-operative DASH score of  $21.6 \pm 13$  reported by Skutek *et al* (29), or for those reported as positive responders  $26.3 \pm 19$  by MacDermid *et al* (19). This finding is significant since all of the patients who participated in our study had massive ( $> 5 \text{ cm}^2$ ) rotator cuff tears while both Skutek *et al* (29) and MacDermid *et al* (19) had patient groups that included smaller tears in addition to massive tears. Moser *et al* (23) reported superior SPADI scores for patients who received complete massive rotator cuff tear repairs, however all were primary surgical procedures. Patients who received partial repairs in their study had lower SPADI scores than we report (23). Based on the self-reported shoulder function results we report use of the long head of the triceps brachii muscle as an interposition flap to reconstruct a massive rotator cuff tear appears to be an effective procedure. Although some disability remains, patients are largely satisfied with their level of shoulder function and are particularly satisfied with the shoulder pain reduction that they experience.

Like the latissimus dorsi tendon transfer reconstruction procedure for a massive, irreparable rotator cuff tear, triceps brachii muscle interposition flap transfer use provides excellent pain relief, and improved shoulder function. We agree with Costouros *et al* (8) regarding the variable functional results and poorly understood factors that are predictive of a good patient outcome. We also agree with Roddey *et al* (25) regarding the complexities of patient qualitative perceptions of shoulder function and satisfaction following rotator cuff surgery. Further electrophysiologic and clinical investigations are needed to definitively ascertain what capacity either autogenous latissimus dorsi tendon

transfer or triceps brachii muscle interposition flap transfer procedures have for restoring active shoulder external rotation and humeral head depression functions. To do this, a cooperative relationship is needed with rehabilitation personnel to develop appropriate neuromuscular training interventions with the specific purpose of teaching the transferred musculotendinous unit to function along its modified force vector line. Only with well-designed clinical studies using electromyographic, kinematic, and patient subjective measurements will we be able to verify if active contributions exist, and if they are functionally significant to the patient.

Before undergoing massive rotator cuff repair using a triceps brachii muscle interposition flap transfer patients should be advised as to the likelihood that they will continue to experience disability during overhead activities, lifting objects of  $\geq 4.54$  kg (10 lbs), quickly moving or taking impact through the upper extremity or performing more intense household chores. This information can be helpful for preoperative patient counselling regarding the likelihood of satisfaction with the procedure, and in surgical planning. For example, while a patient with a primary complaint of pain might be ideally suited to undergo this procedure, an individual who must perform overhead tasks or lift objects  $\geq 4.54$  kg (10 lbs) should be counselled to consider other options, or agree to modify behaviours and/or task requirements to enhance their chances of having a successful outcome.

This study has several limitations. Ideally, prospective DASH and SPADI scores would have been collected for direct comparison. Our conclusions are based on the assumption that the surgical intervention, its ensuing rehabilitation, and patient progressions with activities of daily living are what led to the post-operative DASH and SPADI scores that were observed. The fact that all of the patients who participated in our study had massive rotator cuff tears and most had experienced a primary repair failure prior to reconstructive surgery largely validates this assumption (20). Furthermore, our patients had DASH and SPADI score results that met or exceeded those reported by Skutek *et al* (29) and MacDermid *et al* (19) among patients with smaller rotator cuff tears, by Moser *et al* (23) among

patients who underwent partial primary repair of massive tears, and for age-related non-impaired subjects (33). The male subjects in our study had lower SF-36 general health scores than female subjects, however in a prospective, multi-center study, using the DASH and SPADI surveys Boissonnault *et al* (5) reported that the number of patient comorbidities although negatively influencing patient general health, did not relate to shoulder disability levels.

Massive rotator cuff tear reconstruction using the long head of the triceps brachii muscle provides good patient outcomes at two years post-surgery. However, shoulder functional disabilities related to overhead activities, carrying an object of  $\geq 4.54$  kg (10 lbs), washing the back, heavy household chores and recreational activities with upper extremity impact or free movement remain.

## REFERENCES

1. Audenaert E, Van Nuffel J, Schepens A *et al*. Reconstruction of massive rotator cuff lesions with a synthetic interposition graft: A prospective study of 41 patients. *Knee Surg Sports Traumatol Arthrosc* 2006; 14: 360-364.
2. Bateman JE. The diagnosis and treatment of ruptures of the rotator cuff. *Surg Clin North Am* 1963; 43: 1523-1530.
3. Bigliani LU, Cordasco FA, Mellveen SJ, Musso ES. Operative treatment of failed repairs of the rotator cuff. *J Bone Joint Surg* 1992; 74-A: 1505-1515.
4. Boes MT, McCann PD, Dines DM. Diagnosis and management of massive rotator cuff tears: The surgeon's dilemma. *Instr Course Lect* 2006; 5: 45-57.
5. Boissonnault WG, Badke MB, Wooden MJ *et al*. Patient outcome following rehabilitation for rotator cuff repair surgery: The impact of selected medical comorbidities. *J Orthop Sports Phys Ther* 2007; 37: 312-319.
6. Burkhart SS. Arthroscopic treatment of massive rotator cuff tears. *Clin Orthop* 2001; 390: 107-118.
7. Cofield RH. Rotator cuff disease of the shoulder. *J Bone Joint Surg* 1985; 67-A: 974-979.
8. Costouros JG, Espinosa N, Schmid MR, Gerber C. Teres minor integrity predicts outcome of latissimus dorsi tendon transfer for irreparable rotator cuff tears. *J Shoulder Elbow Surg* 2007; 16: 727-734.
9. Degreef I, Debeer P, VanHerck B *et al*. Treatment of irreparable rotator cuff tears by latissimus dorsi muscle transfer. *Acta Orthop Belg* 2005; 71: 667-671.
10. Gartsman GM. Massive, irreparable tears of the rotator cuff. Results of operative debridement and subacromial decompression. *J Bone Joint Surg* 1997; 79-A: 715-721.

11. **Gerber C.** Latissimus dorsi transfer for the treatment of irreparable tears of the rotator cuff. *Clin Orthop* 1992 ; 275 : 152-160.
12. **Gerber C, Maquieira G, Espinosa N.** Latissimus dorsi transfer for the treatment of irreparable rotator cuff tears. *J Bone Joint Surg* 2006 ; 88-A : 113-120.
13. **Gerber C, Vinh TS, Hertel R, Hess CW.** Latissimus dorsi transfer for the treatment of massive tears of the rotator cuff. *Clin Orthop* 1988 ; 232 : 51-61.
14. **Guven O, Bezer M, Guven Z et al.** Surgical technique and functional results of irreparable cuff tears reconstructed with the long head of the biceps tendon. *Bull Hosp Jt Dis* 2001 ; 60 : 13-17.
15. **Hartrampf CR Jr, Elliot LF, Feldman S.** A triceps musculocutaneous flap for chest-wall defects. *Plast Reconstr Surg* 1990 ; 86 : 502-509.
16. **Jost B, Puskas GJ, Lustenberger A, Gerber C.** Outcome of pectoralis major transfer for the treatment of irreparable subscapularis tears. *J Bone Joint Surg* 2003 ; 85-A : 1944-1951.
17. **Karas SE, Giachello TL.** Subscapularis transfer for reconstruction of massive tears of the rotator cuff. *J Bone Joint Surg* 1996 ; 78-A : 239-245.
18. **Keen J, Nyland J, Kocabey Y, Malkani AL.** Shoulder and elbow function 2 years following long head triceps interposition flap transfer for massive rotator cuff tear reconstruction. *Arch Orthop Trauma Surg* 2006 ; 126 : 471-479.
19. **MacDermid JC, Drosdowech D, Faber K.** Responsiveness of self-report scales in patients recovering from rotator cuff surgery. *J Shoulder Elbow Surg* 2006 ; 15 : 407-414.
20. **McCabe RA, Nicholas SJ, Montgomery KD et al.** The effect of rotator cuff tear size on shoulder strength and range of motion. *J Orthop Sports Phys Ther* 2005 ; 35 : 130-135.
21. **Mikasa M.** Trapezius transfer for global tear of the rotator cuff. In : Basmajian JE, Welsh RP (eds) *Surgery of the shoulder*. Decker, Philadelphia, 1984, pp 196-199.
22. **Miller DV, Hartrampf CR Jr, Namnoum JD.** Triceps myotendinous rotation flap for unrepairable rotator cuff tears : A preliminary report. In : Proceedings of the American Society for Shoulder and Elbow Surgeons, Specialty Day Meeting, San Francisco, 2001.
23. **Moser M, Jablonski MV, Horodyski M, Wright TW.** Functional outcome of surgically treated massive rotator cuff tears : A comparison of complete repair, partial repair, and debridement. *Orthopedics* 2007 ; 30 : 479-482.
24. **Neviaser RJ, Neviaser TJ.** Transfer of the subscapularis and teres minor for massive defects of the rotator cuff. In : Bayley JL, Kessel L. (eds). *Shoulder Surgery*, Springer, New York, 1982, pp 681-684.
25. **Roddey TS, Cook KF, O'Malley KJ, Gartsman GM.** The relationship among strength and mobility measures and self-report outcome scores in persons after rotator cuff repair surgery : Impairment measures are not enough. *J Shoulder Elbow Surg* 2005 ; 14 : 95S-98S.
26. **Roddey TS, Olson SL, Cook KF et al.** Comparison of the University of California-Los Angeles Shoulder Scale and the Simple Shoulder Test with the Shoulder Pain and Disability Index : Single-administration reliability and validity. *Phys Ther* 2000 ; 80 : 759-768.
27. **Ruotolo C, Nottage WM.** Surgical and nonsurgical management of rotator cuff tears. *Arthroscopy* 2002 ; 18 : 527-531.
28. **Sakurai G, Ozaki J, Tomita Y et al.** Incomplete tears of the subscapularis tendon associated with tears of the supraspinatus tendon : Cadaveric and clinical studies. *J Shoulder Elbow Surg* 1998 ; 7 : 510-515.
29. **Skutek M, Fremerey RW, Zeichen J, Bosch U.** Outcome analysis following open rotator cuff repair. Early effectiveness validated using four different shoulder assessment scales. *Arch Orthop Trauma Surg* 2000 ; 120 : 432-436.
30. **Sundine MJ, Malkani AL.** The use of the long head of triceps interposition muscle flap for treatment of massive rotator cuff tears. *Plast Reconstr Surg* 2002 ; 110 : 1266-1274.
31. **Tempelhof S, Rupp S, Seil R.** Age-related prevalence of rotator cuff in asymptomatic shoulders. *J Shoulder Elbow Surg* 1999 ; 8 : 296-299.
32. **Vandenbussche E, Bensaida M, Mutschler C et al.** Massive tears of the rotator cuff treated with a deltoid flap. *Int Orthop* 2004 ; 28 : 226-230.
33. **Ware JE, Snow KK, Kosinski M.** *SF-36® Health Survey Manual and Interpretation Guide*. Lincoln, RI : QualityMetric Incorporated, 2000.
34. **Werner CML, Zingg PO, Lie D et al.** The biomechanical role of subscapularis in latissimus dorsi transfer for the treatment of irreparable rotator cuff tears. *J Shoulder Elbow Surg* 2006 ; 15 : 736-742.