



Radial nerve entrapment in a humeral fracture callus

Sébastien HUGON, François DAUBRESSE, Luc DEPIERREUX

From Centre Hospitalier Régional de Namur, Namur, Belgium

A patient with a radial nerve palsy which persisted nine months after a diaphyseal fracture of the humerus was referred to our department. Radiographs and ultrasound examination showed that the radial nerve was transected and partially entrapped in the fracture callus. This double injury was confirmed and was repaired during subsequent surgical treatment. We report this rare case of combined primary and secondary nerve lesion.

Keywords : radial nerve ; humerus fracture ; callus ; radial palsy ; nerve graft.

INTRODUCTION

Fractures of the humeral shaft are frequently associated with radial nerve palsy. In most cases the nerve injury is a contusion, and it recovers spontaneously in as many as 80% of cases. Conservative management is therefore preferred, nevertheless in some patients recovery fails to occur and surgical exploration becomes necessary (3,7,9).

We report a rare presentation of this latter category.

CASE REPORT

A 27-year-old man was admitted to a surgical emergency department after a car accident. He was unconscious and was immediately intubated. The physical and radiological examination revealed a parietal subdural haematoma with slight frontal

contusion, a transverse diaphyseal fracture of the distal third of the right humerus, several mandible fractures and multiple wounds. Blood alcohol level was 2.52 g/L.

The humerus fracture was rapidly reduced and stabilised using unreamed retrograde nailing with an Ender nail, with an acceptable result (fig 1).

During the postoperative evolution, as the patient came out of coma, a right radial palsy was noticed and evaluated by means of electromyography (EMG). This testing revealed a severe peripheral motor and sensitive neuropathy with axonotmesis of the motor branch of the radial nerve under the elbow, with the triceps branch remaining intact. Conservative treatment including physiotherapy and B-multivitamin complex was initiated.

During the following months, clinical examination and EMG testing were repeated, but the

-
- Sébastien Hugon, MD, Resident in orthopaedic surgery.
 - François Daubresse, MD, Orthopaedic surgeon.
 - Luc Depierreux, MD, Orthopaedic surgeon.

Department of Orthopaedic Surgery, Hand and Microsurgery Unit, Centre Hospitalier Régional de Namur, Namur, Belgium.

Correspondence : Sébastien Hugon, Orthopaedic Surgery Department, Cliniques Universitaires Saint-Luc, Avenue Hippocrate, 10, B-1200 Bruxelles, Belgium.

E-mail : s.hugon@scarlet.be

© 2008, Acta Orthopædica Belgica.

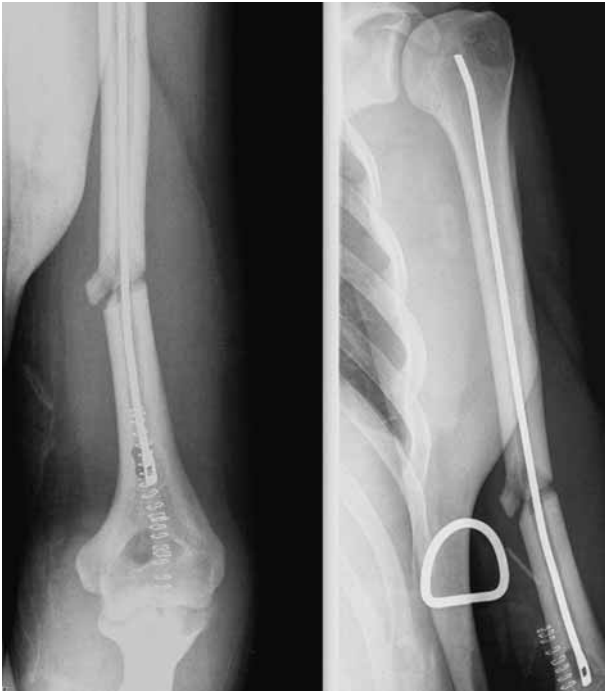

Fig. 1. — Radiograph showing the humeral fracture immediately after osteosynthesis with an Ender nail.

denervation signs remained unchanged. The motor response obtained from the extensor indicis proprius when stimulating the retro-humeral right radial nerve was too weak to be measured, while more distal stimulation showed highly reduced amplitude ($0.5 \mu\text{V}$) with lengthened terminal latency. Anaesthesia in the radial nerve area remained complete after nine months.

The patient was then referred to our department. Further conventional radiographs were obtained, showing good fracture healing but with an unusual callus: its posterolateral part appeared ring-shaped, as if surrounding some soft tissue which could be the radial nerve (fig 2). Ultrasonography (US) could not spot the radial nerve against the scar, but revealed a hypoechogenic thickened nerve on both sides of this region, compatible with a traumatic nerve tear.

Surgical exploration was then decided with the patient. A posterolateral approach was used, and the radial nerve was found in its expected location above the elbow, between the brachialis and the brachioradialis. While following its course up to

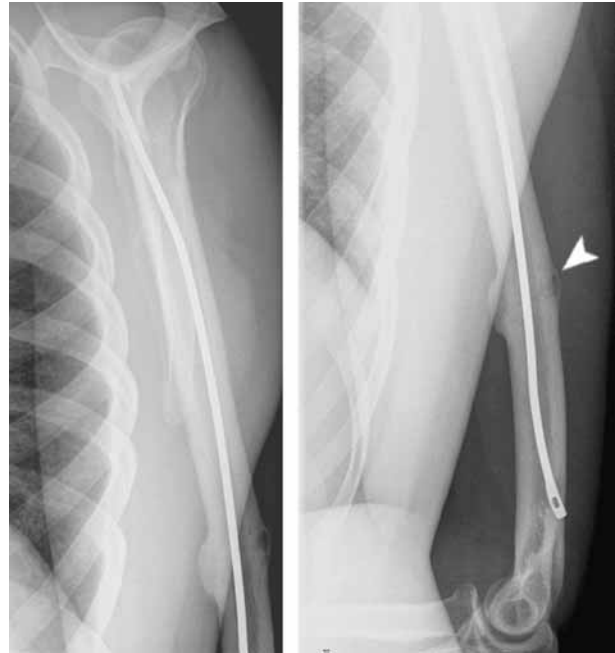


Fig. 2. — Radiographic findings at nine months: The osseous tunnel through the callus is apparent on both frontal and lateral views.

the spiral groove it appeared caught in a fibrous tissue, and tedious dissection was necessary. Half of the distal nerve was found to emerge from a bony tunnel, while the other part of the torn nerve laid in the surrounding fibrous scar. The proximal nerve extremity disappeared entirely in the opposite side of the bony tunnel. Breaking down this bone conduit disclosed a neuroma joining the two nerve ends. The bony callus had thus grown through the nerve fascicles previously torn by the fractured bone, enclosing half of them, which accounted for the image seen on the preoperative radiograph as well as the clinical symptoms (fig 3).

We had to resect five centimeters of neuroma, and bridged the defect with a four-strand sural nerve graft, using the Narakas technique (fig 4).

One month after operation, after discussion with the patient, we performed a triple tendon transfer (pronator teres on the extensor carpi radialis brevis, flexor carpi radialis on the extensor digitorum communis, palmaris longus on the extensor pollicis longus) in order to restore wrist and fingers extension.

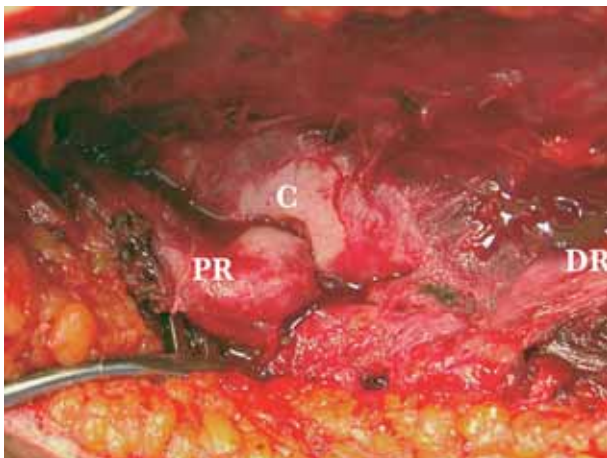


Fig. 3. — Intraoperative view. C, callus ; PR, proximal radial nerve, entering the osseous tunnel ; DR, distal radial nerve, torn in two proximal parts, one coming from the tunnel and one included in the peripheral scar tissue.

The patient has now regained a functional range of motion, and EMG shows progressive yet incomplete nerve regrowth.

DISCUSSION

Although this is most commonly the case for spiral fractures of the middle and distal third of the humerus, transverse or oblique fracture patterns may also be associated with radial neuropathy (3,7,12). The nerve lesion mechanism is manifold, and nerve entrapment between the bony fragments is a well-known possibility (1,2,4,7,9,11,13). However, as the rate of spontaneous recovery is high, surgical exploration is usually suggested three to six months after trauma, except for open fractures or paralysis secondary to fracture reduction (3,7,9). In our patient, this last point could not be stated since he was comatous and impregnated with alcohol, therefore the lesion was assumed to be primary, considering the statistically higher probability. Moreover, Ender nailing is considered a reliable osteosynthesis procedure, with a low risk of iatrogenic injury if the nerve has not previously been trapped in the medullary canal (3,6,10,13).

The value of US examination is high in the preoperative evaluation, as EMG gives no information regarding the integrity of the nerve or the lesion

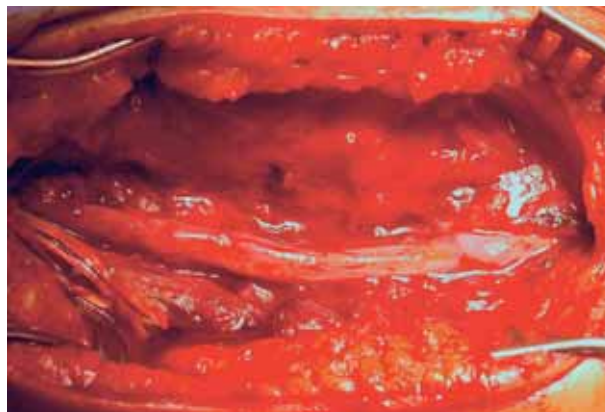


Fig. 4. — Intraoperative view : The four-strand sural nerve graft put into place.

mechanism in the acute phase (2,8). The nerve tear image was actually confirmed in this patient, though the study was impaired by established scar tissue. The x-ray images provided with the second half of the diagnosis, and could establish that the nerve was not caught between the fracture ends.

Duthie (4) and Symeonides *et al* (11) already described a radiologically identifiable radial nerve entrapment in a humeral fracture callus, the latter without any clinical manifestation. Others (1,2,5,7) have reported progressive palsy due to nerve compression or attrition by the callus, but the combined lesion described here, associated with a transverse fracture, does not appear to have been previously reported.

Although it is usually not recommended to perform tendon transfers before one year if the nerve function is expected to recover (3,9), in this case the graft length, the section level, and the excessive time passed since the initial trauma incited us to consider these transfers earlier.

REFERENCES

1. Amillo S, Barrios RH, Martinez-Peric R, Losada JI. Surgical treatment of the radial nerve lesions associated with fractures of the humerus. *J Orthop Trauma* 1993 ; 7 : 211-215.

2. **Bodner G, Buchberger W, Schocke M et al.** Radial nerve palsy associated with humeral shaft fracture : evaluation with US - initial experience. *Radiology* 2001 ; 219 : 811-816.
3. **DeFranco MJ, Lawton JN.** Radial nerve injuries associated with humeral fractures. *J Hand Surg* 2006 ; 31-A : 655-663.
4. **Duthie HL.** Radial nerve in osseous tunnel at humeral fracture site diagnosed radiographically. *J Bone Joint Surg* 1957 ; 39-B : 746-747.
5. **Edwards P, Kurth L.** Postoperative radial nerve paralysis caused by fracture callus. *J Orthop Trauma* 1992 ; 6 : 234-236.
6. **Moon MS, Moon YW, Kim SS et al.** Treatment of fracture of shaft of humerus by Ender nailing : a report of 43 cases. *J Orthop Surg* 1998 ; 6 : 9-15.
7. **Pollock FH, Drake D, Bovill EG et al.** Treatment of radial neuropathy associated with fractures of the humerus. *J Bone Joint Surg* 1981 ; 63-A : 239-243.
8. **Robinson LR.** Traumatic injury to peripheral nerves. *Muscle Nerve* 2000 ; 23 : 863-873.
9. **Shah JJ, Bhatti NA.** Radial paralysis associated with fractures of the humerus. A review of 62 cases. *Clin Orthop* 1983 ; 172 : 171-176.
10. **Shazar N, Brumback RJ, Vanco B.** Treatment of humeral fractures by closed reduction and retrograde intramedullary Ender nails. *Orthopedics* 1998 ; 21 : 641-646.
11. **Symeonides PP, Paschaloglou C, Pagalides T.** Radial nerve enclosed in the callus of a supracondylar fracture. *J Bone Joint Surg* 1975 ; 57-B : 523-524.
12. **Takami H, Takahashi S, Ando M.** Severance of the radial nerve complicating transverse fracture of the mid-shaft of the humerus. *Arch Orthop Trauma Surg* 1999 ; 119 : 109-111.
13. **Yang KH, Han DY, Kim HJ.** Intramedullary entrapment of the radial nerve associated with humeral shaft fracture. *J Orthop Trauma* 1997 ; 11 : 224-226.