



## Primary sacral hydatid cyst. A case report

Nayana JOSHI, Alejandro HERNANDEZ-MARTINEZ, Roberto SEIJAS-VAZQUEZ

*From the Hospital Universitari Vall d'Hebron, Barcelona, Spain*

**This case report highlights an unusual osseous spinal presentation of a well described disease, hydatidosis.**

**A 59-year-old woman presented with increasing back pain and bilateral radiculopathy. Examination disclosed symptoms of spinal stenosis and urinary incontinence. Radiographs showed an expansive lytic lesion affecting the pelvic bones with destruction of the bone cortex. Laboratory analyses were performed and the patient underwent CT and MRI studies. Serology for Echinococcus was positive.**

**When assessing sciatica, low back pain or lower limb weakness the pelvic cavity should be examined for hidden disease that might explain the neurological symptoms.**

**Hydatid disease of bone should be considered in the differential diagnosis of any bone mass discovered in the human body. Diagnosis was delayed in this case because the pelvic cavity was not studied when radiculopathy symptoms started and there was no coexisting visceral involvement.**

**Keywords :** hydatid disease ; echinococcosis ; sacrum.

The parasite requires two hosts in its life cycle : a definitive host (usually a dog) and an intermediate host (e.g. humans). Humans are infected by direct contact with an infected dog or by ingestion of contaminated food. Echinococcal embryos migrate through the intestinal mucosa, enter intestinal venules and lymphatics, and reach the liver in 60% to 70% of cases. If the embryos bypass the liver, they enter the systemic circulation and are carried by the bloodstream to any organ or tissue in the body. A hydatid cyst of bone is always a primary disease. The frequency of bone involvement is 0.5% to 4%, and the spine is affected in 50% of patients with hydatid disease of the bone.

### CASE REPORT

A 59-year-old woman, who had been treated conservatively for more than 12 years for right sciatica secondary to lateral lumbosacral disc

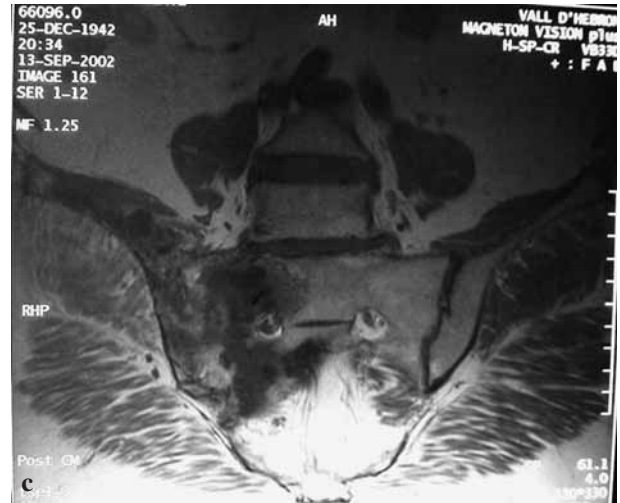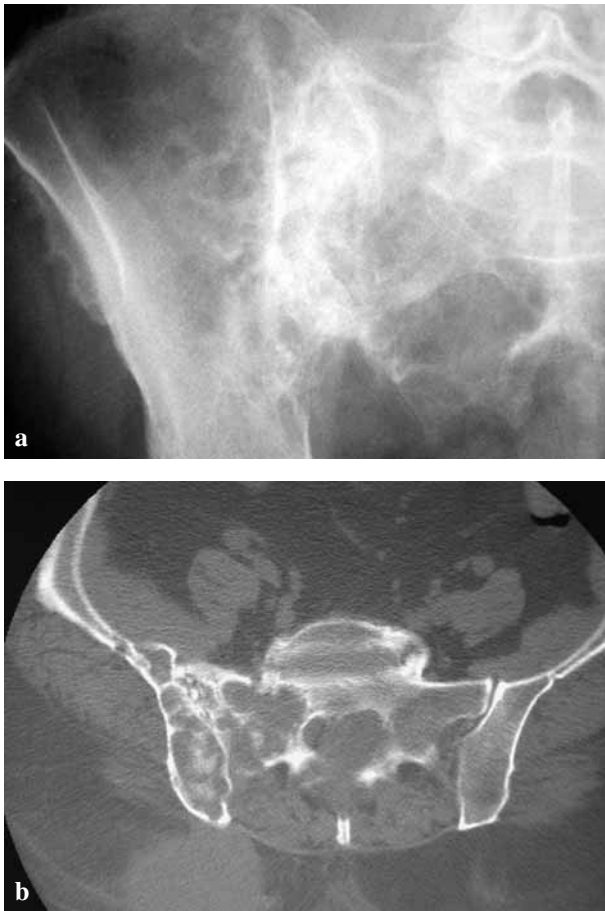
### INTRODUCTION

Hydatid disease is a parasitic infestation caused by larvae of the tapeworm *Echinococcus*. *Echinococcus granulosus* is the species that most commonly infects humans. The infestation is prevalent in most parts of the world, especially in sheep farming and cattle farming areas of the Mediterranean Sea, Asia, North and East Africa, South America, Australia, and the Middle East.

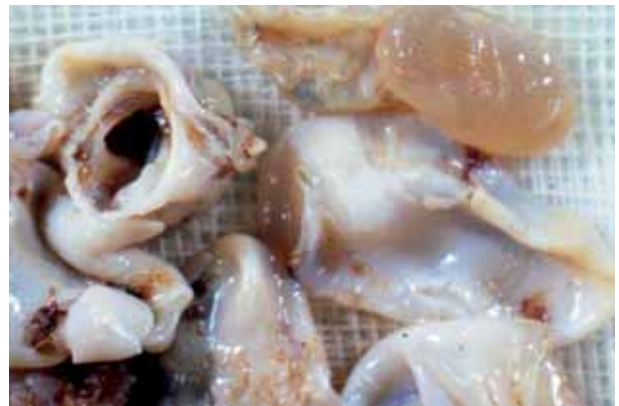---

■ Nayana Joshi, MD, PhD, Orthopaedic Surgeon.  
■ Alejandro Hernández-Martínez, MD, Orthopaedic Surgeon.  
■ Roberto Seijas-Vázquez, MD, Orthopaedic Surgeon.  
*Hospital Universitari Vall d'Hebron, Departament de Cirurgia Ortopèdica y Traumatologia., Barcelona, Spain.*  
Correspondence : N. Joshi, Sagués 47, 1-2, 08021 Barcelona, Spain. E-mail : njoshijubert@gmail.com.  
© 2007, Acta Orthopædica Belgica.

---



**Fig. 1.** — a) Plain radiograph of the pelvis showing lytic lesions ; b) CT images demonstrate hydatid cysts, bone erosion affecting the iliac wing, and sacral destruction ; and c) MR T2-weighted image shows a hypointense rim at the periphery of the cyst, corresponding to a fibrous reactive capsule known as the pericyst. On MRI, hydatid cysts are usually visualized as spherical lesions that are hypointense on T1- and hyperintense on T2-weighted images.



**Fig. 2.** — Photograph of the resected hydatid mass

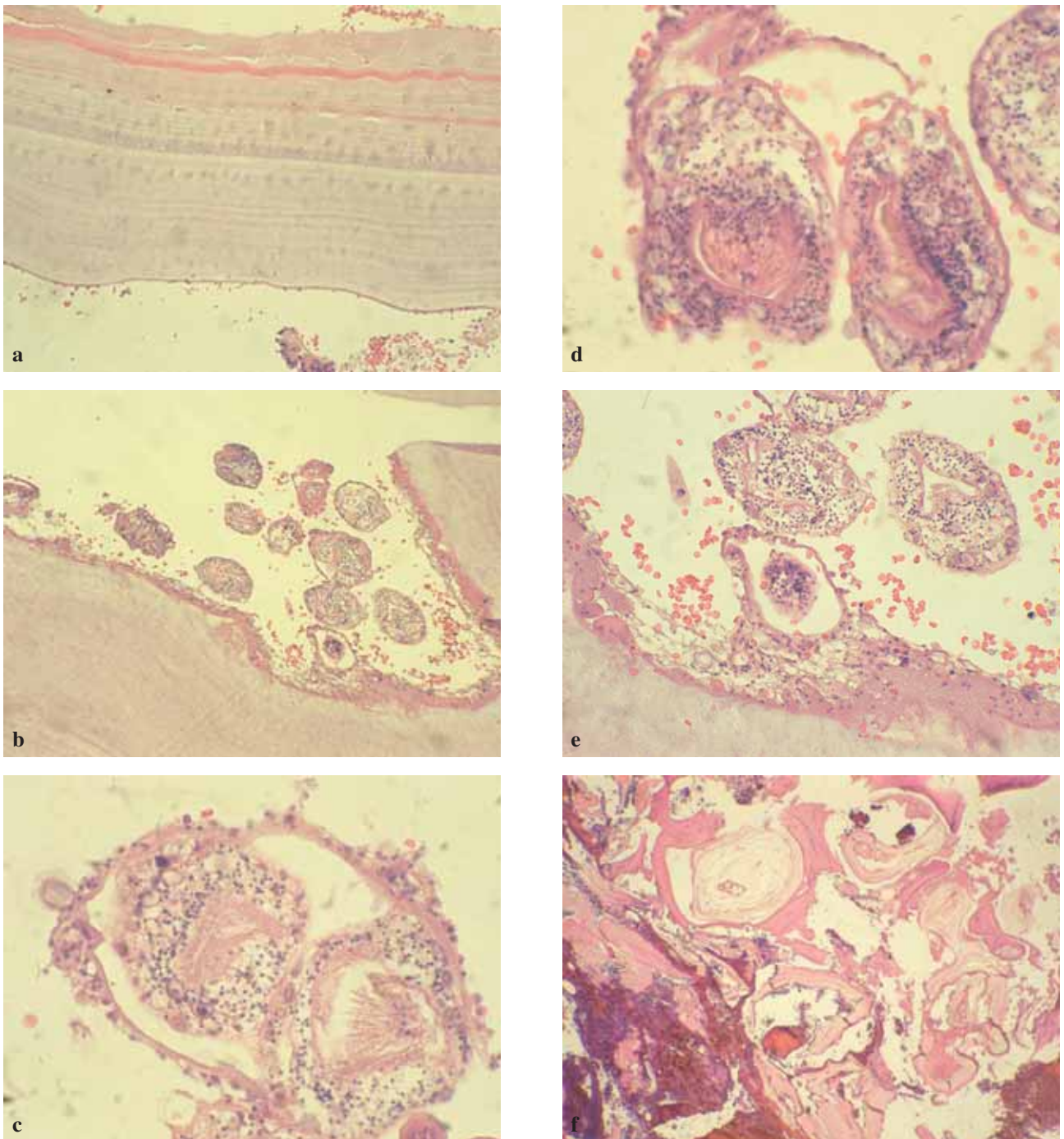
herniation, was admitted to the hospital with increasing back pain and bilateral radiculopathy.

Examination disclosed symptoms of spinal stenosis and urinary incontinence. A slow-growing mass was suspected. Laboratory analyses were performed and the patient underwent radiographs and CT and MRI studies to establish the differential diagnosis between a tumour mass and infectious disease. Radiographs showed an expansile lytic lesion affecting the right iliac wing and the sacrum with cortical bone destruction. The lumbar CT scan showed L5-S1 disc herniation. Pelvic CT was required to visualize a well-localized cystic swelling in the right pelvis over the lumbosacral plexus roots. MRI revealed neural involvement, sacral destruction and replacement by a multiloculated cystic mass, which also occupied the spinal canal (fig 1 a, b, & c). Serology for Echinococcus

was positive. Cranial and thoracoabdominal CT study showed no other coexisting lesions.

Albendazole treatment was started prior to surgical removal of the cyst. The patient underwent excision of the multiloculated cystic mass and hydatid vesicles.

Macroscopic examination of the surgical specimen showed a hydatid cyst containing clear fluid and daughter cysts (fig 2) ; the cuticular layer of the cyst wall was evident.



**Fig. 3.** — Histological examination : a) acellular layer ; b) and c) germinal layer containing daughter cysts ; d) and e), the scolices ; and f) fibrous, hyalinized tissue surrounding multiple small cysts and areas of bone necrosis.

Histological examination showed the acellular layer (fig 3a), the germinal layer containing daughter cysts (fig 3b & 3c) and the scolices (fig 3d &

3e). Abundant fibrous and hyalinized tissue surrounding multiple small cysts and areas of bone death and necrosis were observed (fig 3f).

After surgical and medical treatment, the patient was neurologically normal and had less pain. There were no sequelae and no evidence of recurrence or clinically relevant side effects. At 20 months' follow-up, there were no signs of recurrence.

## DISCUSSION

Although hydatid disease of bone is rare, it should be included in the differential diagnosis of any bone mass discovered in the human body.

Diagnosis was delayed in the reported case because the pelvic cavity was not studied when radiculopathy symptoms started and there was no coexisting visceral involvement.

In endemic areas the incidence of bone hydatid infections is 0.5%-4%. When the bone is affected, multiple slow-growing vesicles proliferate along the medullary canal, replacing trabecular bone, but not forming encapsulated cysts as occurs in other organs (8). For this reason diagnosis may be delayed. With time, the parasite may destroy the cortical bone and protrude into adjacent soft tissue (11,12). Clinical symptoms depend on the location of the disease, and neurological recovery is possible because it is a slow-growing lesion. The anaphylactic shock caused by human hypersensitivity to hydatid vesicles has not been described in hydatid disease of the spine, since the process extends into the spinal canal, instead of forming large cysts (6). Anaphylactic shock mostly occurs when large cysts break up and the antigen spreads through the vessels. Extrapelvic hydatidosis may lead to spinal cord compression by extension through the intervertebral foramen (5,9).

Surgical excision remains the treatment of choice (4), but high rates of postoperative recurrence have highlighted the importance of adjuvant antihelminthic therapy (2,3,7,8). The selection of the drug(s) and the duration of medical treatment are still controversial.

When assessing sciatica, low back pain or lower limb weakness, and after peripheral lesions and lumbar spine disc herniation have been excluded, the pelvic cavity should be examined for hidden disease that might explain the neurological symptoms (1,10).

Surgery is required in the treatment of spinal hydatid disease in order to attain neurological recovery after surgical decompression. Prolonged albendazole treatment appears to be safe and effective in the prevention of late recurrences after spine hydatidosis surgery. Long-term chemotherapy should be the standard after surgical excision of lesions in the spine or other bone locations.

## REFERENCES

1. Basak M, Ozel A, Yildirim O, Erturk M. Relapsing hydatid disease involving the vertebral body and paravertebral soft tissues. *Acta Radiol* 2002 ; 43 : 192-193.
2. Diedrich O, Kraft CN, Zhou H, Sommer T, Perlick L, Schmitt O. [Orthopedic aspects of osseous echinococcosis – radiologic diagnosis, current surgery and drug therapy aspects.] (German). *Z Orthop Ihre Grenzgeb* 2001 ; 139 : 261-266.
3. Duran H, Mata P, Brandau D, Sanchez-Barba A. Osseous hydatidosis. *J Bone J Surg* 1978 ; 60-A : 685-690.
4. García-Vicuña R, Carvajal I, Ortiz-García A, López-Robledillo JC, Laffón A, Sabando P. Primary solitary echinococcosis in cervical spine. Postsurgical successful outcome after long term Albendazole treatment. *Spine* 2000 ; 25 : 520-523.
5. Hassan FO, Shannak A. Primary pelvic hydatid cyst : an unusual cause of sciatica and foot drop. *Spine* 2001 ; 26 : 230-232.
6. Marcos F, Turabian JL, Caballero F *et al.* [Allergic reactions-anaphylactic shock as a manifestation of liver hydatid disease] (Spanish). *Rev Clin Esp* 1984 ; 173 : 49-51.
7. Martínez AA, Herrera A, Cuenca J, Herrero L. Hydatidosis of the pelvis and hip. *Int Orthop* 2001 ; 25 : 302-304.
8. Mensa J. Infecciones por cestodos. In : Ferreras-Rozman (ed). *Medicina Clínica*. Mosby-Doyma, Madrid, 1999, pp 2472-2473.
9. Navarro G. [Recurrent and progressive paraplegia due to a D1-D9 multiple extradural hydatidosis, operated six times.] (Spanish). *Rev Clin Esp* 1972 ; 125 : 461-464.
10. Pasaoglu E, Damgaci L, Tokoglu F, Boyacigil S, Yuksel E. Vertebral hydatid disease. *Australas Radiol* 1997 ; 41 : 188-189.
11. Pedrosa I, Saiz A, Arrazola J, Ferreiros J, Pedrosa CS. Hydatid disease : radiologic and pathologic features and complications. *Radiographics* 2000 ; 20 : 795-817.
12. Yildiz Y, Bayrakci K, Altay M, Saglik Y. The use of polymethylmethacrylate in the management of hydatid disease of bone. *J Bone Joint Surg* 2001 ; 83-B : 1005-1008.