

## CASE REPORT

# INTRAPELVIC MASS IN A YOUNG WOMAN WITH AN UNCEMENTED HIP ARTHROPLASTY

S. OLESEN SCHAARUP, J.-E. VARMARKEN

**Based on a case report in which wear of the polyethylene liner in an uncemented hip prosthesis led to the development of an intrapelvic mass, the pathogenesis, diagnosis and treatment are described. Characteristic osseous and soft tissue reactions caused by release of polyethylene particles to periarticular tissue are discussed as well as the differential diagnosis with infectious and malignant conditions. In the case treated, the differential diagnosis was also made with respect to gynecological pathology.**

**Keywords :** total hip arthroplasty ; polyethylene wear ; intrapelvic mass.

**Mots-clés :** prothèse totale de hanche ; usure du polyéthylène ; masse intra-pelvienne.

---

### CASE REPORT

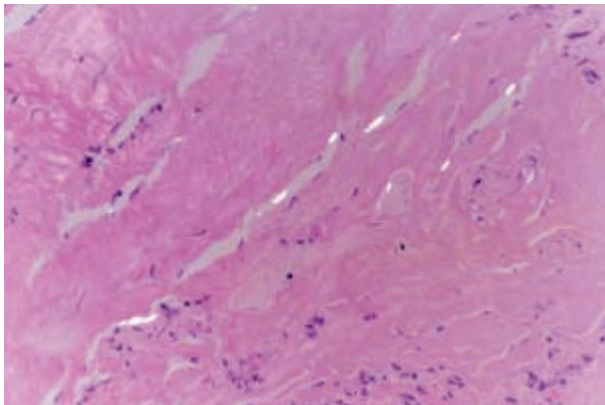
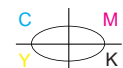
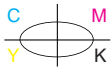
A 24-year-old woman had undergone a left uncemented total hip arthroplasty in 1986 because of posttraumatic avascular necrosis of the femoral head. She was well until December 1998, but she then experienced dyspareunia and felt a mass in her lower left abdomen. The general practitioner found an elastic tumor adherent to the pelvic wall, and observed weight loss approximately 10 kg in 3 months. A malignant tumor was suspected, and the patient was admitted to the orthopedic department. Xrays of hip and pelvis were considered normal. A gynecological origin was not to be excluded, and the patient was referred to the gynecologists. Investigations included clinical gynecological examination, transvaginal ultrasound and CT scan, as well as an abdominal ultrasound. All revealed a

well-defined cystic process with a diameter of 5 to 6 cm, without visible bony involvement and not connected to the ovary. Ultrasonographically the process showed only low signals. It was thought to be an ovarian cyst, possibly a dermoid cyst. Chest xray and laboratory examinations were normal, and an exploratory laparotomy was then performed. The internal genital organs were found to be normal, while a smooth retroperitoneal noninfiltrating cystic mass with a diameter of 5 to 6 cm was found adherent to the left pelvic wall. The mass was close to the iliac vessels and nerves. The cyst contained a light yellowish odorless fluid and a few visible polyethylene fragments. In the bottom of the cyst, the thread of the metal socket was palpable. It became clear that the uncemented hip arthroplasty was the origin of the mass. No bacterial growth was seen on culture of the fluid. Histological examination of the cyst wall showed fibrosis with marked chronic inflammation, lymphocytic infiltration, histiocytes, foreign body giant cells. An unusually large number of macrophages was seen between the collagen bundles. Small, characteristically needle-shaped birefringent particles were seen. The cyst was left open and covered with peritoneum. Review of the radiographs showed wear of the polyethylene liner and a small cavitary acetabular osteolysis. A revision hip arthroplasty was planned.

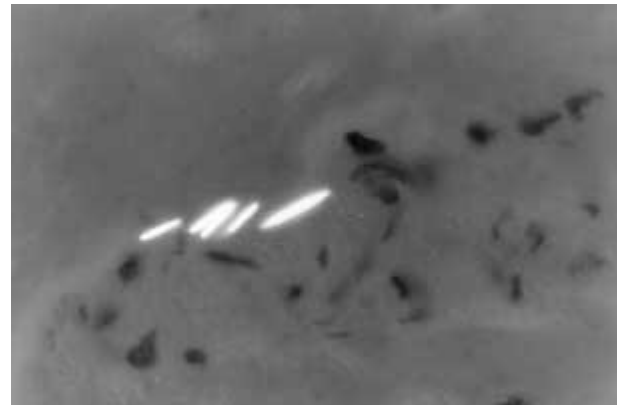
---

Department of Orthopaedic Surgery, Centralsygehuset Naestved, Ringstedgade, 4700 Naestved, Denmark.

Correspondence and reprints : Jens-Erik Varmarken, Centralsygehuset Naestved, Department of Orthopedics, Ringstedgade, 4700 Naestved, Denmark.



**Fig. 1.** — Histological appearance of cyst wall tissue taken at the laparotomy. Note the polyethylene wear debris seen as small birefringent particles between the collagen fibers. H & E stain, polarized light microscopy, magnification  $\times 200$ .



**Fig. 2.** — Same tissue sample at higher magnification  $\times 400$ . Note the needle-shape of the polyethylene particles, which measure from 7 to 14 microns.

During the operation we found excessive fibrosis around the joint and moderate metallosis. Although radiologically there was a suspicion of cup loosening, this was not confirmed, but the polyethylene liner was extensively worn.

In the lower anterior quadrant of the acetabulum we found a small osteolytic lesion with no marked communication with the intrapelvic space. At the anterior rim of the acetabulum we found cystic tissue as the cyst evidently had originated from there. The acetabular component and head were replaced, and the granulomatous periarticular tissue was excised and elicited the same needle-shaped birefringent particles as mentioned above.

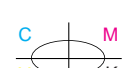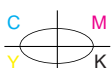
The primary prosthetic components were manufactured by Biomet-Merck Inc. The titanium socket was threaded on its outer hemisphere with an outer diameter of 48 mm and a hole in the bottom. Only a small part of the outside hemisphere was porous-coated. The liner was cylindrical in shape inside the cup with the hex-lock mechanism, and the thickness of the polyethylene was 8 mm. The head was 28 mm in diameter and made of chromium-cobalt. The femoral component was a collared Bi-Metric porous-coated stem made of titanium alloy. Both prosthetic components were uncemented. The femoral stem was not loose and was not changed during the revision operation.

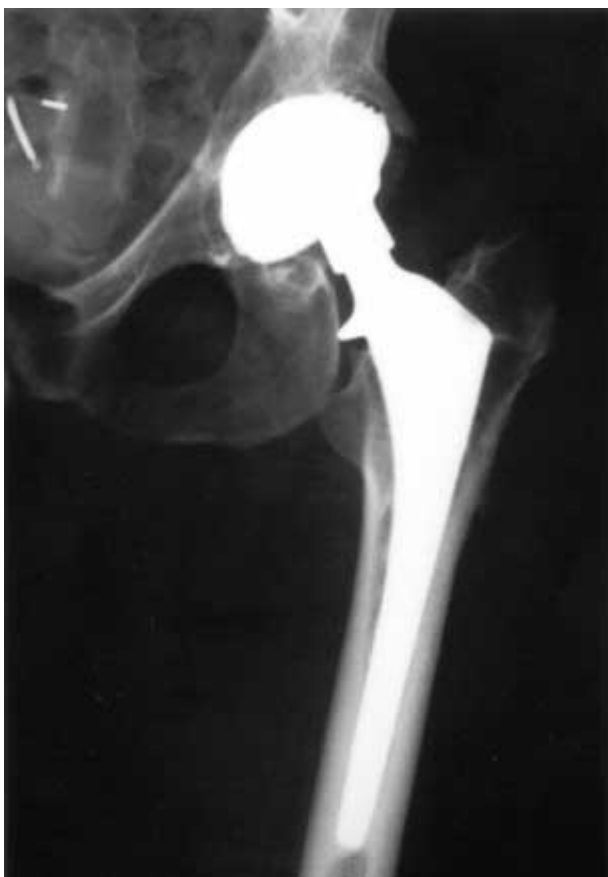The acetabular cup was exchanged with an uncemented hemispheric Trilogy cup (Zimmer) with

a ring-lock mechanism for the polyethylene liner. Osteolytic lesions were grafted with frozen bank bone. The head was also replaced with another of the same diameter, but a longer neck length to stabilize the joint.

## DISCUSSION

Excessive wear of polyethylene in THR has been well described (1, 3-5, 7, 9) especially in old prosthesis designs with nonspherical acetabular components and poor locking mechanisms between liner and metal (1). Younger patients with high activity levels are also more susceptible. In several investigations, release of polyethylene wear debris to the surrounding tissues has been shown to cause localized osteolysis (1, 3-5, 9, 12) and foreign body reactions like fibrosis, granulomas and cystic alterations, which are characterized histologically by chronic inflammation, lymphocytic infiltration and especially histiocytes, macrophages and foreign body giant cells (4, 7, 9, 12). The polyethylene particles are localized both intra- and extracellularly and are only visible in polarized light as birefringent needle-shaped particles (figs. 1, 2). With the plain light microscope and H & E stain they look like amorphous ground substance (9). Polyethylene wear-related tissue reactions have been described in both cemented (7, 9) and uncemented (1, 3, 5, 9, 12) hip arthroplasties. These phenomena are often

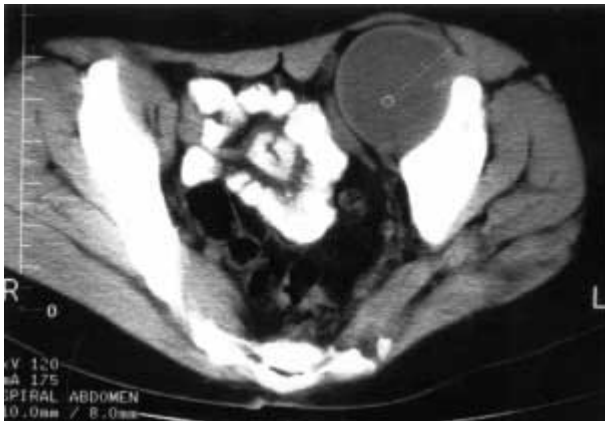



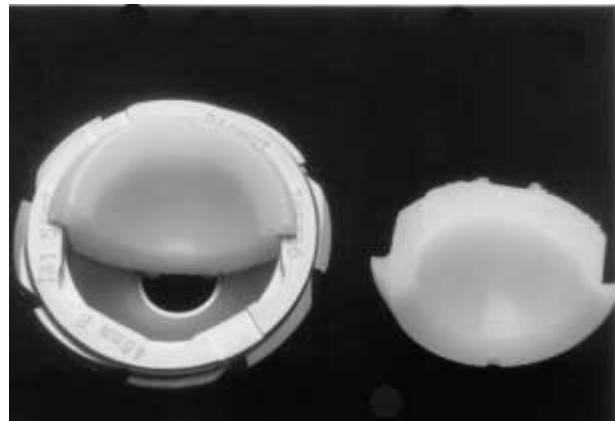
**Fig. 3.** — X-ray of the patient's left hip taken at hospital admission, which shows typical eccentricity of the head within the acetabular component. Small cavitary osteolytic lesions are seen at the anterior inferior acetabular rim and the calcar aspect of the femoral component.

primarily related to the acetabular component and to a lesser extent to the calcar part of the femoral component (1, 3, 5, 9). This has been noted as early as 12 months after implantation, but usually starts after 4 to 6 years. A radiological sign of polyethylene liner wear is the eccentric position of the prosthetic head within the acetabular component on the AP view (9) (fig. 3). Occasionally visible osteolysis is related to direct osseous contact with polyethylene particles. It is related to wear of the acetabular liner and is initiated at the periphery of the prosthetic components. Osteolysis, which is visible as linear or cavitary radiolucencies around the prosthesis is generally pain free (1). In this linear type of osteolysis the outer cortex characteristi-

cally remains intact (9, 10). This is important with respect to differential diagnoses such as postoperative infection or malignant tumors, as the latter have been observed in several cases with possible links to implants (2, 10). Early or rapid progression of painful osteolysis, especially when situated primarily around the femoral component and involving the outer cortex, should raise suspicion of infection or alternatively of a malignant tumor. Malignant mesenchymal tumors often have an extensive soft tissue component (2) resulting in a mass, a feature that can also be found in case of infection or polyethylene release to periarticular tissue. The tissue reactions to polyethylene have in some cases delayed diagnosis of malignancy (10). Polyethylene-wear tissue reactions around hip arthroplasties have in a few cases presented as an intrapelvic mass based on the inner pelvic wall (4, 7, 12). This process is described as developing through an osteolytic defect of varying size in the anterior part of the acetabulum, or along a partly eroded acetabular rim and developing deep to the iliac muscle. In this case the intrapelvic location of the tumor was an important differential diagnostic problem with respect to a gynecological tumor, which has not been discussed previously. Though proven to be optimal in visualizing ovarian pathology ultrasound was in this case unable to detect the origin of the tumor, so a CT-scan was added (fig. 4), owing to its superiority in visualizing retroperitoneal processes and their origins (8, 11). Only in specific cases when a bone tumor is suspected can MRI provide more information (6). Occasionally the final diagnosis can only be confirmed by laparotomy (8). Additional diagnostic tools are ultrasound-guided aspiration or biopsy (2, 11) and arthrography with or without CT-scan (7). A bone scintigram can provide important information about malignancy and loosening of the implant. If the differential diagnosis is an infectious condition in relation to the prosthesis, a supplementary leucocyte scintigram might be carried out (10). Where a polyethylene-wear-related condition is confirmed, limited wear and a symptom-free patient, it is wise to watch and wait. (3). Radiological follow-up of such patients, especially those with un cemented prostheses, should take place at relatively



**Fig. 4.** — Pelvic CT-scan of the patient showing the pelvic mass in close relation to the pelvic wall but also to the internal female genitals. Disturbance of the picture caused by the metal components of the implant made it impossible to continue the scan distally and thereby visualize any further relation between the mass and the arthroplasty.



**Fig. 5.** — Photograph showing a similar cup as the one removed at the revision operation. The liner is cut in two pieces, showing the polyethylene thickness at 8 mm in the bottom of the cup. The outer diameter of the cup is 48 mm. Note the hole in the bottom and the threaded outer hemisphere.

short intervals over long periods (5). In patients with more extensive osteolysis and eccentricity of the head with or without signs of loosening, the treatment is revision arthroplasty. The arthroplasty will include an exchange of at least the acetabular component and the head, as well as removal of granulomatous tissue and allograft filling of the osteolytic defects. Patients without pain should also undergo revision to avoid excessive osteolytic bone loss (3-5, 12). In some patients an intrapelvic mass can be removed through the exposure used for the revision arthroplasty (12), whereas in other cases a transabdominal exposure is necessary (4, 7).

#### *Acknowledgements*

We are very thankful to Dr. Lise Grupe Larsen, Department of Pathology Centralsygehuset Naestved, for her work making the histological preparations.

Thanks to Lillian and Daniel Tobin for their excellent work with the language in this manuscript.

#### **REFERENCES**

1. Dowdy P. A., Rorabeck C. H., Bourne R. B. Uncemented hip arthroplasty in patients 50 years or younger. *J. Arthroplasty*, 1997, 12, 853-862.
2. Jacobs J. J., Rosenbaum D. H., Marshall Hay R., Gitelis S., Black J. Early sarcomatous degeneration near a cementless hip replacement. *J. Bone Joint Surg.*, 1992, 74-B.
3. Kavanagh B.F., Callaghan J., Leggon R. *et al.* Pelvic osteolysis associated with an uncemented acetabular component in total hip arthroplasty. *Orthopaedics*, 1996, 19, 159-163.
4. Korkala O., Syrjanen K.J. Intrapelvic cyst formation after hip arthroplasty with a carbon fiber reinforced polyethylene socket. *Arch. Orthop. Trauma Surg.*, 1998, 118, 113-115.
5. Krugluger J., Eyb R. Bone reaction to uncemented threaded polyethylene acetabular components. *Int. Orthop.*, 1993, 17, 259-265.
6. Mäurer J., Österreich F.U., Grabbe E. Computertomografie und Kernspintomografie bei Beckentumoren ohne Organzusammenhang. *Röntgenblätter*, 1990, 43, 420-425.
7. Reigstad A., Røkkum M. An intrapelvic granuloma induced by acetabular cup loosening. *Acta Orthop. Scand.*, 1992, 63, 465-466.
8. Reuter K. L., D'Orsi C. J., Raptopoulos V., Evers K. Imaging of questionable and unusual pelvic masses. *Br. J. Radiol.*, 1986, 59, 765-771.
9. Schmalzried T. P., Jasty M., Harris W. H. Periprosthetic bone loss in total hip arthroplasty. Polyethylene wear debris and the concept of effective joint space. *J. Bone Joint Surg.*, 1992, 74-A, 849-863.
10. Schmidt A. H., Walker G., Kyle R. F., Thompson R. C. Periprosthetic metastatic carcinoma. Pitfalls in the management of two cases initially diagnosed as osteolysis. *J. Arthroplasty*, 1996, 11, 613-620.

11. Schmidt-Matthiesen A., Schmidt-Matthiesen H. Differenzierung zwischen gynäkologischer und chirurgischer Genese bei pathologischer Unterbauchsresistenzen. Geburtshilfe Frauenheilkd., 1993, 53, 379-383.
12. Wang J. W., Lin C. C. Pelvic mass caused by polyethylene wear after uncemented total hip arthroplasty. J. Arthroplasty, 1996, 11, 626-629.

### SAMENVATTING

*S. OLESEN SCHAARUP, J. E. VARMARKEN. Massa in het bekken van een jonge vrouw met een gecementeerde heup. Gevalstudie.*

Naar aanleiding van een persoonlijk geval, worden de pathogenesis, de diagnosis en behandeling beschreven van een intrapelvische massa ontstaan door polyethyleen slijtage bij een gecementeerde totale heup.

De karakteristieke weekdeel- en been reacties door polyethyleen partikels veroorzaakt in de periarticulaire weefsels en de differentiële diagnosis met infectieuze en

maligne processen worden beschreven. In dit precies geval ook de differentiatie met gynecologische pathologie.

### RÉSUMÉ

*S. OLESEN SCHAARUP, J. E. VARMARKEN. Masse intra-pelvienne chez une jeune femme porteuse d'une prothèse de hanche non cimentée.*

Les auteurs rapportent le cas d'une jeune femme porteuse d'une prothèse totale de hanche non cimentée, chez qui l'usure de l'insert en polyéthylène a conduit à la formation d'une masse intra-pelvienne. Ils discutent la pathogénie, le diagnostic et le traitement. Ils décrivent les modifications caractéristiques engendrées dans l'os et dans les tissus mous par la libération de particules de polyéthylène dans les tissus péri-articulaires, ainsi que le diagnostic différentiel avec des pathologies infectieuses ou tumorales. Dans le cas rapporté, le diagnostic devait aussi envisager des problèmes gynécologiques.