



Treatment of late recurring idiopathic clubfoot deformity in adults

Leonhard E. RAMSEIER, Ralf SCHOENIGER, Patrick VIENNE, Norman ESPINOSA

From Balgrist University Hospital, Zurich, Switzerland

Late recurrence of idiopathic clubfoot deformity in adults after prior successful surgery in childhood remains a rarity and only case reports exist. No study has yet clarified the results of triple arthrodesis in such cases.

Complete clinical and radiological review of 7 patients (7 feet) after a follow-up time of 43 months following triple arthrodesis was undertaken. The time interval between the last surgical intervention and the triple arthrodesis averaged 27 years. The American Orthopaedic Foot and Ankle Society (AOFAS) score was used as an outcome measure.

Average age at time of review was 36 years (range 18-45). All patients were examined clinically and radiologically.

The AOFAS-score improved from 43 points preoperatively to 61 points at follow-up ($p = 0.004$). If adjusted by excluding subtalar motion, the relative score improved by 19% (from 46% to 65%; $p = 0.0043$). Although not significantly altered ($p = 0.1$), pain scores remained fair (25 points) but were improved compared with the preoperative evaluation (13 points). Ankle motion was not changed. Although statistically not significant, there was an increase in degree of ankle arthritis in 67% of patients (one patient had ankle fusion) and mid- and forefoot degenerative changes in 57%. Hindfoot alignment remained fair after surgical intervention.

Triple arthrodesis is a palliative means to correct recurrent deformity in patients with idiopathic clubfoot. Despite residual symptoms and degenerative changes at the ankle, 86% of all patients were satisfied with the postoperative result.

Keywords : clubfoot ; adult ; triple arthrodesis.

INTRODUCTION

Conservative measures to treat clubfoot deformity in children have been proven to be very effective. Surgery is warranted in children who do not respond to conservative treatment. Surgical methods to correct clubfoot deformity include Achilles tendon lengthening, capsular releases, tendon transfers and others. Most studies investigate the outcome after primary triple arthrodesis in children with clubfoot deformity (16,18,23,32,37,39,43,44) or after restoration of painful and deforming hindfoot disorders in adults (12,41,49,52). Although some authors report good results following hindfoot and midfoot fusions in children, these treatment modalities have recently been abandoned in this age group. Residual or uncorrected clubfoot deformity

■ Leonhard E. Ramseier, MD, Orthopaedic Surgeon.

■ Ralf Schoeniger, MD, Orthopaedic Surgeon.

■ Norman Espinosa, MD, Head of Foot Surgery.

Department of Orthopaedics, Balgrist Hospital, University of Zurich, Switzerland.

■ Patrick Vienne, MD, Orthopaedic Surgeon.

Department of Orthopaedics, St Anna Clinic, Luzern, Switzerland.

Correspondence : Leonhard Ramseier, MD, Department of Orthopaedics, University of Zürich Balgrist Hospital, Forchstrasse 340, CH-8008 Zürich, Switzerland.

E-mail : leonhard.ramseier@balgrist.ch.

© 2007, Acta Orthopædica Belgica.

remains a difficult issue. The longstanding deformity may lead to irreversible degenerative changes at the foot and ankle which can only be corrected by means of arthrodesis. A clubfoot deformity recurring more than ten years after successful treatment in childhood, can be defined as a true recurrence. One may argue that there is no need for more aggressive treatment in the absence of degenerative changes at the mid- and hindfoot. However, the patient needs a definitive solution and as there is no clear explanation for the recurrence, this may only be achieved through fusion of the subtalar, talo-navicular and calcaneo-cuboid joints. True recurrence of idiopathic clubfoot deformity is very rare. A thorough review of the literature reveals that description of treatment for late recurrence of idiopathic clubfoot in adults exists only as case reports (13). The question arises how to treat such deformity in adults. This question has not yet been answered.

The term „triple arthrodesis“ refers to the combined fusion of the subtalar-, talonavicular- and calcaneocuboid joints (3,24,31,32,34,43,54). Various pathological entities, including rigid clubfoot deformity, are amenable to this type of surgical intervention. In the meantime the classic type of “triple arthrodesis” (40) has been largely modified (2, 5,14,20,22,28,29,38,42,45-47,50).

There is not much information obtainable about the use of triple arthrodesis for the treatment of late recurrent idiopathic clubfoot deformity in adults after prior successful surgical treatment in childhood.

It is the purpose of this study to evaluate the clinical and radiological outcomes of patients affected by this specific type of pathology, and treated by triple arthrodesis.

MATERIAL AND METHODS

Patients

Between July 1996 and November 2003, 7 consecutive adult patients (7 feet) were treated for late recurrent idiopathic clubfoot deformity. In all cases idiopathic clubfoot deformity was indentified. Six men and one woman participated in the present study. The average age at operation was 36 years (range 18 to 45). All patients had prior succesful surgical correction of their idiopathic clubfeet in childhood, which failed over time and became symptomatic (table I). The time interval between the last surgical intervention and recurrence averaged 27 years (range, 10-44). Each patient gave informed consent and the study was approved by the institutional board review committee.

The triple arthrodesis was performed in a standardized manner. One patient had an additional ankle fusion

Table I. — Patients demographics, time interval until recurrence, pathologies and prior clubfoot treatments (chronologically)

Patient	Gender	Side	Age at operation (years)	Pathology	Interval until recurrence (years)	Previous treatments (chronologically)
1	Male	Left	37	Idiopathic clubfoot	37	Casting, soft-tissue release and Achilles tendon lengthening
2	Male	Right	45	Idiopathic clubfoot	33	Casting, soft-tissue release and Achilles tendon lengthening ; Chopart arthrodesis
3	Male	Right	45	Idiopathic clubfoot	44	Casting, multiple soft-tissue releases, Achilles tendon lengthening
4	Male	Right	39	Idiopathic clubfoot	29	Casting, multiple soft-tissue releases, Achilles tendon lengthening
5	Male	Right	22	Idiopathic clubfoot	11	Casting, Achilles tendon lengthening, medial release, dorsomedial release, Steindler procedure
6	Male	Left	18	Idiopathic clubfoot	10	Casting, Achilles tendon lengthening, medial release, dorsomedial release, Steindler procedure
7	Female	Right	45	Idiopathic clubfoot	30	Casting, soft-tissue release

due to severe osteoarthritis. All patients were reviewed clinically and radiologically at an average follow-up of 43 months (range 24 to 88), by one observer different from the operating surgeon. Pre- and postoperative standardized outcome measurement was performed by means of the American Orthopaedic Foot and Ankle Society (AOFAS)-ankle and hindfoot-score (26), excluding the values for subtalar motion (i.e. minus 6 points). Particular attention was paid to pain relief, stability of fused joints, the talo-calcaneal angulation and evolution of degenerative changes at the ankle- mid- and forefoot joints.

Clinical assessment

After meticulous inspection and palpation of the whole foot, stability of the fused joints was determined. All measurements were performed in a standardized goniometric fashion. Motion at the ankle joint was measured with a goniometer with the foot in maximal dorsiflexion and plantarflexion. The axis of the calcaneus was assessed clinically by examining the patient standing from behind. The integrity of the subtalar arthrodesis, Chopart fusion and the lateral ligaments was tested by performing a forceful inversion of the hindfoot (testing the calcaneo-fibular ligament) or a forceful traction on the talo-calcaneal complex distally in 20° of plantar flexion at the ankle joint (testing of anterior talo-fibular ligament).

Radiographic assessment

Pre- and postoperative dorso-plantar and lateral weight-bearing views of every single foot were obtained and evaluated. The talo-first metatarsal angle was measured on the dorso-plantar as well as in the lateral radiograph.

Additionally, the talo-calcaneal angle was measured in both projections. Degenerative changes at the ankle were assessed by the method of Pell *et al* (35) who combined the classifications of Graves *et al* (19) and Bauer *et al* (table II). Particular attention was paid to the consolidation of the fused joints. All radiographic analyses were performed by the same member of our group by means of the digital Image Device, Picture Archiving and Communications System (PACS-Version 3.6 SP 6 : Image Device GmbH, Idstein, Germany).

Statistical analysis

Statistical analysis of the results was undertaken to determine whether any of the parameters of the overall

Table II. — Modified (35) ankle arthritis classification scheme, adapted according to Graves *et al* (19)

Grade	Classified	Radiological appearance
0	None	No narrowing, no osteophytes
1	Mild	> 3 mm joint space, minimal narrowing of joint space if compared to contralateral side, osteophytes
2	Moderate	1-3 mm joint space, moderate narrowing of joint space if compared to contralateral side, marked formation of osteophytes, bone sclerosis
3	Severe	Obliteration of joint space

functional outcome had changed significantly with time. A non-parametric distribution was assumed. To evaluate the statistical significance of differences noted between the preoperative and postoperative values of each measured variable within each group, the nonparametric paired t-test was used. The level of significance was set at $p \leq 0.05$. Correlations between progression of degenerative changes at the ankle- mid- and forefoot joints and overall outcome were calculated by means of the Spearman-correlation-matrix.

RESULTS

After a mean follow-up of 43 months (range, 24-88), 7 patients and 7 feet (4 right, 3 left) were reviewed. The overall AOFAS-Score improved from 43 (range 18-61) points preoperatively to 61 (range 50-67) points postoperatively ($p = 0.004$; fig 1). The relative score, adjusted by excluding subtalar motion (i.e. minus 6 points on the AOFAS-score-protocol), changed by 19%, from 46% preoperatively to 65% postoperatively ($p = 0.0043$; fig 1). Pain improved from 13 points (range 0-40; $SD \pm 15$) preoperatively (severe daily pain and impairment) to 23 points (range 20-30; $SD \pm 5$) postoperatively (moderate pain; $p = 0.1$; fig 2). Shortening of the leg after intervention averaged 1.6 centimetres (range 0 to 3.6). There was a non-significant loss of plantar flexion from 29° preoperatively to 25° postoperatively. Dorsiflexion averaged 5° preoperatively and was unchanged postoperatively. Three patients presented a valgus alignment of the hindfoot of 5° at time of follow-up. Three patients had a remaining varus malalignment of 5° and one patient had a neutral axis.

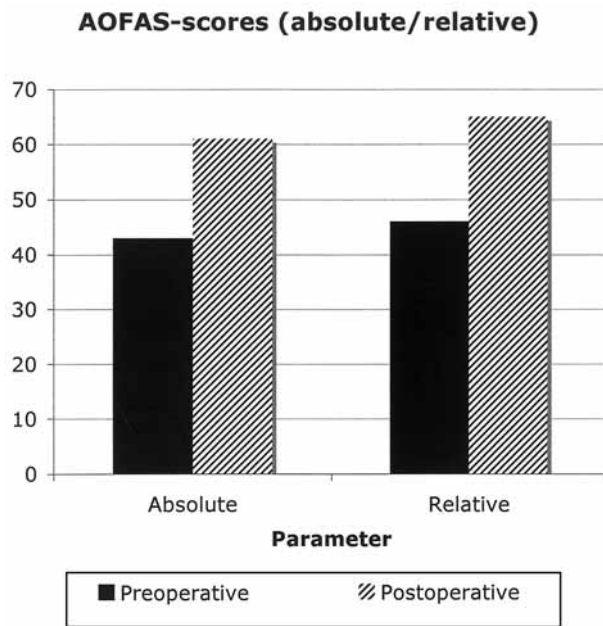


Fig. 1. — Pre- and postoperative absolute and relative AOFAS-scores (including their standard deviations) for the entire series.

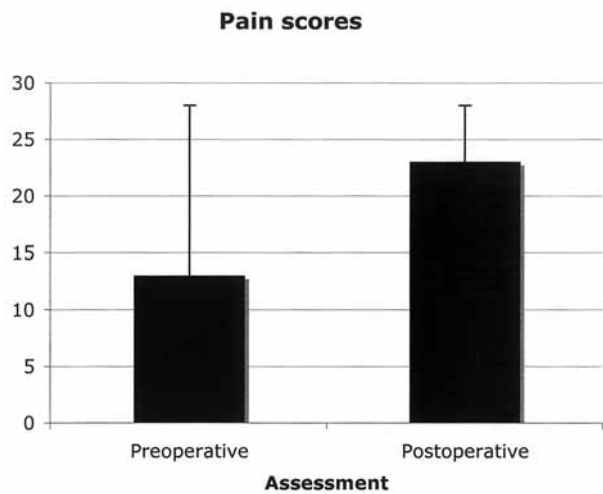


Fig. 2. — Pre- and postoperative pain scores (according to the AOFAS-protocol). An improvement was observed (including standard deviation).

On clinical examination, all patients presented preoperatively with hindfoot instability averaging a score of 0 points (= full instability). At final follow-up, all patients showed stable hindfoot conditions scoring an average of 8 point according to the

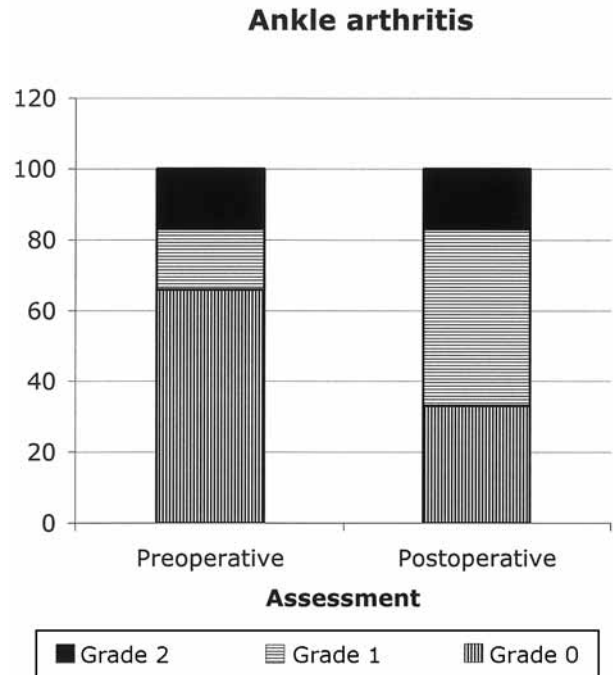


Fig. 3. — Preoperative and postoperative changes in ankle arthritis. At postoperative review there are more grade 1 cases than preoperatively. The patient with fused ankle joint was excluded. Grades were classified as shown in table II.

AOFAS-score-system ($p < 0.05$). Clinically all patients revealed completely stable situations concerning the fused joints (100%).

On lateral radiographs the talo-calcaneal angle did not change (from 4° preoperatively to 6° postoperatively ; n.s.). Also, there was no alteration of the talo-calcaneal angle if measured in the dorso-plantar view. Preoperatively assessed grades of ankle osteoarthritis (fig 3) averaged 0.8 (range 0-3 ; $SD \pm 1.2$) and did not increase (final value 0.8 ; range 0-2 ; $SD \pm 0.6$). Preoperatively one patient presented with severe osteoarthritis at the ankle joint, that required fusion. Four patients showed no degeneration (66%), 1 had grade 2 osteoarthritis (17%) and 1 grade 1 osteoarthritis (17%). Postoperatively, of the 6 patients without fusion, one had grade 2 osteoarthritis (17%), 3 had grade 1 osteoarthritis (50%) and 2 had no signs of degeneration (33%) at the ankle joint. On the contrary, 3 patients in the study group had degeneration of the midfoot and Lisfranc joints when assessed preoperatively, and at follow-up 4 patients out of 7

(i.e. 57%) presented with progressing osteoarthritis at the midfoot, especially at the naviculocuneiform joint. There was a strong correlation between persisting postoperative pain and the final AOFAS-score ($r = -0.9$; $p = 0.003$). Although there was no statistically significant correlation between the level of pain and osteoarthritis ($p = 0.2$) a relevant relation between these parameters was observed ($r = 0.5$). Hindfoot alignment was significantly altered by surgery, i.e. from 1 point preoperatively to 5 points postoperatively ($p = 0.001$). This corresponded to a moderate hindfoot alignment according to the AOFAS-protocol. Walking ability averaged 200-1000m (3 points, $SD \pm 1.1$) at preoperative assessment. At time of follow-up after triple arthrodesis, each patient was able to walk more than 1 kilometer without any pause (5 of 5 possible points on AOFAS score, $SD \pm 0.7$; $p = 0.07$). Most patients (86%) reported a high satisfaction rate after the operation. At review, 3 patients reported an excellent, 3 a good and 1 a poor subjective result (scale 1-3 : 1 = not satisfied ; 2 = satisfied ; 3 = very satisfied).

DISCUSSION

Late recurrences of clubfoot deformity after the age of 5 years are rarities and remain issues of case reports (13). There are many articles examining the treatment of young adults or adolescents by means of triple arthrodesis. Those individuals suffer either from uncorrected clubfoot deformity, neurologic disorders such as poliomyelitis (7) and Charcot-Marie-Tooth (41,53), symptomatic pes planus (51) or further pathologies. In 1964 McCauley (32) reported the effectiveness of triple arthrodesis for idiopathic clubfoot deformity in children. Hersh and Fuchs (23), who investigated primary triple arthrodesis in uncorrected clubfeet presented interesting results. However, until today optimal surgical management of equinovarus foot deformity remains debated. Various surgical methods exist in order to correct residual clubfoot deformity, starting with tibio-calcaneal arthrodesis by means of plates, screws and osteotomies (9,27,30,33,36), Ilizarov ring fixators (11,15,17,37) and ending in triple arthrodesis (1,4,10,12,14).

As stated by Wapner (52), predictable and significant improvement in symptoms may occur after triple arthrodesis if proper alignment is obtained. However the resultant loss of hindfoot motion may lead to secondary arthritis and residual discomfort of the ankle and tarsometatarsal joints. Because of the complications of residual deformity, pseudarthrosis, avascular necrosis of the talus, and ankle and midtarsal arthritis, it has been recommended that it should be used only as a salvage operation in older patients who have a painful, fixed deformity or disabling instability refractory to other treatment options (52). To our knowledge, no one has ever focused on the outcome of triple arthrodesis in adults with late recurrent idiopathic clubfoot deformity.

The present study illustrates the unsolved difficulty of late recurrent idiopathic clubfoot deformity in adults. The final AOFAS-scores were moderately improved. They averaged 61 points at review (i.e. only 65% relative score) and were comparable to results obtained after revision surgery of failed primary triple arthrodesis as published by Haddad *et al* (21). Pain and hindfoot alignment are directly associated with alterations of the score. The Haddad study presented AOFAS-scores averaging 59 points on a 94 points-scale. The authors reported good and satisfactory results after intervention. Pell *et al* (35) reported 72 points on the AOFAS-score after 5.7 years of follow-up in feet with neuromuscular imbalance. The overall satisfaction rate averaged 8.3 points in a scale ranging from 0 (= not satisfied) to 10 (= completely satisfied). But, of the 132 investigated feet only 5 were clubfeet with corresponding equinovarus deformity. Similar results were published by Saltzman *et al* (41) who investigated the long-term effect of triple arthrodesis in patients with neuromuscular hindfoot disorders. In 1991 Bennet *et al* (6) presented a 3-year follow-up of 22 patients with triple arthrodesis due to hindfoot pain and/or deformity. The study included distinctive types of deformities ranging from residual clubfoot to posttraumatic defects. Nevertheless, 18% of these patients reported an excellent, 55% a good, 23% a moderate and 4% a poor result, when rated in a subjective manner. Despite the fact that pain was not completely alleviated, our study

showed 43% excellent, 43% good and 14% poor subjective results and were comparable to the formerly mentioned studies and the observations by Graves *et al* (19).

Range of motion at the ankle joint was comparable to the results of the studies by Benett *et al* (6) and Pell *et al* (35) and averaged 32° at time of follow-up.

Deterioration of adjacent joints, due to altered load distribution, has been linked to triple arthrodesis (8). Wetmore and Drennan (53) investigated patients with Charcot-Marie-Tooth disease and confirmed an ongoing impairment of ankle joint clearance after triple arthrodesis. They concluded that loss of shock absorption may lead to increased loading of the articular surfaces (53). The ankle appears to be prone to develop symptomatic degeneration (25,48,52). Fifty percent of all patients in the study by Benett *et al* (6) presented degeneration at the ankle. Pell *et al* (35) observed degenerative progression in 54% of all patients. Graves *et al* (19) reported progression of degeneration of the ankle in 41% of all cases. So far, the present study revealed in 67% of all patients a mild-to-moderate evolution of degeneration at the ankle joint. Additionally, our studygroup showed in more than half of all patients, progression of osteoarthritis at the naviculo-cuneiform and Lisfranc joints. However, others have found that most patients suffered from ankle arthritis rather than from mid- and forefoot osteoarthritis. Limited motion at the mid- and forefoot reduces harmful force transmission which could cause early degeneration of joint cartilage in adjacent joints (8). While there are studies, which report the occurrence of nonunion, this study did not reveal any sign of nonunion at time of follow-up (8,23,41). In accordance to the study by Haddad *et al* (21) our patient population also showed some residual deformity. Hindfoot alignment was moderate at time of follow-up due to the incapacity of restoring the talo-calcaneal angles. This in turn was significantly influenced by anatomical deviations, scarry tissue and shortening of the musculo-tendinous tissues. This residual malalignment (43% of all cases) may explain further persisting discomfort and pain. Even so, each patient reported unsupported ambulation and felt

subjectively stable and functional. Follow-up time is however relatively short and a new evaluation after several more years would be indicated.

CONCLUSIONS

Triple arthrodesis may be used as *ultima ratio* (considering palliation) in the management of late recurrence of idiopathic clubfoot deformity in adults. Although substantial problems such as residual pain and deformity at the hindfoot were objectively observed, 86% of all patients reported good-to-excellent satisfaction when compared to their preoperative status. All patients were able to walk without support on a stable and functional foot. Therefore, we think that such a revision is an acceptable solution to address the issue.

REFERENCES

1. **Angus PD, Cowell HR.** Triple arthrodesis. A critical long-term review. *J Bone Joint Surg* 1986 ; 68-B : 260-5.
2. **Arango Sanin R.** [Triple arthrodesis of the foot.] (Spanish). *Med Cir (Bogota)* 1951 ; 15 : 149-170 ; concl.
3. **Arango Sanin R.** [Triple arthrodesis of the foot.] (Spanish). *Med Cir (Bogota)* 1951 ; 15 : 105-128.
4. **Atar D, Grant AD, Lehman WB.** Triple arthrodesis. *Foot Ankle* 1990 ; 11 : 45-46.
5. **Belgrano M, Cappello N, Tardella R.** [Triple arthrodesis with the temporary astragalectomy method.] (Italian). *Minerva Ortop* 1964 ; 15 : 90-94.
6. **Bennett GL, Graham CE, Mauldin DM.** Triple arthrodesis in adults. *Foot Ankle* 1991 ; 12 : 138-143.
7. **Bianchi M, Gualtieri G.** [Triple arthrodesis in the poliomyelitic foot.] (Italian). *Arch Ortop* 1964 ; 77 : 63-71.
8. **Bibbo C, Anderson RB, Davis WH.** Complications of midfoot and hindfoot arthrodesis. *Clin Orthop* 2001 ; 391 : 45-58.
9. **Biddinger KR, Komenda GA, Schon LC et al.** A new modified technique for harvest of calcaneal bone grafts in surgery on the foot and ankle. *Foot Ankle Int* 1998 ; 19 : 322-326.
10. **Catanzariti AR, Mendicino RW, Whitaker JM et al.** Realignment considerations in the triple arthrodesis. *J Am Podiatr Med Assoc* 2005 ; 95 : 13-17.
11. **de la Huerta F.** Correction of the neglected clubfoot by the Ilizarov method. *Clin Orthop* 1994 ; 301 : 89-93.
12. **DiStazio JJ.** Triple arthrodesis. *Clin Podiatr Med Surg* 1991 ; 8 : 693-699.
13. **Dobbs MB, Corley CL, Morcuende JA et al.** Late recurrence of clubfoot deformity : a 45-year follow up. *Clin Orthop* 2003 ; 411 : 188-192.

14. **Duncan JW, Lovell WW.** Hoke triple arthrodesis. *J Bone Joint Surg* 1978 ; 60-A : 795-798.
15. **El Barbary H, Abdel Ghani H, Hegazy M.** Correction of relapsed or neglected clubfoot using a simple Ilizarov frame. *Int Orthop* 2004 ; 28 : 183-186.
16. **Flamme CH, Wirth CJ.** [Triple arthrodesis correction in pes equinovarus and tetra-spasticity] (German). *Unfallchirurg* 2004 ; 107 : 343.
17. **Franke J, Grill F, Hein G et al.** Correction of clubfoot relapse using Ilizarov's apparatus in children 8-15 years old. *Arch Orthop Trauma Surg* 1990 ; 110 : 33-37.
18. **Galindo MJ, Jr., Siff SJ, Butler JE et al.** Triple arthrodesis in young children : a salvage procedure after failed releases in severely affected feet. *Foot Ankle* 1987 ; 7 : 319-325.
19. **Graves SC, Mann RA, Graves KO.** Triple arthrodesis in older adults. Results after long-term follow-up. *J Bone Joint Surg* 1993 ; 75-A : 355-362.
20. **Grueff T.** [Triple arthrodesis by temporary astragalectomy (Lorthioir method) in the treatment of poliomyelitic abnormalities of the foot ; long-term results.] (Italian). *Minerva Ortop* 1956 ; 7 : 191-196.
21. **Haddad SL, Myerson MS, Pell RF et al.** Clinical and radiographic outcome of revision surgery for failed triple arthrodesis. *Foot Ankle Int* 1997 ; 18 : 489-499.
22. **Haslam ET, Wickstrom JK.** Single Kirschner wire fixation in triple arthrodesis. *South Med J* 1955 ; 48 : 767-769.
23. **Hersh A, Fuchs LA.** Treatment of the uncorrected clubfoot by triple arthrodesis. *Orthop Clin North Am* 1973 ; 4 : 103-116.
24. **Hill NA, Wilson HJ, Chevres F et al.** Triple arthrodesis in the young child. *Clin Orthop* 1970 ; 70 : 187-190.
25. **Hutchinson B.** Current concepts in triple arthrodesis. *Clin Podiatr Med Surg* 2000 ; 17 : 1-18.
26. **Kitaoka HB, Alexander IJ, Adelaar RS et al.** Clinical rating systems for the ankle-hindfoot, midfoot, hallux, and lesser toes. *Foot Ankle Int* 1994 ; 15 : 349-353.
27. **Kose N, Gunal I, Gokturk E et al.** Treatment of severe residual clubfoot deformity by trans-mid tarsal osteotomy. *J Pediatr Orthop* 1999 ; 8-B : 251-256.
28. **Krigsten EJ, Janes JM.** A method of triple arthrodesis using autogenous tibial bone grafts. *Mayo Clin Proc* 1968 ; 43 : 205-214.
29. **Kuwada GT.** Modification of fixation technique for a subtalar joint and triple arthrodesis. *J Am Podiatr Med Assoc* 1988 ; 78 : 482-485.
30. **Lipscomb PR.** Osteotomy of calcaneus, triple arthrodesis, and tendon transfer for severe paralytic calcaneocavus deformity. Report of a case. *J Bone Joint Surg* 1969 ; 51-A : 548-552.
31. **Lynch SA, Renstrom PA.** Treatment of acute lateral ankle ligament rupture in the athlete. Conservative versus surgical treatment. *Sports Med* 1999 ; 27 : 61-71.
32. **McCauley JC.** Triple arthrodesis for congenital talipes equinovarus deformities. *Clin Orthop* 1964 ; 34 : 25-29.
33. **McCauley JC, Jr.** The history of conservative and surgical methods of clubfoot treatment. *Clin Orthop* 1972 ; 84 : 25-28.
34. **Patterson RL, Jr.** Various factors involved in triple arthrodesis. *Clin Orthop* 1972 ; 85 : 59-61.
35. **Pell RF, Myerson MS, Schon LC.** Clinical outcome after primary triple arthrodesis. *J Bone Joint Surg* 2000 ; 82-A : 47-57.
36. **Pohl M, Nicol RO.** Transcuneiform and opening wedge medial cuneiform osteotomy with closing wedge cuboid osteotomy in relapsed clubfoot. *J Pediatr Orthop* 2003 ; 23 : 70-73.
37. **Raab P, Krauspe R.** [Recurrent club foot.] (German). *Orthopäde* 1999 ; 28 : 110-116.
38. **Raisman VH.** Triple arthrodesis of the foot by Charnley compression. *J Int Coll Surg* 1964 ; 41 : 79-86.
39. **Richter M, Zech S, Geerling J et al.** [Restoration of the ability to walk through bilateral triple arthrodesis in marked spastic pes equinovarus.] (German). *Unfallchirurg* 2004 ; 107 : 50-54.
40. **Ryerson E.** Arthrodesing operations on the foot. *J Bone Joint Surg* 1923 ; 5 : 453-471.
41. **Saltzman CL, Fehrle MJ, Cooper RR et al.** Triple arthrodesis : twenty-five and forty-four-year average follow-up of the same patients. *J Bone Joint Surg* 1999 ; 81-A : 1391-1402.
42. **Sammarco GJ.** Technique of triple arthrodesis in treatment of symptomatic pes planus. *Orthopedics* 1988 ; 11 : 1607-1610.
43. **Schramm CA, Hein SC, Cooper PS.** Triple arthrodesis. *AORN J* 1996 ; 64 : 31-52 ; quiz 54-61.
44. **Seitz DG, Carpenter EB.** Triple arthrodesis in children : a ten-year review. *South Med J* 1974 ; 67 : 1420-1424.
45. **Sennara H.** Triple arthrodesis : a modified new technic. *Clin Orthop* 1972 ; 83 : 237-240.
46. **Sgarlato TE, Sharpe DA.** Triple arthrodesis : a new approach. *J Am Podiatry Assoc* 1975 ; 65 : 41-49.
47. **Siffert RS, Forster RI, Nachamie B.** "Beak" triple arthrodesis for correction of severe cavus deformity. *Clin Orthop* 1966 ; 45 : 101-106.
48. **Smith RW, Shen W, Dewitt S et al.** Triple arthrodesis in adults with non-paralytic disease. A minimum ten-year follow-up study. *J Bone Joint Surg* 2004 ; 86-A : 2707-2713.
49. **Sullivan RJ, Aronow MS.** Different faces of the triple arthrodesis. *Foot Ankle Clin* 2002 ; 7 : 95-106.
50. **Tang SC, Leong JC, Hsu LC.** Lambrinudi triple arthrodesis for correction of severe rigid drop-foot. *J Bone Joint Surg* 1984 ; 66-B : 66-70.
51. **Vogler HW.** Triple arthrodesis as a salvage for end-stage flatfoot. *Clin Podiatr Med Surg* 1989 ; 6 : 591-604.
52. **Wapner KL.** Triple arthrodesis in adults. *J Am Acad Orthop Surg* 1998 ; 6 : 188-196.
53. **Wetmore RS, Drennan JC.** Long-term results of triple arthrodesis in Charcot-Marie-Tooth disease. *J Bone Joint Surg* 1989 ; 71-A : 417-422.
54. **Wilson FC, Jr., Fay GF, Lamotte P et al.** Triple arthrodesis. A study of the factors affecting fusion after three hundred and one procedures. *J Bone Joint Surg* 1965 ; 47-A : 340-348.