



## Minimally invasive percutaneous plate fixation of distal tibia fractures

Syah BAHARI, Brian LENEHAN, Hamad KHAN, John P. McELWAIN

*From Adelaide and Meath Hospital incorporating National Children Hospital, Tallaght, Dublin, Ireland*

**We report a series of 42 patients reviewed at a mean of 19.6 months after treatment of distal tibial and pilon fractures using the AO distal tibia locking plate with a minimally invasive percutaneous plate osteosynthesis (MIPPO) technique.**

**Mean time to union was 22.4 weeks. All fractures united with acceptable alignment and angulation. Two cases of superficial infection were noted, with one case of deep infection. Mean SF36 score was 85 and mean AOFAS score was 90 at a mean of 19 months follow-up. We report satisfactory outcomes with the use of the AO distal tibia locking plate in treatment of unstable distal tibial fractures. Eighty-nine percent of the patients felt that they were back to their pre injury status and 95% back to their previous employment.**

**Keywords :** pilon fracture ; distal tibia ; locking plate ; MIPPO ; soft tissue ; infection.

dehiscence (3,4,22,24,25). External fixation (12,13,16,18,19) and intramedullary nailing (10,11,14,21) techniques undoubtedly minimise soft-tissue trauma and have been shown to reduce wound infection (10,11,13) but their use is complicated by malunion and nonunion, imperfect reduction of articular surface, and pin tract infection (12,19). The AO distal tibia locking plate (®Synthes) applied percutaneously by adhering to the minimally invasive percutaneous plate osteosynthesis (MIPPO) technique was developed by the AO group to address the soft tissue problems associated with ORIF of the distal tibia. We report a series of patients who were treated in our institution for fractures of the distal tibial metaphysis with or without intraarticular

### INTRODUCTION

The treatment of unstable distal tibia or pilon fractures remains controversial. Reports from various institutions suggest treatment modalities ranging from minimally invasive technique, open reduction and internal fixation (ORIF), intramedullary nailing (IM), hybrid or ring external fixation (2-5,8,9,10-14,16-19,20-25). These treatment modalities are associated with their benefits and complications. Evidence shows that ORIF can often be complicated by infection and wound

■ Syah Bahari, Registrar in Trauma & Orthopaedic Surgery.

■ Brian Lenehan, Specialist Registrar in Trauma & Orthopaedic Surgery.


■ Hamad Khan, Consultant in Trauma & Orthopaedic Surgery.

■ John P. McElwain, Consultant in Trauma & Orthopaedic Surgery.

*Department of Orthopaedics, Adelaide and Meath Hospital incorporating National Children Hospital, Tallaght, Dublin, Ireland.*

Correspondence : Dr. Syah Bahari, 15 Millbank, The Links, Station Road, Portmarnock, Co. Dublin, Republic of Ireland.  
E-mail : syahbahari@gmail.com.

© 2007, Acta Orthopædica Belgica.



*Fig. 1.* — (a & b) The pre contoured AO distal tibia locking plate used in our study

involvement, using this plate and minimal osteosynthesis technique.

### The AO distal tibia plate (15) (fig 1)

The AO distal tibia locking plate has been developed for fractures in the metaphyseal area that may reach into the shaft. The distal end is anatomically contoured to the distal medial tibia. The first eight threaded screw holes in the distal section are angled to allow optimal fixation of the screws in the epiphyseal and metaphyseal area without penetrating the joint. The dense net of 3.5 LCP combination holes in the thinned plate area allows the insertion of up to 9 screws to provide a higher anchoring stability. The long hole helps to fine-tune the reduction in the longitudinal axis. The locking screw-plate interface allows fracture fixation without plate-bone adherence thus preserving fracture haematoma, and reduces the risk of non-union. The AO distal tibia locking plate is available in titanium and stainless steel.

### Management Protocol (fig 2)

Our protocol in management of distal tibia or pilon fracture consists of immediate reduction with temporary plaster stabilisation. Soft tissue assessment is performed prior to surgery, and if there is doubt on the viability of the soft tissue, bridging external fixation is performed for skeletal and soft tissue stabilisation (19). An associated fibula fracture can be treated with ORIF if the soft tissue allows it. Elevation of the fractured limb with generous use of ice to reduce the swelling are utilised in the initial management. Open injuries are treated with intravenous antibiotics, adequate wound debridement and lavage prior to any definitive fixation.

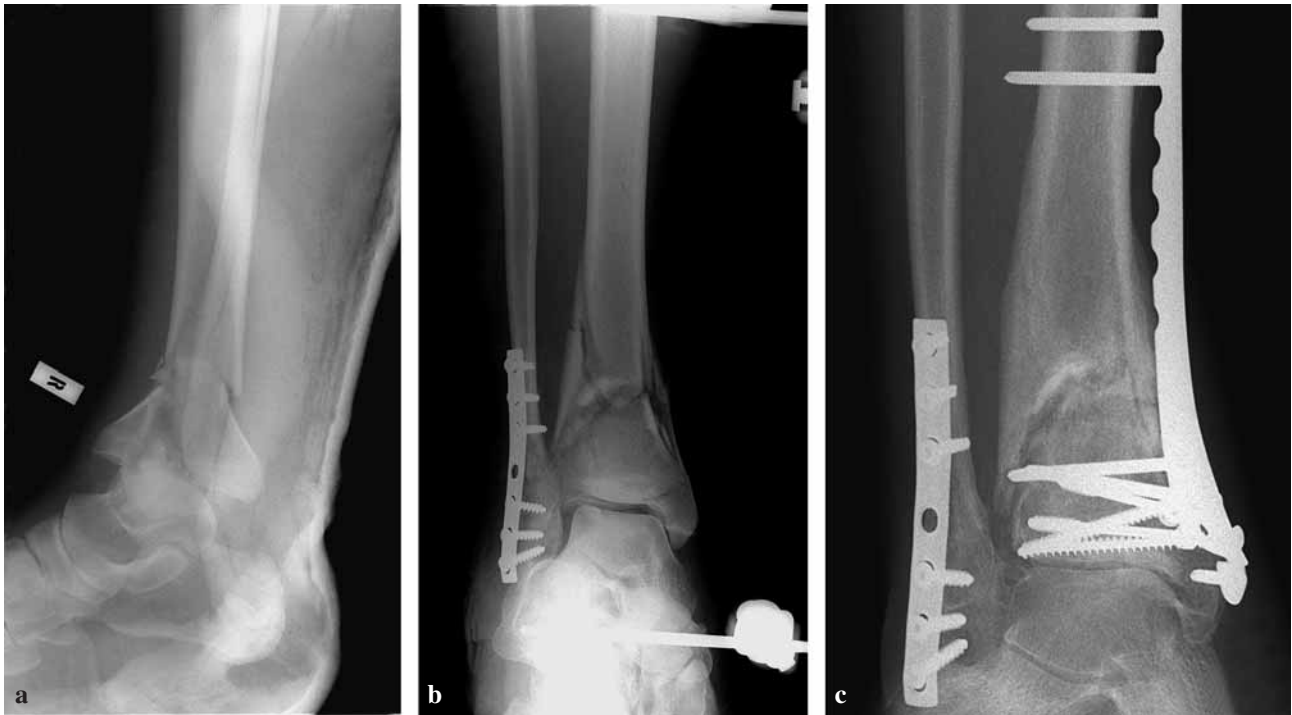Further investigations performed prior to definitive fixation such as computed tomography (CT) of the distal tibia is useful in assessment of the articular extension in pilon fracture. Preoperative assessment is the key in the minimally invasive procedure as the technique limits the exposure, and identification of the various articular fragments is vital for reconstruction (9).

Anatomical reduction of the articular surface is essential prior to plate placement. Restoring articular congruity can be performed by percutaneous techniques, utilising fluoroscopy. Direct open reduction may be used in difficult cases. Once reduction is achieved, the articular fragments are stabilised with 3.5 mm lag screws. The appropriate length for the distal tibial plate is determined by placing the plate over the medial aspect of the tibia allowing at least 3 screws to be placed proximal to the fracture.

Postoperative plaster cast immobilisation is not used routinely. Active range of motion (AROM) with non weight bearing postoperatively is allowed initially and weight bearing as tolerated is allowed over time depending of fracture healing and stability of fracture fixation.

### PATIENTS AND METHODS

Patients with distal tibia or pilon fractures treated in our institution were prospectively followed. AP and lateral full length view of the tibia and fibula and dedicated ankle radiographs were taken in all cases. All fractures were classified using the AO classification and intra-articular fractures were further classified using the Ruedi & Allgöwer classification. Fractures were considered healed when mature bridging callus was identified on two views and patients reported no pain on full weight bearing. Soft tissue outcome was assessed from history of wound infection, wound dehiscence, plate impingement and plate removal. American



**Fig. 2.** — (a) Pilon fracture of distal tibia, preoperative radiograph ; (b) Temporary bridging external fixator for soft tissue and skeletal stabilisation. ORIF fibula performed when soft tissue swelling was acceptable ; (c) Postoperative radiograph. Mature callus formation over the fracture site.

Orthopaedic Foot and Ankle Score (AOFAS), SF-36 score, time back to work and change of work in relation to the injury were used to assess the functional outcome.

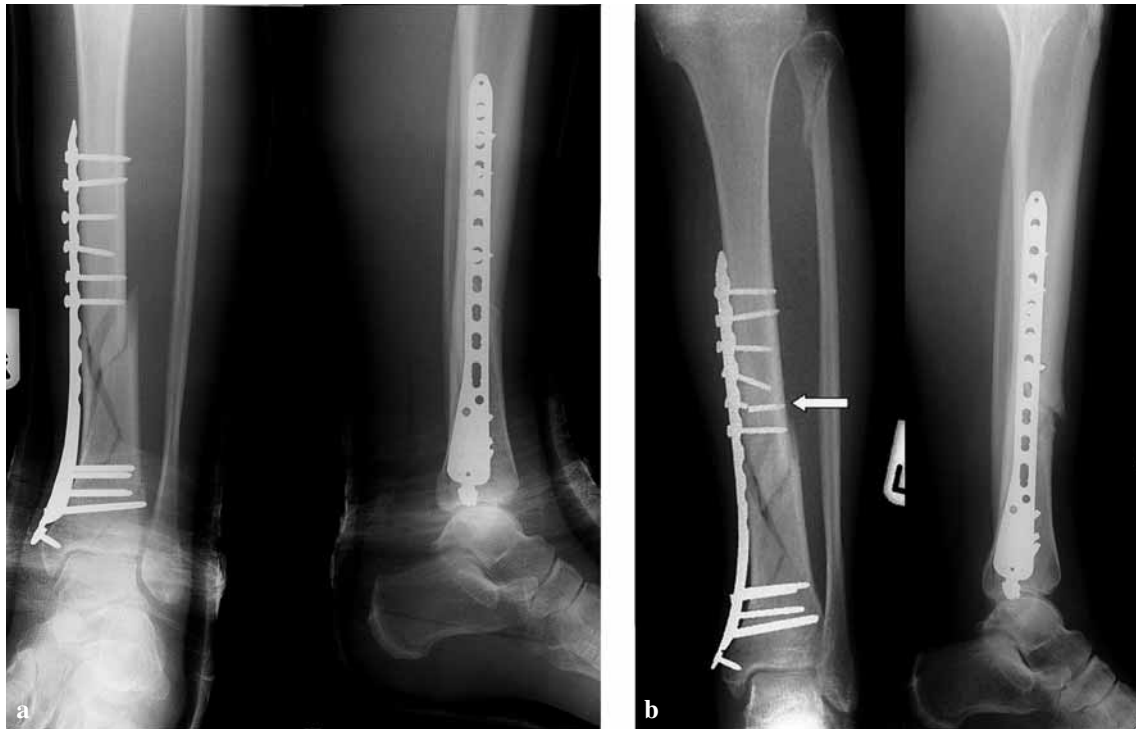## RESULTS

Between January 2004 and December 2005, 48 patients with distal tibia or pilon fracture were treated with the AO distal tibia locking plate. Forty-two patients, 31 male and 11 female, were available for follow-up. Mean age was 35 years (range, 17-75). Thirty-two cases were high-energy fractures related to a road traffic accident or a fall from a height, and 10 patients had low-energy trauma. Eight cases were open fractures and classified by the Gustilo-Anderson classification. Five cases were Type IIIA, two cases were Type II and one case was Type I. The fractures were classified by AO/ASIF and Ruedi-Allgöwer classification. Fifteen cases were 43A, 5 were 43B and 22 were 43C based on the AO/ASIF classification. Thirty

cases were associated with articular involvement. Nine were Type I, 16 were Type II and five were Type III based on the Ruedi-Allgöwer classification. In 29 cases, the fibula was involved and plated. Twelve patients had a bridging external fixator applied prior to definitive treatment due to soft tissue swelling. The mean follow-up time was 19.6 months (range, 9-24). Mean time to fracture healing was 22.4 weeks. Mean SF36 score was 85 and mean AOFAS score was 90 at a mean of 19 months follow-up. There were one case of hardware failure (fig 3) and two of superficial infection. There was one case of deep infection. Three patients had metalwork removal due to plate impingement.

## DISCUSSION

Fractures of the distal tibia or pilon fractures are often associated with significant soft tissue injury. The key point in management of this injury is to



**Fig. 3.** — Radiographs of the patient who presented a fracture of one proximal screw. Comparison (a) before hardware failure (b) after hardware failure. The overall tibial alignment is maintained.

recognise the importance of the soft tissue component (13). Failing to appreciate the soft tissue condition will invariably complicate the injury with infection, wound dehiscence or non union. Where the soft tissue injury is significant, bridging external fixation is advantageous for skeletal and soft tissue stabilisation (19). Definitive fixation is only advisable when the soft tissue allows it, when the 'wrinkle sign' is evident.

Open fractures are treated with adequate debridement, washout, tetanus prophylaxis and broad spectrum antibiotics cover. Significant soft tissue loss after debridement is a problem as adequate soft tissue cover is difficult in this area. Skin graft and free flap are viable treatment options (22).

Reports in the literature on ORIF of distal tibia or pilon fractures are plagued by wound infection (3,4,22,24,25). The high-energy trauma sustained during the initial injury causes massive soft tissue injury and often devitalises the soft tissue around

the fracture site. The anteromedial aspect of the distal tibia is most at risk of wound infection and dehiscence (11).

Previously published infection rates in the management of this injury range from 0% to 50% (2-5,8,9,10-14,16-19,20-25). ORIF has been shown to have the highest infection rates compared to other methods of treatment (24). Deep infection and wound dehiscence are the major soft tissue complications. Wound debridement, antibiotics, skin grafting, myocutaneous flap and even arthrodesis have a role to play in management (22). Studies using external fixation techniques reported significant reduction in infection rates (12,13,16,18,19). Infection rates in the MIPPO technique are better than in previously reported ORIF studies and comparable to external fixation technique (2,5,8,9,17,22,23). This is reflected in our results, with only two cases (4%) of superficial wound infection, which completely resolved with appropriate antibiotics. We found one case of deep infection which necessitated hardware

removal. *Staphylococcus Aureus* sensitive to flu-cloxacillin was cultured. The fracture was united at time of hardware removal.

Reports suggest that intramedullary nailing has the lowest infection rates compared with other techniques (10,11) but the technique is associated with other complications such as malunion, fat embolus syndrome, compartment syndrome and anterior knee pain (10). Angular malalignment and malunion have been reported with intramedullary nailing of these fractures (10). Studies involving external fixation techniques showed complications such as loosening, malunion, imperfect articular reductions and pin tract infections (18,19). ORIF has the lowest rate of angular malunion (4,10,22) compared to external fixation (16,19) or intramedullary nailing (10) but the downside is the high infection rates.

The AO distal tibia locking plate applied with minimally invasive techniques allows fracture reduction and alignment without the associated wound complications in ORIF.

The distal tibia plate is pre-contoured to the anatomy of the distal tibia and thus allows placement of the plate without disruption of fracture fragments. The distal end of the plate allows placement of locking screws that provide stability where satisfactory bone purchase is difficult. The threaded holes lock to the locking screw head and minimise plate-bone interface and maintain the vascularity of the fracture site. The proximal combination holes allow insertion of locking or cortical screws where relative or absolute stability can be achieved.

We found one case of hardware failure where one of the proximal screws broke but the overall alignment and angulation was maintained (fig 3a & b). Acceptable tibial alignment was 5° of varus or valgus and 10° of recurvatum or procurvatum. All of our patients were found to have acceptable reduction and alignment post operatively and at union.

Fracture healing is defined as mature callus formation seen on plain radiograph with pain free full weight bearing. Mean fracture healing was found at 22.4 weeks postoperatively. Our results are comparable to other studies using the MIPPO tech-

nique (5,20). Comparing the results with other methods of fixation, our results are better in comparison with ORIF and external fixation (2-5,8,9,12,13,16-18, 20,22-25).

Distal tibia plating allows early active range of movement as postoperative plaster immobilisation is not necessary. We found that ankle stiffness is not a problem, with a mean AOFAS score of 90 at 18 months follow-up. Partial weight bearing or weight bearing as tolerated was allowed at a mean of 5.6 weeks postoperatively and full weight bearing was allowed at a mean of 11.3 weeks postoperatively.

Routine metalwork removal is not necessary, as opposed to external fixation. Superficial tenderness or impingement over the medial aspect of the medial malleolus was noted in five cases but only three opted for plate removal as it interfered with activities of daily living. Anterior knee pain is not an issue in comparison to intramedullary nailing (10,11).

The mean modified SF-36 score was 85 and this is comparable with the normal general Irish population (1). Eighty-nine percent of the patients felt that they were back to their pre-injury status and 95% were back to work within 6 months of injury.

## REFERENCES

1. **Blake C, Codd MB, O'Meara YM.** The Short Form 36 (SF-36) health survey : normative data for the Irish population. *Ir J Med Sci* 2000 ; 169 : 195-200.
2. **Blauth M, Bastian L, Krettek C, Knop C, Evans S.** Surgical options for the treatment of severe tibial pilon fractures. A study of three techniques. *J Orthop Trauma* 2001 ; 15 : 153-160.
3. **Bonar SK, Marsh JL.** Tibial plafond fractures : Changing principles of treatment. *J Am Acad Orthop Surg* 1994 ; 2 : 297-305.
4. **Bone LB.** Fractures of the tibial plafond. *Orthop Clin North Am* 1987 ; 18 : 95-104.
5. **Borg T, Larsson S, Lindsjo U.** Percutaneous plating of distal tibia fractures. Preliminary results in 21 patients. *Injury* 2004 ; 35 : 608-614.
6. **Borrelli J, Prickett W, Song E, Becker D, Ricci W.** Extra osseous blood supply of the distal tibia and the effects of different plating techniques : Human cadaveric study. *J Orthop Trauma* 2002 ; 16 : 691-695.
7. **Farouk O, Krettek C, Miclau T, Schandelmaier P, Guy P, Tscherne H.** Minimally invasive plate osteo-



- synthesis and vascularity ; preliminary results of cadaver injection study. *Injury* 1997 ; 28 : Suppl 1 : A7-A12.
8. **Helfet D, Shonnard P, Levine D, Borelli J.** Minimally invasive plate osteosynthesis of distal fractures of the tibia. *Injury* 1997 ; 28 : Suppl 1 : A42-48.
  9. **Helfet DL, Koval K, Pappas J, Sanders RW, Di Pasquale T.** Intraarticular "pilon" fracture of the tibia. *Clin Orthop* 1994 ; 298 : 221-228.
  10. **Im GI, Tae SK.** Distal metaphyseal fractures of tibia : a prospective randomised trial of closed reduction and intramedullary nail versus open reduction and plate and screw fixation. *J Trauma* 2005 ; 59 : 1219-1223.
  11. **Konrath G, Moed BR, Watson JT, Kaneshiro S, Karges DE, Cramer KE.** Intramedullary nailing of unstable diaphyseal fractures of the tibia with distal intraarticular involvement. *J Orthop Trauma* 1997 ; 11 : 200-205.
  12. **Marsh JL, Bonar S, Nepola JV et al.** Use of an articulated external fixator for fractures of the tibial plafond. *J Bone Joint Surg* 1995 ; 77-A : 1498-1509.
  13. **Mockford BJ, Ogonda L, Warnock D, Barr RJ, Andrews C.** The early management of severe tibial pilon fractures using a temporary ring fixator. *Surgeon* 2003 ; 1 : 104-107.
  14. **Mosheiff R, Safran O, Segal D, Liebergall M.** The unreamed tibial nail in the treatment of distal metaphyseal fractures. *Injury* 1999 ; 30 : 83-90.
  15. **Pallister I, Iorwerth A.** Indirect reduction using a simple quadrilateral frame in the application of distal tibial LCP-technical tips. *Injury* 2005 ; 36 : 1138-1142.
  16. **Pavolini B, Maritato M, Turelli L, D'Arienzo M.** The Illizarov fixator in trauma. A 10-year experience. *J Orthop Sci* 2000 ; 5 : 108-113.
  17. **Perren SM.** Minimally invasive internal fixation. History, essence and potential of a new approach. *Injury* 2001 ; 32 : SA1-3.
  18. **Piper KJ, Won HY, Ellis AM.** Hybrid external fixation in complex tibial plateau and plafond fractures : An Australian audit of outcomes. *Injury* 2005 ; 36 : 178-184.
  19. **Rammelt S, Endres T, Grass R, Zwipp H.** The role of external fixation in acute ankle trauma. *Foot Ankle Clin* 2004 ; 9 : 455-474.
  20. **Redfern DJ, Syed SU, Davies SJM.** Fractures of the distal tibia. Minimally invasive plate osteosynthesis. *Injury* 2004 ; 35 : 615-620.
  21. **Robinson CM, McLauchlan GJ, McLean IP, Court-Brown CM.** Distal metaphyseal fractures of the tibia with minimal involvement of the ankle : classification and treatment by locked intramedullary nailing. *J Bone Joint Surg* 1995 ; 77-B : 781-787.
  22. **Sands A, Grujic L, Byck DC, Agel J, Benirschke S, Swiontkowski MF et al.** Clinical and functional outcomes of internal fixation of displaced pilon fractures. *Clin Orthop* 1998 ; 347 : 131-137.
  23. **Sirkin M, Sanders R, DiPasquale T, Herscovici D.** A staged protocol for soft tissue management in the treatment of complex pilon fractures. *J Orthop Trauma* 2004 ; 13 : 78-84.
  24. **Teeny SM, Wiss DA.** Open reduction and internal fixation of tibial plafond fractures. *Clin Orthop* 1993 ; 292 : 108-117.
  25. **Wyrsh B, McFerran MA, McAndrew M et al.** Operative treatment of fractures of the tibial plafond. A randomised, prospective study. *J Bone Joint Surg* 1996 ; 78-A : 1646-1657.