



False aneurysm of the profunda femoris artery, a rare complication of a proximal femoral fracture

Ewan D. RITCHIE, Daniël HAVERKAMP, Tom J.M.J. SCHIPHORST, Koop BOSSCHA

From Jeroen Bosch Hospital, 's Hertogenbosch, The Netherlands

The authors describe a false aneurysm of the profunda femoris artery caused by a bony fragment from the lesser trochanter after a proximal femoral fracture. False aneurysm as a complication of a hip fracture is rare ; however it is essential to consider the possibility, more even so if there is inexplicable persisting pain after internal fixation. Symptoms are sometimes difficult to judge, as they can be almost identical to usual symptoms after an operated hip fracture. In this case we present a female patient with persistent pain after a surgically fixed proximal femoral fracture. CT scan showed a false aneurysm caused by a bony fragment of the lesser trochanter. Because of the persisting mechanical stress from the bony fragment we decided to explore the false aneurysm and to remove the bony fragment. It is essential to be aware of adjacent vascular and neurological structures when a fracture is seen and operated on.

Keywords : false aneurysm ; proximal femoral fracture ; profunda femoris artery ; internal fixation.

A false aneurysm is defined as a pulsating haematoma with the presence of a wall made of connective tissue, without an endothelium and other arterial vessel wall components. A false or pseudo aneurysm contains a permanent arterial blood circulation, as it communicates with the adjacent blood vessel and thrombotic mass (4, 6).

We present a case of a proximal femoral hip fracture treated with a dynamic hip screw in which a false aneurysm developed because of a bony fragment penetrating the profunda femoris artery.

CASE REPORT

A 74-year-old female sustained a proximal femoral fracture of her left hip after a significant trauma. After closed reduction she received an AO dynamic hip screw (fig 1-2). The postoperative radiograph was satisfactory. During her revalida-

INTRODUCTION

The development of a false aneurysm after a hip fracture is a rare complication. Since the first case was reported in 1969 by Bouma *et al* (1) only few other case reports on false aneurysm as a complication of a hip fracture or its surgical treatment have been reported. The cause of most of these false aneurysms was penetration of a blood vessel during drilling or by screws.

- Ewan D. Ritchie, MD, Resident.
- Daniël Haverkamp, MD PhD, Resident.
- Tom J.M.J. Schiphorst, MD PhD, Surgeon.
- Koop Bosscha, MD PhD, Surgeon.

Department of Surgery, Jeroen Bosch Hospital, 's Hertogenbosch, The Netherlands.

Correspondence : D. Haverkamp, MD PhD, Academic Medical Centre, Amsterdam, Departement of Orthopaedic Surgery (G4), PO Box 22660. 1100DD Amsterdam, The Netherlands. E-mail : D.Haverkamp@osteotomie.nl.

© 2007, Acta Orthopædica Belgica.

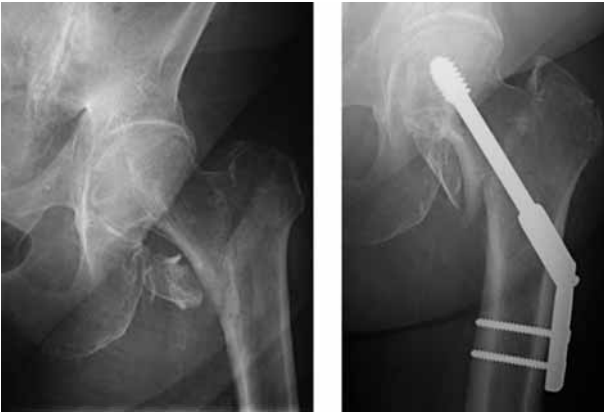

Fig. 1 & 2. — AP radiograph of the left hip showing the fracture of the proximal femur before and after internal fixation with a DHS.

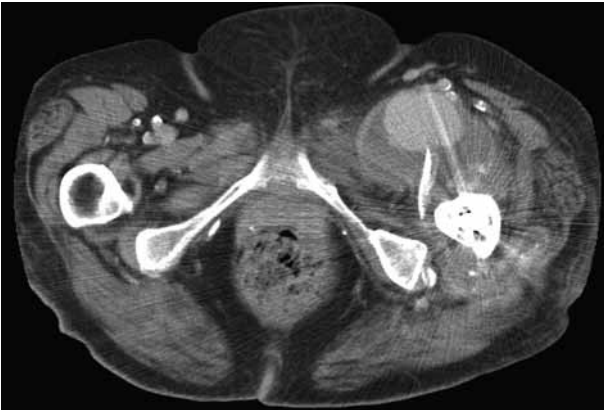

Fig. 3. — CT scan showing a pseudoaneurysm of the profunda femoris artery caused by a bony fragment from the lesser trochanter, with haematoma.

tion she complained of persisting pain in her left inguinal region, while X-ray investigation showed no explanation for complaints. Pain was present on weight bearing and walking. On inspection, no abnormalities were visible and on physical examination of the left thigh a palpable non pulsating swelling in the left groin was noted, which was not painful. Distal pulses were normal as was confirmed with Doppler signals. A CT-scan showed a false aneurysm of the profunda femoris artery caused by a bony fragment from the minor trochanter (fig 3). Angiography showed the precise location of the false aneurysm (fig 4). The distal arteries displayed normal size and flow.

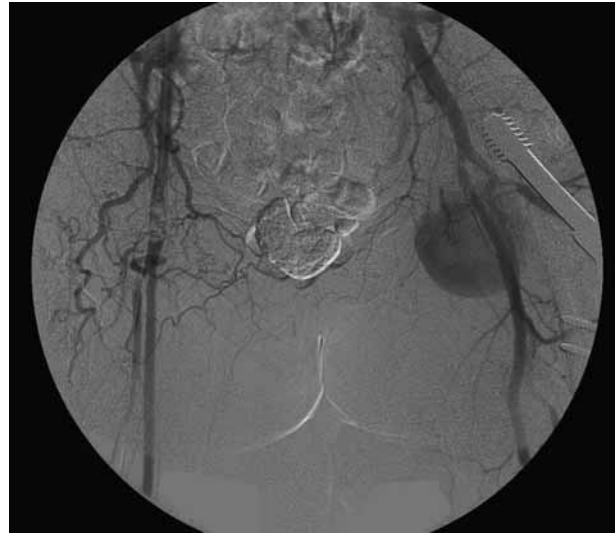


Fig. 4. — Angiography of the femoral artery showing the false aneurysm developed from a branch of the profunda femoris artery.

Because of the mechanical stress caused by the bony fragment, other therapeutic options were not considered and the false aneurysm was treated by surgical exploration. Distal to the second bifurcation of the profunda femoris artery the medial branch disappeared into the false aneurysm. The false aneurysm was opened showing the underlying bony fragment of the trochanter minor. The branch causing the false aneurysm was ligated and the remaining profunda femoris artery was saved. The loose fragment of the minor trochanter was removed, relieving possible persisting strain on adjacent vessels. The patient experienced an uneventful postoperative recovery.

DISCUSSION

A false aneurysm after a proximal femoral fracture is a rare complication. The first symptoms may be pain and/or an expanding haematoma, caused by a penetrating injury to the femoral arteries. These symptoms are often difficult to evaluate, since pain (and an occasional haematoma) is not unusual after surgical fixation of a proximal femoral fracture. If suspected, physical examination may strengthen the suspicion of the presence of a false aneurysm.

Pulsations are often palpable and systolic bruits can be heard over the aneurysm. The pulse distal to the false aneurysm can be present although it might be weaker because of diminished blood flow, a result of partial laceration of the vessel wall. Duplex ultrasonography is an easy non invasive diagnostic tool to visualise a false aneurysm, and essential information can be obtained concerning size, length and diameter of the neck of a false aneurysm and compression on surrounding tissue.

Although angiography used to be the gold standard to confirm the diagnosis, nowadays it is only used when ultrasonography is not conclusive or when a precise localisation of the aneurysm is required for surgical planning.

False aneurysms can obliterate spontaneously, especially when smaller than one inch and with a small neck. However, it is essential to follow these patients with ultrasound examination on a regular basis, because in some cases it might eventually be necessary to treat the false aneurysm. A false aneurysm can also result in bleeding, infection and necrosis, and rupture, compression of adjacent neurovascular structures or even distal embolisation.

The management of false aneurysms depends on the site of the injury and the size of the cavity. There is no gold standard on how to treat false aneurysms after trauma, and treatment choices depend more or less on the preference of the vascular surgeon.

Traditional treatment of false aneurysms is surgical exploration, a technique which is still widely accepted. There is no clear consensus on which types of false aneurysm should be treated surgically. Surgical exploration offers good results when other less invasive techniques have failed to resolve the problem. Several other techniques are available. Small false aneurysms can be compressed ultrasonically resulting in cure in 75% (5, 7). Other techniques like thrombin injections, minimally invasive intravascular stent placement, are also extensively described (2, 3, 8-10).

In this case mechanical strain on the damaged branch of the profunda femoris artery was caused by a bony fragment of the lesser trochanter. This bony fragment was removed as it could cause persisting mechanical stress, resulting in further

vascular injury. In proximal femoral fractures a surgeon should, at all times, be aware of the underlying femoral artery. A false aneurysm can be caused by several events : the fracture itself, reduction of the fracture and penetration by drilling or screws. As our case shows, not only the surgical intervention (drilling) can cause a false aneurysm, but also the fracture itself.

Probably more vascular injuries occur than are diagnosed because they can obliterate spontaneously (7). It is essential to be aware of adjacent vascular and neurological structures when a fracture is seen and operated on. Early detection of a false aneurysm can lead to swift intervention and less complications.

REFERENCES

1. **Bouma S, Van der Kruk M, Van Raalten CW.** False aneurysm following the insertion of a McLaughlin plate. *Arch Chir Neerl* 1969 ; 21 : 59-65.
2. **Cope C, Zeit R.** Coagulation of aneurysms by direct percutaneous thrombin injection. *AJR (Am J Roentgenol)* 1986 ; 147 : 383-387
3. **Criado E, Marston WA, Ligush J et al.** Endovascular repair of peripheral aneurysms, pseudoaneurysms and arteriovenous fistulas. *Ann Vasc Surg* 1997 ; 11 : 256-263.
4. **Dhal A, Chadha M, Lai H, Singh T, Tyagi S.** Encounters with pseudoaneurysms in orthopaedic practice. *Injury* 2001 ; 32 : 771-778.
5. **Eisenberg L, Paulson EK, Kliever MA, Hudson MP, DeLong DM, Carroll BA.** Sonographically guided compression repair of pseudoaneurysms : further experience from a single institution. *AJR (Am J Roentgenol)* 1999 ; 173 : 1567-1573.
6. **Franklin JA, Brigham D, Bogey WM, Powell CS.** Treatment of iatrogenic false aneurysms. *J Am Coll Surg* 2003 ; 197 : 293-301.
7. **Kazmers A, Meeker C, Nofz K et al.** Nonoperative therapy for postcatheterization femoral artery pseudoaneurysms. *Am Surg* 1997 ; 63 : 199-204.
8. **Khoury M, Rebecca A, Greene K et al.** Duplex scanning-guided thrombin injection for the treatment of iatrogenic pseudoaneurysms. *J Vasc Surg* 2002 ; 35 : 517-521.
9. **Powell A, Benenati JF, Becker GJ, Katzen BT, Zemel G.** Percutaneous ultrasound-guided thrombin injection for the treatment of pseudoaneurysms. *J Am Coll Surg* 2002 ; 194 (1 Suppl) : S53-57.
10. **Thalhammer C, Kirchherr AS, Uhlich F, Waigand J, Gross CM.** Postcatheterisation pseudoaneurysms and arteriovenous fistulas : repair with percutaneous implantation of endovascular stents. *Radiology* 2000 ; 214 : 127-131.