



Management of humeral head fractures with a trauma shoulder prosthesis : Correlation between joint function and healing of the tuberosities

Falk REUTHER, Stefan MÜLLER, Diethard WAHL

From the German Red Cross Hospital (DRK-Kliniken), Berlin, Germany

This prospective follow-up study investigated the correlation between healing of the tuberosities and the functional outcome after arthroplasty with a trauma shoulder prosthesis in elderly patients with non-reconstructible humeral head fractures. Surgery was performed on 65 patients (66 shoulders) with a mean age of 74.9 years.

A total of 56 patients (57 cases) underwent clinical and radiological evaluation after a mean follow-up of 16 months (range : 4 to 62). Mean Constant Score was 50 and the age- and gender-corrected value was 73%. The Constant Score was significantly higher (62 points, $p = 0.015$) if the tuberosities healed. Mean ASES index was 68 and correlated significantly with the Constant Score ($r = 0.77$).

Healing of the tuberosities appears to be crucial to achieve good function in patients treated with a humeral head prosthesis. For elderly patients, the main objectives are to recover the ability to perform activities of daily living, to become pain free, and to reach a high level of satisfaction. All these criteria were largely achieved by the procedure described in this paper.

Keywords : humeral head fracture ; trauma shoulder prosthesis ; Constant Score ; tuberosities.

INTRODUCTION

Considering the changes in demographics, the number of humeral head fractures is expected to

further increase in the future (1, 23). While fractures with minor or absent displacement can be successfully managed with a conservative technique, the outcome of displaced multiple-fragment humeral head fractures is a restriction in function with limited motion and residual pain (26). Therefore, there is a need for treatment to reduce pain and enable elderly individuals in particular to perform routine activities (22, 46). Currently, minimal osteosynthesis and systems with angular stability are used because of better anchoring in osteoporotic bone (20, 28, 36). Common complications such as humeral head necrosis, secondary displacement, pseudoarthrosis, and secondary stiffness either require a second intervention or lead to a poor outcome with pain and limited range of motion (8, 14, 26, 43, 46). Hemiarthroplasty as a therapeutic option for the management of multiple-fragment fractures of the humeral head was pioneered by Charles Neer in

■ Falk Reuther, MD, Head of Department.

■ Stefan Müller, MD, Resident.

■ Diethard Wahl, MD, PhD, Head of Department, retired.

Department of Trauma and Orthopaedics, DRK Hospital, Berlin - Köpenick, Berlin, Germany.

Correspondence : Dr Falk Reuther, Klinik für Unfallchirurgie und Orthopädie der DRK-Kliniken Berlin - Köpenick, Salvador-Allende-Str. 2-8, D-12559 Berlin, Germany.

E-mail : f.reuther@drk-kliniken-koepenick.de.

1970 (29, 33). The Neer prosthesis has been considered for a long time to be the golden standard in the treatment of three and four part fractures. However, the excellent results regarding functional outcome published by Neer (31, 33) could not be confirmed by other authors (6, 7, 29, 38). Several authors reported major functional loss after shoulder hemiarthroplasty for acute fractures and stressed the need for an improved prosthetic design.

In the 1990's, increasing efforts were made to design prostheses to meet the requirements of the individual fractures and therefore to achieve improved function of the artificial joint (34, 47, 48). The secure and stable re-attachment of the tuberosities appears crucial for good functional results (13).

This paper investigates the correlation between the healing of the tuberosities, and the functional result after shoulder hemiarthroplasty of non-reconstructible multiple-fragment humeral head fractures in elderly patients.

PATIENTS AND METHODS

A total of 66 trauma shoulder prostheses were implanted in 65 patients with non-reconstructible humeral head fractures. All hemiarthroplasties were performed in one hospital between April 2000 and December 2004. All patients were treated with a modular trauma shoulder prosthesis (ARTICULA®, Mathys AG, Bettlach, Switzerland). This implant consists of three pieces (stem, middle part and head) (fig 1). Height (± 15 mm) and retroversion (360°) of the implant can be adjusted intraoperatively after implantation of the stem. The middle part of the implant is voluminous with external spikes to achieve good primary fixation.

Patient demographics are given in table I. Fractures were classified according to the Neer classification (32). The indications in the 66 cases were : 21 cases (31.8%) of 4-part fractures, 16 cases (24.2%) of 3-part fractures with shallow humeral head, and 12 cases (18.2%) of anterior and posterior fracture dislocations with involvement of the greater tuberosity or both tuberosities. The remaining indications were mainly fractures of the anatomical neck and split fractures of the humeral head.

The degree of osteoporosis was judged intraoperatively by the surgeon and classified as severe, moderate or absent. Severe or moderate osteoporosis was noted intraoperatively in 58% and 34% of cases, respectively.



Fig. 1. — The ARTICULA® trauma shoulder prosthesis.

Table I. — Age at operation by gender (in years)

	N	Mean	SD	Median	Min	Max
Males	9	69.3	7.7	69.0	54.4	84.2
Females	57	75.8	8.9	77.4	50.0	93.7
All	66	74.9	9.0	75.2	50.0	93.7

The position of the prosthesis was considered to be correct and anatomical if the head was congruent to the glenoid. Cranial or caudal position was classified as subluxation, and even minimal displacement of the head was classified as displacement. The immediate post-operative radiograph showed the head of the prosthesis to be optimally positioned in 71% (n = 46) of cases.

Caudal subluxation was noted in 20% (n = 13) and was related to atony of the deltoid muscle. Cranial subluxation was noted in 9% (n = 6) of the cases. The greater tuberosity was considered to be in the correct anatomical position if its proximal point was 5-8 mm underneath the humeral head ; this was achieved in 77% (n = 51) of cases.

Two thirds of the patients were assessed clinically and radiologically. Radiological assessment could not be carried out on one third of the patients because they were examined in the nursing home where they were living.

The tuberosities were assessed from radiographs in the true AP view and in the scapular Y-view. Tuberosities were considered healed in the presence of dense bony structures in anatomical position on the middle part of the implant. Tuberosities were classified as "not visible" if no such structures could be observed. It could not be differentiated whether non-visible tuberosities were resorbed or displaced.

The Constant Score (9, 11, 12) and the ASES index (38) were recorded for all patients. A possible correlation of the two scores was tested. The Constant Score was corrected for age and gender according to Kelsch (24).

Correlations between variables were tested with the Pearson correlation test. Multiple variance analyses were carried out to test differences in the Constant Scores for influencing factors. The threshold level of significance was defined as $p < 0.05$. The SAS 9.1 statistical software package (SAS Institute, Cary, NC, USA) was used.

RESULTS

Of the 65 patients, a total of 56 (86%) (49 women, 7 men) with a total of 57 arthroplasties were available for follow-up after an average of 16.4 months. Three patients died (none of the deaths were treatment related) and 4 patients could not be contacted because they had relocated. Two patients declined participation in the follow-up due to dementia. Early complications included one haematoma, one superficial infection, and one secondary displacement.

The results of the 44 radiological controls showed superior subluxation of the prosthetic head in 66% (n = 29) of cases. The tuberosities were not visible on radiographs in 64% (n = 28) of the cases. Glenoid erosion and ossification were observed in

4 and 3 cases, respectively. The implant was changed in two cases of painful ventro-cranial dislocation. Reverse shoulder prosthesis was implanted in both cases (Delta3®, DePuy Orthopädie GmbH). These interventions resulted in almost complete pain relief and acceptable function with 80° abduction and 80° anteversion. However, rotation was substantially poorer.

The mean Constant Score was 50 points, the age- and gender-corrected value 73% (table II). As expected, the Constant Score values was found to decrease with increasing age. The scores of each component of the Constant Score are presented in table III. Pain was minor or absent in 85% of the patients (n = 37). The Constant Score of 62 points in cases with radiologically healed tuberosities is significantly higher than with non-healed tuberosities (47 points, $p = 0.015$) (table IV). Both abduction ($p = 0.01$) and anteversion ($p = 0.006$) were significantly better when the tuberosities were healed. We could not demonstrate a statistically significant relationship between the status of tuberosities and rotation post surgery due to the small sample size. The pain level was not influenced by the status of the tuberosities. Neither age nor the degree of osteoporosis appeared to influence healing of the tuberosities, however gender did. Tuberosities were more likely to heal in men compared to women ($p = 0.0101$). As expected, we detected a correlation between cranial subluxation and the condition of the tuberosities ($p = 0.0027$). An example of a patient with good clinical outcome after arthroplasty and healed tuberosities is given in fig 2.

The self-assessment of the ASES index resulted in a mean score of 68 (range: 23 to 100). Concerning their activities of daily living (ADL), patients experienced little or no impairment in terms of "putting on a jacket", "sleeping on the affected side", "toilet hygiene" and "performance of routine tasks". Activities such as "washing the back", "reaching for high shelves" or "lifting a weight of 4.5 kg above shoulder level" were almost or completely impossible for the patients.

There was a correlation between the Constant Score and the ASES index ($r = 0.77$).

DISCUSSION

The treatment of displaced multifragment humeral head fractures in elderly patients is controversial (18, 25, 42, 46). Although the rate of non-prosthetic complications after primary arthroplasty is low, several authors have reported that the shoulder function after arthroplasty remains limited (1, 3, 4, 25, 40). On behalf of the Cochrane Collaboration, Handoll *et al* (18) reviewed the procedures used to treat proximal humeral fractures in adult patients. Only a few studies were prospective and randomised. No superior therapy was identified (18). Healing of the tuberosities appears to be a key factor to achieve good functionality. Several studies have confirmed the statistical significance of the correlation between the Constant Score, the subjective satisfaction level, and function (1, 25, 27, 34, 40, 49, 51). Most authors report a large amount of secondarily displaced, partially or completely resorbed tuberosities. In these cases, the functional outcome was poor and sometimes ventral and/or cranial dislocation of the prosthesis occurred (4, 27, 34, 42, 49). Boileau *et al* (3) underlined that the outcome after surgery for three- or four-part fractures is unpredictable, often poor, and worse than that following arthroplasty performed for osteoarthritis. They also reviewed several European and US studies using the Neer prosthesis or similar systems and came to the conclusion that the outcomes were rather poor (3).

The outcome of any treatment might be jeopardised by severe damage to the blood supply of the humeral head during trauma (21, 42). Nevertheless, the surgical technique is very important because it is likely to be at least partly responsible for the rate of healing. The fixation of the tuberosities on the middle part of the prosthesis must be stable but should not hinder blood supply. Under these conditions a lasting integration with bony consolidation can be achieved.

The correction for age and gender allows for better assessment of the Constant Score, especially in elderly female patients (9, 24), and makes it possible to compare results from populations with varying demographics. Our results are consistent with those of other authors (1, 43, 27). Boileau *et al* (2) reported

a mean Constant Score of 56 (range : 20 to 95). Loew *et al* (27) reported a mean absolute Constant Score of 51.9 points and a corrected score of 75% respectively. The mean Constant Score in our study was 50. The Constant Score corrected for age and gender was 73%.

This explains the substantial difference between the non-corrected and the age- and gender-corrected values in the present investigation. Some of the components of the Constant Score (ROM and strength) show rather moderate values, which impacts the overall score negatively. The score of these components is always restricted in a population with advanced age, such as the one studied here.

The self-assessment questionnaire of the ASES showed that patients were largely capable of performing activities of daily living, but that they had difficulties with more demanding tasks. The clear reduction of pain after implant surgery confirms findings from other studies (1, 6, 16, 22, 24, 25, 27, 37, 40, 41, 42, 51, 52).

Overall, full range of motion is achieved less frequently than pain reduction. In our study it can be assumed that the lower range of motion correlates with non-healed tuberosities and cranial subluxation of the humeral head. This was noted in approximately two thirds of the radiological controls, and concurs with observations that loss of fixation of the greater tuberosity is the main reason behind poor clinical results (4, 9, 25, 44). With the prosthesis used in this study, good anatomical position of the tuberosities can be achieved through re-fixation to the middle part of the implant. The tuberosities should initially be fixed to each other and thereafter to the shaft with non-absorbable sutures.

In a biomechanical testing, Frankle *et al* (13) noted that a voluminous middle part and an irregular surface are also necessary to obtain stability. They further observed improved stabilisation of the tuberosities when using an encircling wire linked to the central part of the prosthesis (13). In the case of ARTICULA®, rotational stability is achieved with sutures going through the holes in the middle part (fig 1). The suture should run through the subscapularis tendon medially and through the infraspinatus tendon laterally and be tied together laterally.

Table II. — Constant Score with respect to age and gender

Age group	N	Mean	SD	LS Mean	Corrected for age and gender (%)	Median	Min	Max
91-100	2	34	16.3	20	64	34	22	45
81-90	14	45	15.3	47	69	43	19	69
71-80	23	54	20.0	63	78	52	13	87
61-70	15	52	15.4	54	70	50	20	92
< 61	2	58	7.8	63	76	58	52	63
Total	56	50	17.6	—	73	50	13	92

Table III. — Distribution for components of the Constant Score

Components from Constant Score and Point Range	Mean	Median	Min	Max
Pain (0 – 15)	12	10	0	15
ADL (0 – 20)	13	12	3	20
ROM (0 – 40)	16	16	2	36
Strength (0 – 25)	10	8	1	25
Total (0 – 100)	50	50	13	92

Table IV. — Outcome according to dissolved / not dissolved tuberosities

	Dissolved	Not dissolved	p value
Mean Constant Score	48	62	0.0149*
Pain (from CS)			
None	10	8	0.6442
Mild	13	6	
Moderate	5	2	
Strong	0	0	
Mean Abduction	55°	90°	0.01*
Mean Anteversion	62°	96°	0.006*
Gender f / m	27 / 1	1 / 5	0.0101*
Age			
< 61	1	1	0.9598
61 - 70	6	4	
71 - 80	14	7	
+ 81	7	7	
Cranial subluxation			
Yes	23	6	0.0027*
no	5	10	
Osteoporosis			
No	1	1	0.8151
Moderate	10	7	
Strong	16	8	

* statistically significant ($p < 0.05$).

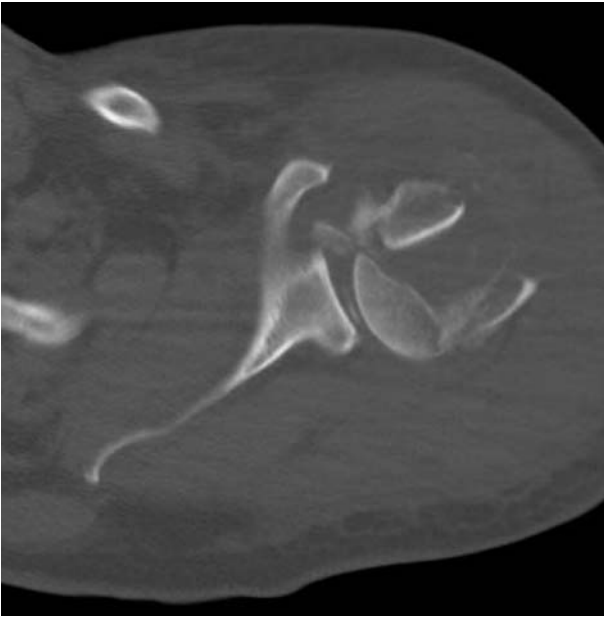


Fig. 2a. — Non-reconstructible 4-part fracture on the left side.

The exact height- and rotation adjustment of the prosthesis together with the stable fixation of the tuberosities are the basis to achieve a good clinical outcome (2, 17). Furthermore, early displacement and loosening of the tuberosities leading to resorption can be prevented if these criteria are attained.

When reconstruction of the shoulder joint is no longer an option and arthroplasty becomes inevitable, a careful operative technique is fundamental to maintain good blood supply to the tuberosities. If the trauma or surgical trauma leads to irreversible damage to the blood supply, dissolution of the tuberosities will result and lead to a comparatively poorer function.

The objective of the surgical technique is to obtain an anatomical and stable reconstruction, respecting fracture biology as much as possible, as this creates optimal conditions for anatomical healing of the tuberosities. Procedures allowing for rapid fixation by bony ongrowth to the central part of the prosthesis are a possible approach to improve the functional results.

There are a few limitations to the study. First, this was not a multicenter study ; recruitment was limited and the number of patients was small, as in

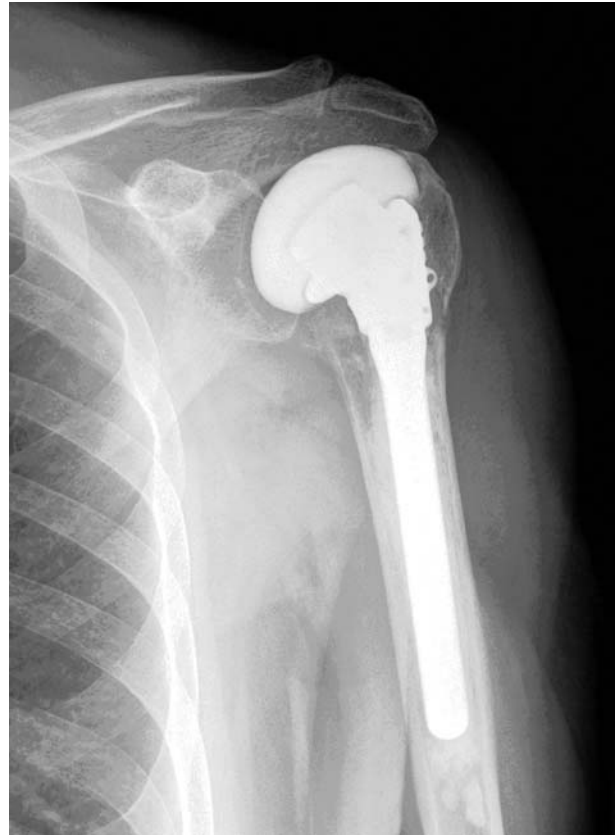

Fig. 2b. — Follow-up after 12 months with the tuberosities assessed as healed.

many previous reports. In addition, the high average age of the patients led to a relatively high dropout rate, but this is also similar to other studies dealing with shoulder arthroplasty for acute fracture.

Besides, the heterogeneous trauma situation led to a difficult classification of fractures and indication for the arthroplasty. Finally, the outcome (healed versus non-healed) of the tuberosities was based on radiographs only, but not all patients had radiographs. This led to a further decrease in follow-up numbers. Furthermore, the quality of the radiographs did not allow for differentiation between displacement and resorption of non visible tuberosities. This evaluation could have been improved by using CT-scans, but the higher exposure to x-rays only for study purpose was judged to be ethically unacceptable.

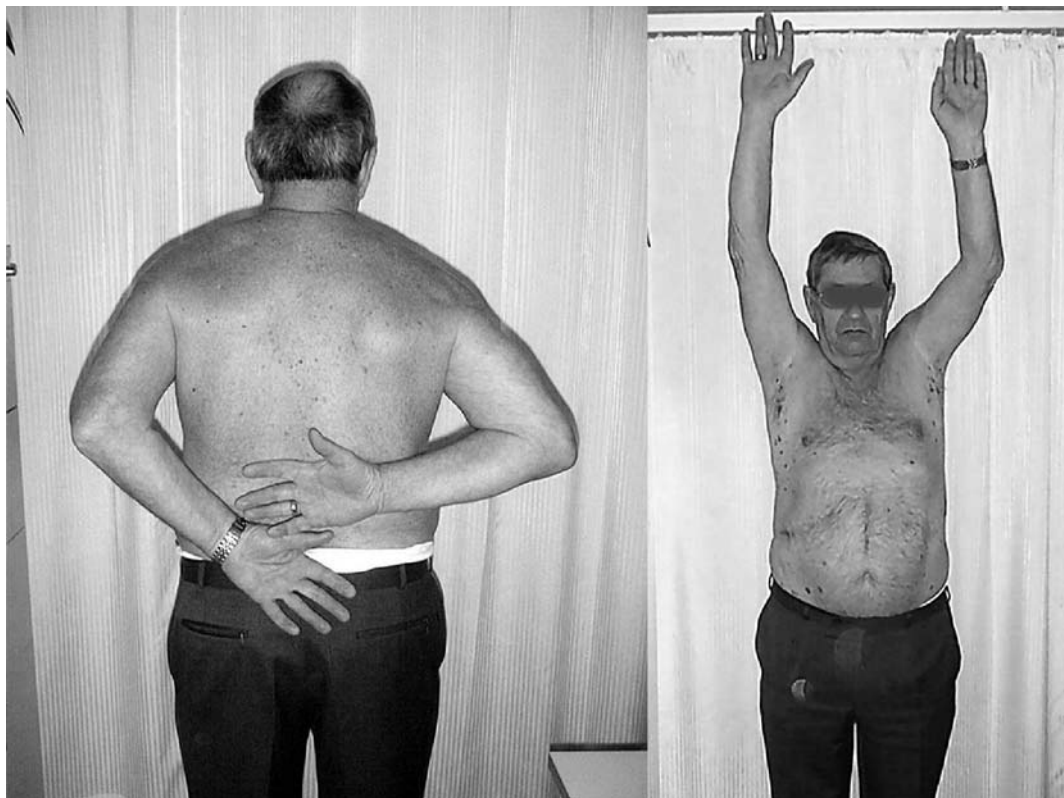

Fig. 2c. — Free range of motion for internal rotation and anteversion with a Constant Score of 81 points and an ASES Score of 87 points.

The strength of this study lies in its prospective nature and the fact that all patients have been operated on and followed-up according to the same criteria in the same centre.

CONCLUSION

Modern trauma shoulder prostheses are suitable to manage non-reconstructible humeral head fractures. The results achieved are a direct function of the healing of the tuberosities. Most patients can become almost pain-free, irrespective of the healing of the tuberosities. Patients can perform activities of daily living without help, and return to a familiar environment after one single operation. This is particularly important for elderly patients. Tuberosity resorption and suboptimal functional recovery remain major problems even with an improved tuberosity fixation design.

REFERENCES

1. **Ambacher T, Ehrli HJ, Paar O.** [Results of primary hemiarthroplasty in the treatment of displaced fractures of the humeral head] (in German). *Zentralbl Chir* 2000 ; 125 : 750-755.
2. **Boileau P, Krishnan SG, Tinsi L et al.** Tuberosity malposition and migration : reason for poor outcomes after hemiarthroplasty for displaced fractures of the proximal humerus. *J Shoulder Elbow Surg* 2002 ; 11 : 401-412.
3. **Boileau P, Sinnerton RJ, Chuinard C, Walch G.** Arthroplasty of the shoulder. *J Bone Joint Surg* 2006 ; 88-B : 562-575.
4. **Boileau P, Trojani C, Walch G et al.** Shoulder arthroplasty for the treatment of the sequelae of fractures of the proximal humerus. *J Shoulder Elbow Surg* 2001 ; 10 : 299-308.
5. **Boileau P, Tinsi L, LeHouc JC et al.** Results of shoulder arthroplasty in acute fractures of proximal humerus. In : Walch G, Boileau P (eds). *Shoulder Arthroplasty*. Springer, Berlin, Heidelberg, New York, 1999, pp 331-345.
6. **Bosch U, Skuttek M, Fremerey W, Tscherné H.** Outcome after primary and secondary arthroplasty in elderly

- patients with fractures of the proximal humerus. *J Shoulder Elbow Surg* 1998 ; 7 : 479-484.
7. **Boss AP, Hintermann B.** Primary endoprosthesis in comminuted humeral head fractures in patients over 60 years of age. *Int Orthop* 1999 ; 23 : 172-174.
 8. **Cofield RH.** Comminuted fractures of the proximal humerus. *Clin Orthop* 1988 ; 230 : 49-57.
 9. **Compito CA, Self EB, Bigliani LU.** Arthroplasty and acute shoulder trauma : reasons for success and failure. *Clin Orthop* 1994 ; 307 : 27-36.
 10. **Constant CR.** Age related recovery of shoulder function after injury [thesis]. Cork (Ireland) : University College 1986.
 11. **Constant CR, Murley AH.** A clinical method of functional assessment of the shoulder. *Clin Orthop* 1987 ; 214 : 160-164.
 12. **Constant CR.** Assessment of shoulder function. In : Copeland SA (ed). *Shoulder Surgery*. WB Saunders, Philadelphia, 1997 ; pp 56-64.
 13. **Frankle MA, Ondrovic LE, Markee BA et al.** Stability of tuberosity reattachment in proximal humeral hemiarthroplasty. *J Shoulder Elbow Surg* 2002 ; 11 : 413-420.
 14. **Gerber C, Hersche O, Berberat C.** The clinical relevance of posttraumatic avascular necrosis of the humeral head. *J Shoulder Elbow Surg* 1998 ; 7 : 586-590.
 15. **Gerber Ch, Schneeberger AG, Vinh TS.** The arterial vascularisation of the humeral head ; an anatomic study. *J Bone Joint Surg* 1990 ; 72-A, 1486-1494.
 16. **Goldman RT, Koval KJ, Cuomo F et al.** Functional outcome after humeral head replacement for acute three- and four-part proximal humeral fractures. *J Shoulder Elbow Surg* 1995 ; 4 : 81-86.
 17. **Habermeyer P, Ebert T.** [Current status and perspectives of shoulder replacement] (in German). *Unfallchirurg* 1999 ; 102 : 668-683.
 18. **Handoll HHG, Gibson JNA, Madhok R.** Interventions for treating proximal humeral fractures in adults (Cochrane Review). In : *The Cochrane Library*, Issue 2, Chichester, UK : John Wiley & Sons, Ltd. 2004.
 19. **Harvie P, Pollard TCB, Chennagiri RJ, Carr AJ.** The use of outcome scores in surgery of the shoulder. *J Bone Joint Surg* 2005 ; 87-B : 151-154.
 20. **Hente R, Kampshoof J, Kinner B et al.** [Treatment of dislocated 3- and 4-part fractures of the proximal humerus with an angle-stabilizing fixation plate] (in German) *Unfallchirurg* 2004 ; 107 : 769-782.
 21. **Hertel R, Hempfing A, Stiehler M, Leunig M.** Predictors of humeral head ischemia after intracapsular fracture of the humerus. *J Shoulder Elbow Surg* 2004 ; 13 : 427-433.
 22. **Hoellen IP, Bauer G, Holbein O.** [Prosthetic humeral head replacement in dislocated humerus multi-fragment fracture in the elderly – an alternative to minimal osteosynthesis] (in German). *Zentralbl Chir* 1997 ; 122 : 994-1001.
 23. **Kannus P, Palvanen M, Niemi S et al.** Osteoporotic fractures of the proximal humerus in elderly Finnish persons : sharp increase in 1970-1998 and alarming projections for the new millennium. *Acta Orthop Scand* 2000 ; 71 : 465-470.
 24. **Kelsch G, Gmelich B, Deffner P, Ulrich C.** [Clinical results of prosthetic replacement of the humeral head in multi-fragment fractures of the humeral head] (in German). *Osteo Trauma Care* 1999 ; 7 : 216-220.
 25. **Kralinger F, Schwaiger R, Wambacher M et al.** Outcome after primary hemiarthroplasty for fracture of the head of the humerus. *J Bone Joint Surg* 2004 ; 86-B : 217-219.
 26. **Lill H, Bewer A, Korner J et al.** [Conservative treatment of displaced fractures of the proximal humerus] (in German). *Zentralbl Chir* 2001 ; 126 : 205-210.
 27. **Loew M, Heitkemper S, Parsch D et al.** Influence of the design on the outcome after hemiarthroplasty of the shoulder in displaced fractures of the head of the humerus. *J Bone Joint Surg* 2006 ; 88-B : 345-350.
 28. **Mathews J, Lobenhoffer P.** [Results of the provision of unstable proximal humeral fractures in geriatric patients with a new angle stabilizing antegrade nail system] (in German). *Unfallchirurg* 2004 ; 107 : 372-380.
 29. **Movin T, Sjoden GO, Ahrengart L.** Poor function after shoulder replacement in fracture patients. A retrospective evaluation of 29 patients followed for 2-12 years. *Acta Orthop Scand* 1998 ; 69 : 392-396.
 30. **Neer CS.** Displaced proximal humeral fractures. Part II. Treatment of three and four part displacement. *J Bone Joint Surg* 1970 ; 52-A : 1090-1103.
 31. **Neer CS 2nd, McIlveen SJ.** Humeral head replacement with reconstruction of the tuberosities and the cuff in 4-fragment-displaced fractures. Current results and techniques. *Rev Chir Orthop* 1988 ; 74 Suppl 2 : 31-40.
 32. **Neer CS 2nd.** Displaced proximal humerus fractures. Part I. Classification and evaluation. *J Bone Joint Surg* 1970 ; 52-A : 1077-1089.
 33. **Neer CS, Rockwood CA.** Fractures and dislocations of the shoulder. In : Rockwood CA, Green DP (eds). *Fractures*. 2nd ed. Philadelphia. 1984, J.B. Lippincott, pp 675-707.
 34. **Povacz P, Podlaha A, Aschauer E, Resch H.** [Treatment of proximal fractures of the arm with the HAS prosthesis] (in German). *Europ J Trauma E-Suppl.* 2001 ; 1 : 133-136.
 35. **Resch H.** [Fractures of the humeral head] (in German). *Unfallchirurg* 2003 ; 106 : 602-617.
 36. **Resch H, Povacz P, Frohlich R, Wambacher M.** Percutaneous fixation of three- and four-part fractures of the proximal humerus. *J Bone Joint Surg* 1997 ; 79-B : 295-300.
 37. **Reuther F, Wahl D, Bärwolff F.** [The fracture prosthesis ARTICULA – Clinical experience] (in German). *5th European Trauma Congress*, 04-08-05. 2002, Wien.
 38. **Richard P, Albassir A, Litt R et al.** Hemi-arthroplasty of the shoulder : radiological, functional and dynamic studies. *Acta Orthop Belg* 1995 ; 61 Suppl 1 : 124-133.

39. **Richards RR, An KN, Bigliani LU et al.** A standardized method for the assessment of shoulder function. *J Shoulder Elbow Surg* 1994 ; 3 : 347-352.
40. **Robinson CM, Page RS, Hill RM et al.** Primary hemiarthroplasty for treatment of proximal humeral fractures. *J Bone Joint Surg* 2003 ; 85-A : 1215-1223.
41. **Rüter A.** [Indication and technique for shoulder endoprostheses in fractures] (in German). *Chirurg* 2001 ; 72 : 1246-1252.
42. **Schmal H, Klemt C, Südkamp NP.** [Evaluation of shoulder arthroplasty in treatment of four-fragment fractures of the proximal humerus] (in German). *Unfallchirurg* 2004 ; 107 : 575-582.
43. **Stableforth PG.** Four-part fractures of the neck of the humerus. *J Bone Joint Surg* 1984 ; 66-B : 104-108.
44. **Tanner MW, Cofield RH.** Prosthetic arthroplasty of fractures of the proximal humerus. *Clin Orthop* 1983 ; 179 : 116-128.
45. **Thomas M, Dieball O, Busse M.** [Normal values of the shoulder strength in dependency on age and gender – comparison with the Constant, UCLA, ASES scores and SF36 health survey] (in German). *Z Orthop* 2003 ; 141 : 160-170.
46. **Tingart M, Bähris H, Bouillon B, Tilling Th.** [The displaced proximal humeral fracture : is there evidence for therapeutic concepts ?] (in German). *Chirurg* 2001 ; 72 : 1284-1291.
47. **Wahl D, Reuther F.** [First clinical experience and early results in treatment of fractures of the proximal humerus with the Trauma Shoulder Prosthesis ARTICULA] (in German). In : W. Neumann, R. Ascherl (eds). *Hüft- und Schulterendoprothetik, Materialien und klinische Ergebnisse. Buchreihe für Orthopädie und orthopädische Grenzgebiete*, Band 18, Medizinisch Literarische Verlagsgesellschaft mbH, Uelzen. 2001 ; S 64-68.
48. **Walch G, Boileau P.** Prosthetic adaptability : A new concept for shoulder arthroplasty. *J Shoulder Elbow Surg* 1999 ; 8 : 443-451.
49. **Wiedemann E, Brunner U, Hauptmann S, Mutschler W.** [Prosthesis implantation in fractures of the humeral head] (in German). *Operat Orthop Traumatol* 2004 ; 16 : 1-27.
50. **Willems WJ, Lim TE.** Neer arthroplasty for humeral fracture. *Acta Orthop Scand* 1985 ; 56 : 394-395.
51. **Wretenberg P, Ekelund A.** Acute hemiarthroplasty after proximal humeral fracture in old patients. A retrospective evaluation of 18 patients followed for 2-7 years. *Acta Orthop Scand* 1997 ; 68 : 121-123.
52. **Zyto K, Wallace WA, Frostick SP, Preston BJ.** Outcome after hemiarthroplasty for three and four-part fractures of the proximal humerus. *J Shoulder Elbow Surg* 1997 ; 7 : 85-89.