



## Bicortical K-wires for distal radius fracture fixation : How many ?

Harish V. KURUP, Vipul MANDALIA, Anthony SHAJU, Adrian BEAUMONT

*From Salisbury District Hospital, Salisbury, Wiltshire, United Kingdom*

The aim of this study was to find out whether number and position of K-wires influence the stability of distal radius fractures treated by percutaneous wire fixation. Patients who underwent K-wire fixation for unstable fractures of the distal radius over a period of three years were included in this retrospective study. Radiographs taken immediately after the procedure and radiographs taken after removal of K-wires were analysed to study three radiological parameters : palmar or dorsal tilt, radial inclination and ulnar variance. Loss of these angles was analysed statistically against the number of wires (2 or 3) and position of wires (from radial styloid or a combination of styloid and dorsal wires). Ninety-five fractures were analysed with a mean age of 52.8 years and male to female ratio of 1:2. Average loss of radial inclination was 5.2°, loss of palmar tilt was 8.3° and loss of ulnar variance was 3.4 mm. Using 3 wires or using a dorsal wire in addition to the styloid wires both improved the final radial length by 1.2 mm and 2 mm respectively, but the effects were statistically not significant. We found that the number or position of wires did not influence radiological outcome. Based on our findings we recommend the use of two K-wires : one from the radial styloid and one from the dorsal side for these fractures.

**Keywords :** distal radius fracture ; K-wire fixation ; dorsal ; styloid.

### INTRODUCTION

Fractures of the distal radius are the most common of all orthopaedic injuries, accounting for

nearly 20% of all fractures presenting to the emergency department (11). Malunion of distal radius fractures leads to posttraumatic arthritis, mid carpal instability and pain (9). Conservative treatment of minimally displaced and stable fractures of the distal end of the radius in elderly patients usually shows a good outcome but the treatment of severely displaced and unstable fractures has been controversial. The functional results in patients with significant radial shortening are poor. Fujii *et al* (3) recommended reduction of these fractures even in elderly patients. Percutaneous pinning is a simple, minimally invasive technique and is aimed at preventing redisplacement of the fragments. Wires can be introduced either percutaneous across the fracture or intrafocally into the fracture site. Percutaneous wires can be introduced from the radial styloid or dorsally. Most surgeons use two or three wires. The aim of our study was to find out

---

■ Harish V. Kurup, MRCS, Specialist Registrar in Orthopaedics.

*Royal Glamorgan Hospital, Llantrisant, United Kingdom.*

■ Vipul Mandalia, FRCS, Specialist Registrar in Orthopaedics.

■ Anthony Shaju, FRCS, Registrar in Orthopaedics.

■ Adrian Beaumont, FRCS, Consultant in Orthopaedics.

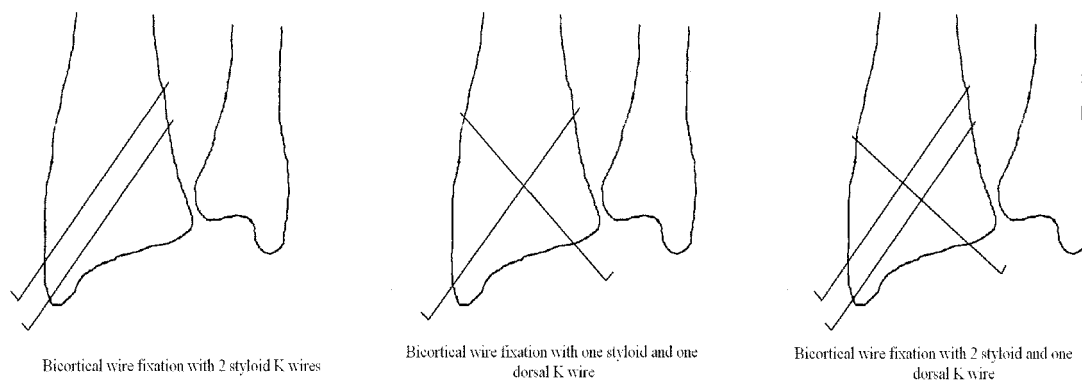
*Salisbury District Hospital, Salisbury, United Kingdom.*

Correspondence : Harish V. Kurup, Royal Glamorgan Hospital, Llantrisant, CF72 8XR, United Kingdom.

E-mail : harishvk@yahoo.com.

© 2007, Acta Orthopædica Belgica.

---



**Fig. 1.** — Bicortical K-wire fixation for distal radius fracture : types of wire placement

whether the number or position of wires affects radiological outcome in these fractures.

#### MATERIALS AND METHODS

Ninety-five patients who underwent Kirschner wire (K-wire) fixation for distal radius fractures in our department from June 2000 to May 2003 were included in this retrospective study. Palmar tilt, radial inclination and ulnar variance were measured in these patients on plain radiographs (6). Extra-articular fractures of Colles type and intra-articular fractures except Barton type were included in this study. Fractures were classified using the AO classification. The exclusion criteria were paediatric fractures, additional procedures like external fixation, and non-availability of satisfactory and comparable radiographs for measurement. Only bicortical K-wire fixations with radial or dorsal entry points were included in this study. Eighteen cases were excluded because of use of intrafocal or intramedullary wires to supplement fixation. The number of K-wires used and the position of these depended on the preferences of the individual operating surgeon. All operations were carried out by consultants or registrars with appropriate experience. K-wires were removed in the outpatient clinic usually between 4-6 weeks.

Male : female ratio was 1:2. The mean age of patients was 52.8 years (range : 18 to 86). We divided patients into two groups depending on the number of K-wires used for fixation : those who had 2 wires and those who had 3 (fig 1). Seventy-six patients had fixation with 2 wires and 19 had 3 wires. Both groups were similar in terms of age, sex and fracture type distribution (table II). They had similar results in terms of maintenance of

reduction during the period of wire fixation (table III). Depending on the position of K-wires the patients were again divided into two groups, one group had styloid wires only (28 patients) and the second group (67 patients) had a combination of styloid and dorsal wires. Both groups were similar in terms of age, sex and fracture types (table IV).

The loss of palmar tilt, radial inclination, and ulnar variance were measured from radiographs done immediately after the procedure and radiographs done after wire removal. These were scored according to the radiological scoring system proposed by Stewart *et al* (14) (table I). The anatomical results were classified as excellent, good, fair or poor based on these scores. The results were tabulated and statistically analysed using SPSS software package (SPSS Inc, Chicago, IL, USA). Anatomical results were analysed using the Chi-Square test and loss of angles using the Mann-Whitney test. A p value of < 0.05 was considered significant for the purposes of this study.

#### RESULTS

Of the 95 patients, 25 (26.4%) graded excellent on the Stewart system, 52 patients (52.6%) graded good, 16 (16.8%) were graded fair and 4 (4.2%) had a poor outcome. Mean loss of dorsal tilt was 8.6°, radial inclination 5.2° and ulnar variance 3.3 mm.

The 3 wires group had a mean loss of radial length (ulnar variance) of 2.5 mm compared to 3.7 mm in the 2 wires group, but this was not statistically significant. (p value : 0.665). Depending

Table I. — Assessment of radiological / anatomical result (14)

Final Dorsal Tilt (Degrees)	Neutral / Volar	1-10	11-14	15+
Loss of Ulnar Variance (mm)	0-3	4-6	7-11	12+
Loss of radial Inclination (Degrees)	0-4	5-9	10-14	15+
Score for each	0	1	2	4

Grades : 0 Excellent, 1 to3 Good, 4 to 6 Fair, 7 to12 Poor.

Table II. — Two versus three K-wires

Number of K-wires used	Number of patients	Age (years) Mean (range)	Male : Female	Extra-articular fractures (AO type A)	Intra-articular fractures (AO type C)
2 wires	76	53.4 (18-86)	1:2.3	41	35
3 wires	19	50.4 (18-85)	1:2.1	7	12
p value (Chi-Square test)				0.1822	

Table III. — Number of K-wires and results

Number of K-wires used	Results – Number (%)				Loss of angles Mean (Range)		
	Excellent	good	fair	poor	Dorsal Tilt (degrees)	Radial Inclination (degrees)	Ulnar variance (mm)
2 wires	18 (23.7%)	41 (54%)	14 (18.3%)	3 (4%)	8.0 (0-35)	5.2 (0-29)	3.7 (0-26)
3 wires	7 (37%)	9 (47.3%)	2 (10.5%)	1 (5.2%)	9.4 (0-34)	5.1 (0-15)	2.5 (0-7)
p value	0.625				0.830	0.228	0.665
	<i>Chi- square test</i>				<i>Mann-Whitney test</i>		

Table IV. — Wire position and patients

K-wire construct used	Number of patients	Age : Mean (range)	Male : Female	Extra-articular fractures (AO type A)	Intra-articular fractures (AO type C)
Styloid wires only	28	53.4 (20-85)	1 : 2.5	11	17
Combination of styloid and dorsal	67	51.2 (18-86)	1 : 2.2	38	29
p value ( Chi-Square test)				0.1211	

on the position of K-wires both groups of patients had similar radiological results (table V). The use of dorsal wires in addition to styloid wires reduced loss of radial length by 2 mm (from 4.8 to 2.8 mm) but this again was statistically insignificant (p value : 0.249).

## DISCUSSION

Abraham Colles (2) first described the Colles fracture in 1814 and stated “one consolation only remains that the limb will at some remote period again enjoy perfect freedom in all its motions and

Table V. — Position of K-wires and results

K-wire construct used	Results – Number (%)				Loss of angles Mean (Range)		
	Excellent	good	fair	poor	Dorsal Tilt (degrees)	Radial Inclination (degrees)	Ulnar variance (mm)
Styloid wires only	8 (28.5%)	11 (39%)	7 (25%)	2 (7.5%)	8.8 (0-26)	4.6 (0-11)	4.8 (0-19)
Both styloid and dorsal wires	17 (25.3%)	39 (58.2)	9 (13.5%)	2 (3%)	8.1 (0-35)	5.4 (0-29)	2.8 (0-26)
<i>p value</i>	0.284				0.361	0.056	0.249
	<i>Chi-square test</i>				<i>Mann-Whitney test</i>		

be completely exempt from pain ; the deformity however will remain undiminished through life". The different surgical techniques for treating fractures of the distal radius are aimed at reducing this final deformity to ensure better anatomical results especially in more severe fractures. Most distal radial fractures are uncomplicated and effectively treated with closed reduction and immobilisation in a cast. The goal of treatment is to restore the functional anatomy by a method that does not compromise hand function. The important factors to consider are fracture pattern, displacement, stability of fracture, age and physical demands of the patient (11).

Various modalities of treatment for distal radius fracture are described in the literature and the four methods generally followed in treating these fractures are :

1. Conservative treatment in plaster cast with or without manipulative reduction,
2. K-wire fixation to maintain reduction while in plaster,
3. External fixation (bridging or non-bridging),
4. Open reduction and internal fixation.

There is no general consensus regarding the indications, advantages and disadvantages of each of these treatment methods (4). Percutaneous wire fixation is an excellent technique provided the distal radius is not severely comminuted or osteoporotic. It is especially useful for unstable fractures both extra articular and intra articular sometimes in combination with other modes of fixation (11). The

bicortical wire fixation technique was first reported by Stein and Katz (13) in 1975 and further refined by Clancey (1) in 1984. K-wires are placed through the radial styloid and / or dorsally to aid in fixation. Alternatively they may be placed intrafocally as in Kapandji's technique (7). Few randomised controlled trials have compared K-wiring techniques for distal radius fractures (8, 15), but they have failed to show any significant difference in outcome between the different techniques.

Cross pinning with two radial styloid pins and placement of a pin from the ulnar corner of the radius is described to be the most rigid construct biomechanically (10). Radial styloid wires have a high incidence of iatrogenic injury to the superficial radial nerve (12). We found that using a combination of styloid and dorsal wires does not compromise the stability of fixation and it may be advisable to keep the number of styloid wires to a minimum to reduce risk of nerve injury. Use of an additional dorsal wire may even reduce the loss of radial length (by 2 mm) even though this was found to have statistically insignificant association. We did not examine the incidence of superficial radial nerve injury in our study, but three or two percutaneous wires over the radial styloid will definitely increase the risk compared to two or one respectively.

K-wires, especially when left outside the skin, have a high incidence of pin tract infection (5). Pin tract infection, even though of little consequence, can rarely result in septic arthritis and definitely increases cost of treatment by requiring additional

hospital attendance and dressing change. Limiting the number of wires may reduce the risk of infection, nevertheless will definitely reduce implant costs. We found that using two wires gave to the distal radius the same stability as three wires. Fixation with three wires in fact improved the final radial length (mean loss of ulnar variance of 2.5 mm compared to 3.7 mm with two wires), but this was statistically insignificant. It cannot be ignored that a third wire gave an extra 1.2 mm final radial length but based on available evidence it can be concluded that this extra length is unlikely to improve the final outcome (14).

The limitations of our study were that being a retrospective study, we had to exclude patients without comparable radiographs for measurements and that we did not investigate into the functional outcome in these patients. It is also possible that sample size has influenced our results and a larger study group would have given more definite answers to the questions raised.

### CONCLUSION

K-wire fixation for unstable fractures of the distal radius is a good technique to prevent redisplacement. Using 3 wires or using a dorsal wire in addition to a styloid wire both improved the final radial length, but the effect was statistically insignificant. We found that the number or position of wires did not influence radiological results. We therefore recommend the use of two K-wires : one from the radial styloid and one from the dorsal side for these fractures.

### REFERENCES

1. **Colles A.** On the fracture of the carpal extremity of the radius. *Edinb Med Surg J* 1814 ; 10 : 181. In : *Clin Orthop* 2006 ; 445 : 5-7.
2. **Clancey GJ.** Percutaneous Kirschner-wire fixation of Colles fractures. A prospective study of thirty cases. *J Bone Joint Surg* 1984 ; 66-A : 1008-1014.
3. **Fujii K, Henmi T, Kanematsu Y et al.** Fractures of the distal end of radius in elderly patients : a comparative study of anatomical and functional results. *J Orthop Surg (Hong Kong)* 2002 ; 10 : 9-15.
4. **Handoll HH, Madhok R.** Surgical interventions for treating distal radial fractures in adults. *Cochrane Database Syst Rev* 2003 : CD003209.
5. **Hargreaves DG, Drew SJ, Eckersley R.** Kirschner wire pin tract infection rates : a randomized controlled trial between percutaneous and buried wires. *J Hand Surg* 2004 ; 29-B : 374-376.
6. **Hollevoet N, Verdonk R.** The functional importance of malunion in distal radius fractures. *Acta Orthop Belg* 2003 ; 69 : 239-245.
7. **Kapandji A.** Intra-focal pinning of fractures of the distal end of the radius 10 years later. *Ann Chir Main* 1987 ; 6 : 57-63.
8. **Lenoble E, Dumontier C, Goutallier D, Apoil A.** Fracture of the distal radius. A prospective comparison between trans-styloid and Kapandji fixations. *J Bone Joint Surg* 1995 ; 77-B : 562-567.
9. **Miyake T, Hashizume H, Inoue H et al.** Malunited Colles' fracture. Analysis of stress distribution. *J Hand Surg* 1994 ; 19-B : 737-742.
10. **Naidu SH, Capo JT, Moulton M et al.** Percutaneous pinning of distal radius fractures : a biomechanical study. *J Hand Surg* 1997 ; 22-A : 252-257.
11. **Simic PM, Weiland AJ.** Fractures of the distal aspect of the radius : changes in treatment over the past two decades. *Instr Course Lect* 2003 ; 52 : 185-195.
12. **Singh S, Trikha P, Twyman R.** Superficial radial nerve damage due to Kirschner wiring of the radius. *Injury* 2005 ; 36 : 330-332.
13. **Stein AH Jr, Katz SF.** Stabilization of comminuted fractures of the distal inch of the radius : Percutaneous pinning. *Clin Orthop* 1975 ; 108 : 174-181.
14. **Stewart HD, Innes AR, Burke FD.** Factors affecting the outcome of Colles' fracture : an anatomical and functional study. *Injury* 1985 ; 16 : 289-295.
15. **Strohm PC, Muller CA, Boll T, Pfister U.** Two procedures for Kirschner wire osteosynthesis of distal radial fractures. A randomized trial. *J Bone Joint Surg* 2004 ; 86-A : 2621-2628.