



Evaluation of lung cancer metastases to the spine

Ufuk AYDINLI, Cagatay OZTURK, Sami BAYRAM, Sureyya SARIHAN, Turkkkan EVRENSEL, Halil Sedat YILMAZ

From Department of Orthopedics and Traumatology, Spine Surgery Unit, Uludag University Medical School, Bursa, Turkey

Most metastatic spinal lesions (70%) are found at the thoracic level, 20% in the lumbar region, and 10% in the cervical region. A variety of benign and malignant tumours may arise in the lung, but the vast majority is bronchogenic carcinomas (90 to 95%). The aim of this study was to evaluate the lung cancer metastases to the vertebral column in terms of type, localisation and metastasis pattern.

Between the years 1995 and 2003, 168 lung cancer patients with metastatic spinal tumour who had received radiotherapy and chemotherapy were retrospectively evaluated.

The total number of vertebrae in which metastases were detected was 328. The most common site for metastasis was the thoracic spine. In 49 (29%) patients, there was only one vertebral involvement. Additional extravertebral bony metastases were present in 37 (22%) patients; the femur (20 patients) was the most common site. Only 25 of 168 patients were operated due to spinal cord compression leading to neurological deficit. The rest of the patients were treated by appropriate chemotherapy and radiotherapy protocols. The mean survival after diagnosis of vertebral metastasis was 7.1 months.

Squamous cell carcinoma and adenocarcinoma are the lung cancers that mostly metastasise to vertebrae. Most of the metastases involve multiple spinal levels. After the diagnosis of vertebral metastasis, the mean survival is seven months. Pain relief and maintaining quality of life must be balanced with the patient's life expectancy, comorbidities and immunological, nutritional and functional status in treatment decision.

Keywords : lung cancer ; metastases ; spine ; treatment.

INTRODUCTION

The spinal column is the most frequent site of bony metastasis (1, 23). Metastatic spinal disease is a significant problem for a large number of cancer patients. Between 5% and 10% of all cancer patients develop spinal metastases during the course of their disease (4). Approximately 40% of individuals dying of cancer will have autopsy evidence of spinal metastases (2, 4, 18) and 10% of these will develop spinal cord compression with

■ Ufuk Aydinli, MD, Professor.

■ Halil Sedat Yilmaz, MD, Consultant.

Department of Orthopaedic Surgery, Uludag University Medical School, Bursa, Turkey.

■ Cagatay Ozturk, MD, Consultant.

Turkish Armed Forces Rehabilitation and Care Center, Ankara, Turkey.

■ Sami Bayram, MD, Consultant.

Department of Thoracic Surgery, Uludag University Medical School, Bursa, Turkey.

■ Sureyya Sarihan, MD, Consultant.

Uludag University Medical School, Department of Radiation Oncology, Bursa, Turkey.

■ Turkkkan Evrensel, MD, Associate Professor.

Department of Medical Oncology, Uludag University Medical School, Bursa, Turkey.

Correspondence : Cagatay Ozturk, MD, Orthopaedic Surgeon, Turkish Armed Forces Rehabilitation and Care Center, Bilkent, Ankara, Turkey.

E-mail : rezocagatay@hotmail.com.

© 2006, Acta Orthopædica Belgica.

subsequent neurological deficits (26, 31). Bony metastases to the spine are a frequent event in breast, prostate, lung, kidney, urinary bladder and thyroid cancer as well as in multiple myeloma and other haematological malignancies which may, however, be considered as primary tumours. In adults, 60% of spinal metastases are either from breast, lung, or prostate cancer. Renal and gastrointestinal malignancies each account for about 5% of spinal metastases, and thyroid carcinomas and melanomas occur with a lesser frequency (5, 16).

There is a slight preponderance of metastatic spinal tumours in males (60%) compared to females (11). Spinal metastases may occur in all age groups, but the period of highest prevalence coincides with the relatively high cancer risk period of 40 to 65 years of age (7).

Metastatic spread to bone may be related to osteotropism of the malignant cells, direct spread, and/or the high vascular supply of bone marrow (1). Batson *et al* have demonstrated that the vertebral venous plexus draining the thoracic, abdominal, and pelvic viscera (Batson's plexus) is a route of metastases to the spine (6).

Most metastatic spinal lesions (70%) are found at the thoracic level, 20% in the lumbar region, and 10% in the cervical region (14). The increased frequency of spinal metastases in the thoracic vertebrae may be related to the greater number of thoracic vertebrae, compared to the lumbar and cervical regions. Metastatic lesions occur at multiple noncontiguous levels in 10% to 38% of cases (14, 22, 24).

In almost 10% of cases of newly diagnosed spinal metastases, the patient is not known to have cancer, and spinal cord compression is the initial symptom of the malignancy (30). Half of these patients are subsequently found to have lung cancer. The time between the original diagnosis of cancer and the occurrence of spinal metastases varies widely.

The treatment of patients with metastatic disease of the patient is controversial. The conservative treatment is weighted against surgical options, which are indicated in the presence of progressive neurological deficit. Pain relief and maintenance of quality of life must be balanced with the patient's

life expectancy, comorbidities, immunological, nutritional and functional status.

A variety of benign and malignant tumours may arise in the lung, but the vast majority is bronchogenic carcinomas (90 to 95%). These types of tumours are divided into four major categories; squamous cell carcinoma, adenocarcinoma, small cell carcinoma and large cell carcinoma. Lung cancer occurs between the ages of 40 and 70 years, with a peak incidence in the late fifties or early sixties.

In this study, we aimed to evaluate the lung cancer metastases to the spine in terms of type, localisation and metastasis pattern.

MATERIALS AND METHODS

One hundred and sixty eight lung cancer patients with metastatic spinal tumour who had received radiotherapy and chemotherapy between the years 1995 and 2003, were retrospectively evaluated. There were 146 (87%) men and 22 (13%) women with a mean age of 57 years (range; 24 to 87 years). The mean age was 58 years among men and 53 years among women.

The diagnosis of vertebral metastasis was established based on a history of primary lung cancer, physical examination revealing pain and neurological complaints, plain spinal radiographs, magnetic resonance imaging and transpedicular vertebral biopsy under local anaesthesia.

Level of spinal metastasis, number of vertebrae involved, presence of extravertebral metastasis, histological type of lung cancer metastasis, mean survival time after diagnosis of vertebral metastasis and treatment modality were recorded.

RESULTS

The distribution of pathological diagnosis of the patients was as follows; squamous cell carcinoma in 81 (48%) patients, adenocarcinoma in 52 (31%) patients, small cell carcinoma in 25 (15%) patients and large cell carcinoma in 10 (6%) patients. The most common type was squamous cell carcinoma in males (71 patients, 49%) and adenocarcinoma in females (11 patients, 50%) (table I).

The total number of vertebrae in which a metastasis was detected was 328. One hundred and

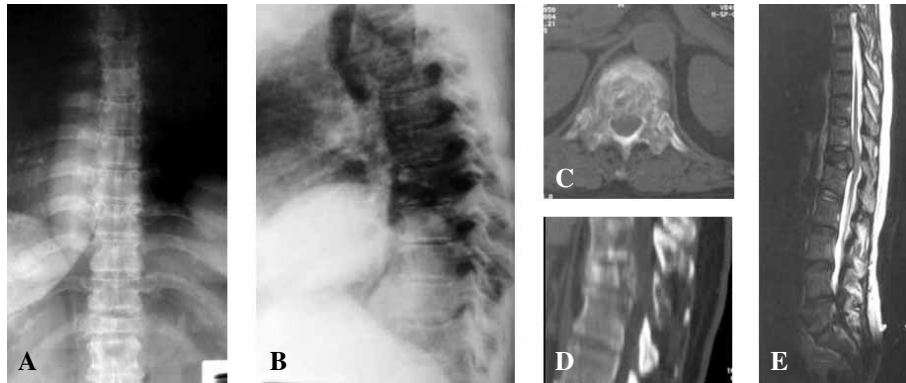


Fig. 1. — A 67-year-woman with T12 metastatic lung cancer of small cell carcinoma type. She had no neurological deficit and she underwent radiotherapy rather than surgery. (A) Anteroposterior and (B) lateral plain radiographs show the compression of the T12 vertebra. Axial (C) and sagittally reconstructed (D) CT scans show vertebral destruction with minimal spinal canal compression, and sagittal MRI (E) shows the lesion.

Table I. — Distribution of pathological diagnoses

Histological diagnosis	n	%
Squamous cell carcinoma	81	48
Adenocarcinoma	52	31
Small cell carcinoma	25	15
Large cell carcinoma	10	6
Total	168	100

eighty-eight of them (57%) were thoracic, 105 (32%) were lumbar, 23 (7%) were cervical and 12 (4%) were sacral in localisation. The most common site for metastasis was the thoracic spine (table II) (fig 1).

In 49 (29%) patients, there was only one vertebral involvement. In the remaining 119 (71%) patients, vertebral metastases were multiple (contiguous in 77 (46%) patients and noncontiguous or skipped in 43 (25%) patients). The most common metastasis was to T9 level in the thoracic region and L3 in the lumbar region, with percentages of 16 and 28% respectively.

Additional extravertebral bony metastases were present in 37 (22%) patients: the femur (20 patients) was the most common site, followed by the humerus (8 patients), the pelvis (5 patients), the scapula (2 patients) and the cranial bones (2 patients) (table III).

Table II. — Distribution of vertebrae in which a metastasis was detected

Localisation	n	%
Cervical	23	7
Thoracic	188	57
Lumbar	105	32
Sacral	12	4
Total	328	100

Table III. — Distribution of extravertebral bony metastases in the patients

Site of extravertebral bony metastasis	n	%
Femur	20	12
Humerus	8	5
Pelvis	5	3
Scapula	2	1
Cranial bones	2	1
Total	37	22

Only 25 of 168 patients were operated due to spinal cord compression leading to a neurological deficit. The other patients were treated by appropriate chemotherapy and radiotherapy protocols. The mean survival after diagnosis of vertebral metastasis was 7.1 months (range ; 1 to 24 months).

DISCUSSION

Malignant metastatic cells most frequently spread to the spine haematogenously with tumour emboli following the paravertebral plexus (plexus of Batson) (6, 10, 27, 34), which is characterised by absence of valves. It is postulated that the venous blood return is shifted into the paravertebral plexus via the intervertebral and basivertebral veins due to increased intra-abdominal and intrathoracic pressure. As a result metastases, which follow this pathway, result in the characteristic pattern of bony spread because tumour cells are seeded by this mechanism into the capillary network of the vertebral bodies. Spread from the primary tumour also occurs by the arterial route via the nutrient artery or by direct invasion through the intervertebral foramina. Due to its avascular nature, the disc is usually spared from tumour involvement: however, the most frequently and severely affected part of the vertebra is the vertebral body (in about 80%) followed by the pedicles and the posterior elements. Tumours of the lung seed the vertebral column through arterial dissemination; for this reason, most lung cancer metastases occur in the vertebral body due to its abundant red bone marrow and high vascularity.

Lung cancers may involve the spine by direct invasion from a pulmonary or a chest wall mass or by true metastasis. Spinal metastases are often multiple and are frequently seen late in the course of the disease, when brain or visceral metastases are also evident. Of the types of lung cancer, only adenocarcinomas are often encountered by surgeons as a surgical disease. Small cell carcinoma of the lung is almost certainly a systemic disease, which rarely causes massive bony destruction or instability of the spine. It is relatively radiosensitive and patients get benefit from radiotherapy.

Squamous cell carcinomas are highly aggressive malignancies that frequently metastasise to the spine. The patients generally have massive vertebral destruction, anterior and posterior involvement, and multisegmental disease at the time of diagnosis. The tumour is usually radioresistant, and surgery must sometimes be attempted to preserve function. However, life expectancy is usually

measured in months. Adenocarcinoma of the lung frequently behaves in an intermediate fashion between the small cell and squamous cell varieties.

The classical autopsy investigations have demonstrated that the distribution of spine metastases is related to the size of the vertebra. Thus, metastatic lesions are most commonly located in the lumbar region, less so in the thoracic spine, and least often in the cervical spine (13). On the other hand, some reports pointed out that about 70% of symptomatic lesions were found in the thoracic spine, 20% in the lumbar spine and 10% in the cervical spine (3, 14).

The clinical presentation of metastatic spine disease is predominantly pain, neurological deficit, progressive deformity, and general weakness. Pain may be localised to a certain structure and region of the spine and may be of radicular or medullary origin. The pain is either caused by increased intraosseous pressure in the vertebral bodies due to cellular invasion of the cancellous bone, by compression of neural structures such as roots or nervous fibers, by a secondary instability due to the osteoligamentous destruction of parts of the axial skeleton, or by infiltration of the dura or other neuroanatomical structures.

Pain is the most common presenting symptom in patients with metastatic spinal tumours (12, 14, 15). The aetiology of pain may be tumour spread, spinal instability, nerve root or dural irritation, or direct cauda equina or spinal cord compression. Pain may also be related to bony destruction or invasion of paraspinal tissues, such as muscles or ligaments (33).

Patients with spinal metastases frequently describe the pain as a dull, constant ache and often complain that the pain awakens them during sleep (12). Occasionally, the pain will occur in a radicular distribution, which may be caused by nerve root irritation. Muscular weakness is frequently manifested by the progressive inability to ambulate or the loss of limb function. The patient's ability to walk at the time of presentation is a sensitive predictor of the ability to walk after surgery (29).

In the diagnostic work up, plain radiographs can show spinal alignment, the presence of a fracture,

and gross areas of bone involvement by the tumour. Spinal metastatic lesions from lung cancer are osteolytic and 30% to 60% of the bone must be destroyed for a lytic lesion to be appreciated on plain radiographs (8, 36). More than 70% of patients with spinal cord compression have an abnormal plain radiograph in the region of pain (compression fracture, deformity, or lytic metastasis).

Magnetic resonance imaging (MRI) is now the method of choice to detect the presence and extent of spinal metastases (9, 15, 17, 19, 21). It provides excellent visualisation of soft-tissue involvement, bone marrow replacement, ligamentous involvement, spinal cord oedema, and degree of canal compromise and cord compression (28). Magnetic resonance imaging has the further advantage of being able to image the entire spine ; this may be especially helpful because multiple lesions that are not suspected clinically are found in up to 30% of cases (25).

Computerised tomography (CT) remains an important imaging tool in the evaluation of patients with spinal metastases (22). Axial CT images provide excellent bony detail of the spinal canal and vertebral bodies and can help determine whether canal compromise is due to bone or soft tissue (20, 32). The integrity of vertebral elements that may be required for internal fixation, such as pedicles and lamina, can also be determined (35). Computed tomographic scanning may be reserved for patients who cannot undergo MRI scanning for reasons such as the presence of a cardiac pacemaker.

A thorough metastatic workup is of paramount importance in patients with spinal metastasis. This helps to delineate the nature and the extent of the systemic disease ; however, the appropriateness of diagnostic tests depends on the amount of time available. In patients with rapidly progressing symptoms, chest radiograph and physical examination is all that is permitted. The patient should then have a plain radiograph of the entire spine, followed by MRI with and without contrast.

No treatment has been proven to increase the life expectancy of patients with lung cancer and spinal metastasis. The goals of therapy are pain control and function preservation. The ability to ambulate at the time of presentation is a favourable prognos-

tic sign. Loss of sphincter control is a poor prognostic feature and is mostly irreversible. Conservative treatment (chemotherapy and radiotherapy) must be weighted against surgical options. Pain relief and maintenance of quality of life must be balanced against the patient's life expectancy, presence of comorbidities, immunological, nutritional and functional status.

Radiation therapy is more effective in achieving pain control than surgery (3, 13). Notably, surgery alone is the least effective way to treat spinal metastases. About 20-26% of patients who undergo surgery experience further deterioration in terms of either mobility or sphincter control while only 17% in the radiation therapy group experience further deterioration (3, 13). Surgical intervention with extensive reconstruction should be employed only after thorough evaluation of the extent of the systemic disease and with a clear understanding of the realistic expectation of the patients and their care-takers.

In patients with lung cancer metastases to the spine, therapeutic methods need to be selected carefully, taking into account the condition of the patient. When treating patients whose paralysis is rapidly progressive, it is essential to determine the necessity of surgery as soon as possible. Even when surgery is selected, the extent of surgical intervention should be as limited as possible. Radiotherapy and chemotherapy should be considered first in the treatment of patients with vertebra metastasis of lung cancer as their survival rate is short and the rate of multiple metastases is high.

REFERENCES

1. **Aaron AD.** The management of cancer metastatic to bone. *JAMA* 1994 ; 15 : 1206-1209.
2. **Abrams HL, Spiro R, Goldstein N.** Metastases in carcinoma : Analysis of 1,000 autopsied cases. *Cancer* 1950 ; 3 : 74-85.
3. **Aebi M.** Spinal metastasis in the elderly. *Eur Spine J* 2003 ; 12 (Suppl 2) : S202-S213.
4. **Barron KD, Hirano A, Araki S et al.** Experiences with metastatic neoplasms involving the spinal cord. *Neurology* 1959 ; 9 : 91-106.
5. **Bartanusz V, Porchet F.** Current strategies in the management of spinal metastatic disease. *Swiss Surg* 2003 ; 9 : 55-62.

6. **Batson OV.** The function of vertebral veins and their role in the spread of metastases. *Ann Surg* 1940 ; 112 : 138-149.
7. **Black P, Nair S, Giannakopoulos G.** Spinal epidural tumors, in Wilkins RH, Rengachary SS (eds): *Neurosurgery*. McGraw-Hill, New York, 1996 : pp 1791-1804.
8. **Boland PJ, Lane JM, Sundaresan N.** Metastatic disease of the spine. *Clin Orthop* 1982 ; 169 : 95-102.
9. **Byrne TN.** Spinal cord compression from epidural metastases. *N Engl J Med* 1992 ; 327 : 614-619.
10. **Coman DR, DeLong RP.** The role of the vertebral venous system in the metastasis of cancer into the spinal cord : experiments with tumor cell suspensions in rats and rabbits. *Cancer* 1951 ; 4 : 610-618.
11. **Constans JP, Divitis ED, Donzelli R et al.** Spinal metastases with neurological manifestations : Review of 600 cases. *J Neurosurg* 1983 ; 59 : 111-118.
12. **Elliot K, Foley KM.** Neurologic pain syndromes in patients with cancer. *Neurol Clin* 1989 ; 7 : 333-360.
13. **Gerszten PC, Welch WC.** Current surgical management of metastatic spinal disease. *Oncology* 2000 ; 14 : 1013-1024.
14. **Gilbert RW, Kim J-H, Posner JB.** Epidural spinal cord compression from metastatic tumor : Diagnosis and treatment. *Ann Neurol* 1978 ; 3 : 40-51.
15. **Grant R, Papadopoulos SM, Sandler HM et al.** Metastatic epidural cord compression : Current concepts and treatment. *J Neurooncol* 1994 ; 19 : 79-92.
16. **Groot MT.** Costs of prostate cancer metastasis to the bone in The Netherlands. *Eur Urol* 2003 ; 43 : 226-232.
17. **Harnsberger HR, Dillon WP.** The radiologic role in diagnosis, staging, and follow-up of neoplasia of the brain, spine, and head and neck. *Semin Ultrasound CT MR* 1989 ; 10 : 431-452.
18. **Harrington KD.** The use of methylmethacrylate for vertebral-body replacement and anterior stabilization of pathological fracture-dislocations of the spine due to metastatic malignant disease. *J Bone Joint Surg* 1981 ; 63-A : 36-46.
19. **Jones JM, Schwartz RB, Mantello MT et al.** Fast spin-echo MR in the detection of vertebral metastases : Comparison of three sequences. *Am J Neuroradiol* 1994 ; 15 : 401-407.
20. **McAfee PC, Bohlman HH, Hans JS et al.** Comparison of nuclear magnetic resonance imaging and computed tomography in the diagnosis of upper cervical spinal cord compression. *Spine* 1986 ; 11 : 295-304.
21. **Mehta RC, Marks MP, Hinks S et al.** MR evaluation of vertebral metastases : T1-weighted short-inversion-time inversion recovery, fast spin-echo, and inversion-recovery fast spin-echo sequences. *Am J Neuroradiol* 1995 ; 16 : 281-288.
22. **O'Rourke T, George CB, Redmond J et al.** Spinal computed tomography and computed tomographic metrizamide myelography in the early diagnosis of metastatic disease. *J Clin Oncol* 1986 ; 4 : 576-583.
23. **Ratanatharathorn V, Powers WE.** Epidural spinal cord compression for metastatic tumor : Diagnosis and guidelines for management. *Cancer Treat Rev* 1991 ; 18 : 55-71.
24. **Ruff RL, Lanska DJ.** Epidural metastases in prospectively evaluated veterans with cancer and back pain. *Cancer* 1989 ; 63 : 2234-2241.
25. **Sarpel S, Sarpel G, Yu E et al.** Early diagnosis of spinal epidural metastases by magnetic resonance imaging. *Cancer* 1987 ; 59 : 1112-1116.
26. **Schaberg J, Gainor BJ.** A profile of metastatic carcinoma of the spine. *Spine* 1985 ; 10 : 19-20.
27. **Schick U, Marquardt G, Lorenz R.** Intradural and extradural spinal metastases. *Neurosurg Rev* 2001 ; 24 : 1-5.
28. **Smoker WRK, Godersky JC, Knutson RK et al.** The role of MR imaging in evaluating metastatic spinal disease. *Am J Roentgenol* 1987 ; 149 : 1241-1248.
29. **Sorensen PS, Borgesen SE, Rohde K et al.** Metastatic epidural spinal cord compression : Results of treatment and survival. *Cancer* 1990 ; 65 : 1502-1508.
30. **Stark RJ, Henson RA, Evans SJ.** Spinal metastases : A retrospective survey from a general hospital. *Brain* 1982 ; 105 : 189-213.
31. **Sundaresan N, Digiacinto GV, Hughes JEO et al.** Treatment of neoplastic spinal cord compression : Results of a prospective study. *Neurosurgery* 1991 ; 29 : 645-650.
32. **Vandermark RM, Shpall EJ, Affronti ML.** Bone metastases from breast cancer : Value of CT bone windows. *J Comput Assist Tomogr* 1992 ; 16 : 608-614.
33. **Villavicencio H.** Quality of life of patients with advanced metastatic prostatic carcinoma. *Eur Urol* 1993 ; 24 (S) : 118-121.
34. **Vinholes J, Coleman R, Eastell R.** Effects of bone metastases on bone metabolism : implications for diagnosis, imaging and assessment of response to cancer treatment. *Cancer Treat Rev* 1996 ; 22 : 289-331.
35. **Welch WC, Jacobs GB.** Surgery for metastatic spinal disease. *J Neurooncol* 1995 ; 23 : 163-170.
36. **Wong DA, Fornasier VL, MacNab I.** Spinal metastases : The obvious, the occult, and the impostors. *Spine* 1990 ; 15 : 1-4.