



Stabilisation of a posteriorly unstable glenohumeral joint during total shoulder arthroplasty : A novel capsulorrhaphy technique

George M. KONTAKIS, Magdalini TOZAKIDOU, John KARANTINOS

Department of Orthopaedics-Traumatology, University of Crete, Greece

Restoration of the soft tissue balance is of great importance during shoulder arthroplasty. We report a novel technique of posterior capsulorrhaphy through an anterior approach for the management of intraoperative posterior instability during implantation of the prosthesis. After the operation, the patients were able to follow a rehabilitation program with some minor restrictions, avoiding the necessity of a shoulder spica or other constrictive measures. This technique is simple, safe and sufficient to address instability due to abundance of the posterior shoulder capsule.

Keywords : capsulorrhaphy ; posterior instability ; shoulder arthroplasty.

INTRODUCTION

It is well known that restoration of the soft tissue balance is of great importance during shoulder arthroplasty, whatever the indication. This is usually achieved by proper soft tissue release and application of the modularity concept of the implanted prosthesis. After soft tissue release and preparation for the implantation of the prosthesis, the selection of a bigger head may be enough to achieve the proper soft tissue balance. The surgeon pushes the prosthetic head with his thumb in an antero-posterior (AP) direction while it faces the glenoid. A 30% posterior translation is desired but removal of the thumb pressure must produce automatic

relocation of the head. In third-generation prostheses, where the selected prosthetic head size is dependent on the cut surface of the humeral head – to reproduce a head as close to normal as possible – the alternative for the surgeon to select another bigger head to increase tension of the soft tissues does not exist.

In cases with abundance of the posterior capsule the surgeon may be faced with the difficult problem to maintain stability in the AP direction before the completion of the procedure, and the reconstruction of the anterior tissues. It should be mentioned that this concerns especially cases where the posterior instability is the result of soft tissue problems rather than of bony deficiencies (such as deficiencies of the glenoid bone), a more complex situation.

■ George M. Kontakis, MD, Assistant Professor of Orthopaedics.

■ Magdalini Tozakidou, MD, Erasmus Student.

■ John Karantinos, MD, Registrar in Orthopaedics.

Department of Orthopaedics-Traumatology, University of Crete, Greece.

Correspondence : George M. Kontakis, MD, 1 Pindarou Street, 713 05 Heraklion Crete, Greece.

E-mail : kontak@med.uoc.gr.

© 2006, Acta Orthopædica Belgica.

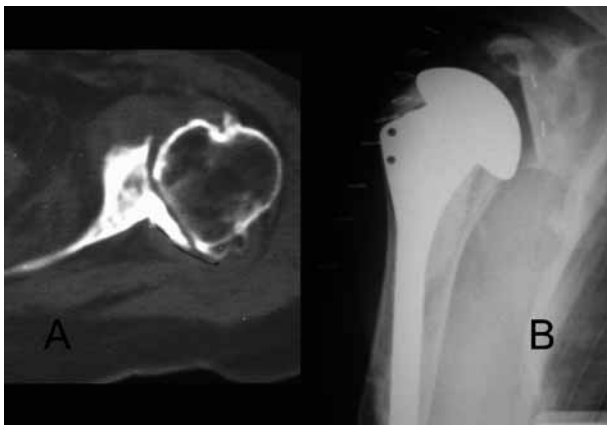


Fig. 1. — A 73-year-old woman with degenerative glenohumeral arthritis ; **A.** Preoperative CT scan of the left shoulder showing the arthritis and the large posterior osteophyte ; **B.** Postoperative true AP radiograph showing the normal relation between the prosthetic implant surfaces.

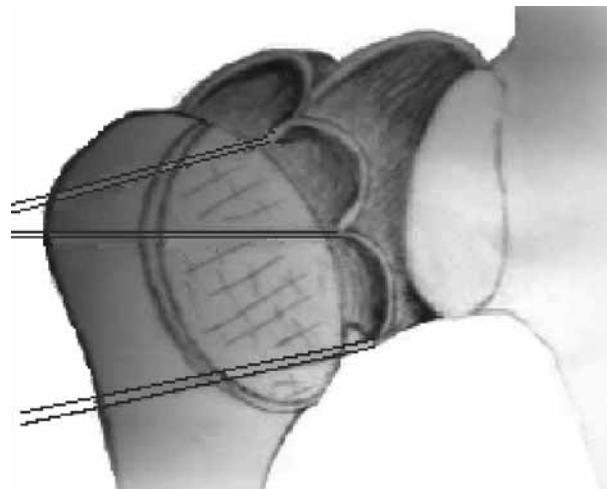


Fig. 2. — Three sutures are placed in the posterior capsule in one line from its upper aspect to its inferior part.

CASE PRESENTATION

Case 1

The first patient was a 73-year-old woman with degenerative glenohumeral arthritis, who was treated with total shoulder arthroplasty (fig 1). The posterior instability of the implanted prosthesis during surgery was due to the removal of large posterior glenoid osteophytes, which had attenuated the posterior capsule.

Case 2

The second patient was a 44-year-old woman with an old posteriorly locked shoulder dislocation with a severely damaged humeral head. Total shoulder arthroplasty was decided. Posterior instability was noticed during the intraoperative trial reduction of the shoulder with the temporarily fixed humeral implant. This was attributed to the abundance of the posterior capsule because of the chronic head displacement.

SURGICAL TECHNIQUE

Three no. 5 absorbable sutures were used to gather the posterior capsule from the posterior to

the antero-lateral direction. The first suture was placed in the middle of the upper part of the posterior capsule ; the second was placed in the middle, and the third in the lower part of the posterior capsule, avoiding the capsule below the inferior border of the teres minor. All sutures were placed in the midline of the posterior capsule, sufficiently lateral to the glenoid surface (fig 2). During trial reduction and with the humeral head facing the glenoid, the 3 pairs of sutures were tensioned and the upper 2 were passed over the top of the trial humeral head and the 3rd inferiorly relative to the head. The AP stability was checked via the classic manoeuvre (thumb pressure is applied on the trial head) and any adaptation of the proper rotation of the humerus – in order to achieve the desired and allowed translation – was determined. In both cases this occurred in about 15-20 degrees of external rotation. The desired tension of the sutures was determined by using a marking pencil to label the sutures in their junction with the outer edge of the trial head. During the cementation of the final implant the tensioned sutures were secured underneath the head, between its flat surface and the bone (with interference of cement) (fig 3). Additionally, after cement polymerisation, the sutures were secured by tying a knot between them. The closure of the open subscapularis and the

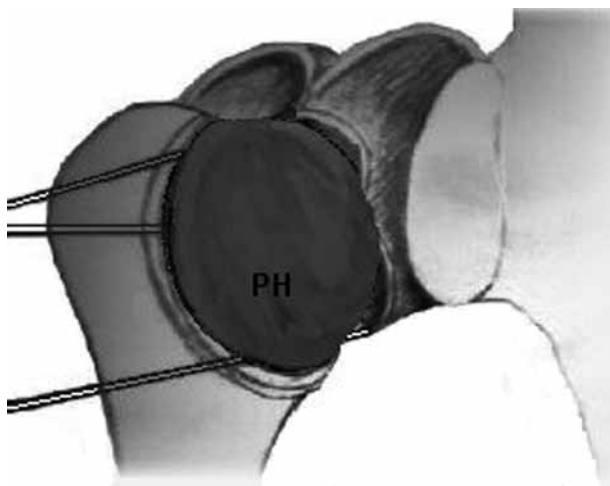


Fig. 3. — After determination of the proper tension, the sutures are secured between the prosthetic head (PH) and the osteotomised surface of the upper humerus (2 pairs above and one pair below the stem level). A knot between them will provide more safety.

rotator interval contributed to greater stability in the AP direction. After surgery the forearm was put in a sling with the elbow flexed 90° and the arm to the side. With the patients in the erect position, gentle passive flexion in neutral rotation was permitted immediately after the first postoperative day and no more than 5° of external rotation and no internal rotation were permitted earlier than 3 weeks post-surgery. After 6 weeks the capsule was considered healed and free motion was permitted. Postoperative radiographs were performed once a week during the first 3 weeks, in order to check that the good head position was maintained. Both patients recovered without any instability and gained more shoulder motion than their preoperative one in the entire spectrum. During the 12 months of follow-up the shoulders remained stable.

DISCUSSION

Namba and Thornhill (2) presented a case of intra-operative shoulder prosthesis instability where posterior capsulorrhaphy was performed. They used heavy non-absorbable no 5 suture and secured the posterior capsule through 2 pairs of bony holes at the upper part of the humerus. Together with the posterior capsule they included in their sewing superficial parts of the infraspinatus and teres minor muscles.

Mestdagh *et al* (1) developed a technique of posterior capsulorrhaphy using absorbable sutures (no 5) and passing them through the subscapularis, in cases with a large posterior capsular pouch. Two sutures are passed in the posterior capsular pouch before inserting the definitive prosthesis. These sutures are then passed through the subscapularis before suturing the tendon. The sutures are tied at the end of the operation with the arm in external rotation, and are resorbed within 6 weeks.

Our technique of posterior capsulorrhaphy is a simple one and seems to work efficiently. It provides enough stability during the early postoperative period and does not affect the rehabilitation. The technique is safe, because it avoids the danger of producing nerve injury as long as the vulnerable suprascapular and axillary nerves are located about 2 cm medial to the glenoid and inferior to the teres minor respectively. It is a valuable method helping the surgeon to solve the difficult problem of posterior instability during shoulder arthroplasty.

REFERENCES

1. Mestdagh H, Boileau P, Walch G. Intra- and postoperative complications of shoulder arthroplasty. In: Walch G, Boileau P (eds). *Shoulder Arthroplasty*, Springer-Verlag, Berlin Heidelberg, 1999, pp 405-417.
2. Namba RS, Thornhill TS. Posterior capsulorrhaphy in total shoulder arthroplasty. *Clin Orthop* 1995 ; 313 : 135-139.