



Multifocal osteonecrosis predominantly affecting the knees secondary to chronic alcohol ingestion : A case report and review

Richard ROACH, David MILLER, David GRIFFITHS

From the University Hospital of North Staffordshire, Stoke-on-Trent, United Kingdom

We present a case of multifocal osteonecrosis secondary to alcohol ingestion in a middle aged lady, after the exclusion of other causal factors. It presented initially with knee pain and subsequently necessitated arthroplasty ; other areas became more problematic. This condition is rare and we present a literature review that reveals that after steroids the suspected link to alcohol is not so obvious. A high index of suspicion is required and treatment remains expectant and symptomatic. The role of screening is also discussed.

Keywords : knee ; osteonecrosis ; multifocal.

INTRODUCTION

When three or more joints are affected with osteonecrosis, a diagnosis of multifocal osteonecrosis can be made. Steroids are the commonest cause of this condition. Alcohol abuse is the commonest substance misuse in the western world. Despite this, multifocal osteonecrosis related to alcohol intake is relatively rare. It is still unclear which patients are at particular risk of developing this condition although it is known that the quantity of alcohol intake is a factor. We present a case to highlight the effect of excess alcohol and the subsequent management of osteonecrosis affecting the knees predominantly.

CASE REPORT

A 57-year-old lady presented with increasing generalised right knee pain, stiffness and activity related joint line discomfort. Radiographs revealed marked destruction of the articular surfaces of the knee with increased radiodensity of the distal third of the femur extending from the joint line (fig 1 a, b). Further radiographs suggested medullary infarction confirmed by magnetic resonance imaging (MRI) (fig 2). Questioning revealed chronic alcohol ingestion in excess of 50 units per day over many years. A full blood screen including clotting profile and auto-antibodies was normal. The AP hip radiograph was also normal. Conservative measures failed quickly and arthroplasty of the knee was performed, resulting in relief of symptoms. A left knee arthroplasty followed soon after.

-
- Richard Roach, MD, Specialist Registrar.
 - David Miller, MD, Specialist Registrar.
 - David Griffiths, MD, Consultant Orthopaedic Surgeon.

Department of Trauma and Orthopaedic Surgery, University Hospital of North Staffordshire, Stoke-on-Trent, ST4 7LN, United Kingdom.

Correspondence : David Miller, Flat 12, St. James Place, 34 George Road, Edgbaston, Birmingham, B15 1PQ, United Kingdom. E-mail : dvmill@aol.com.

© 2005, Acta Orthopædica Belgica.

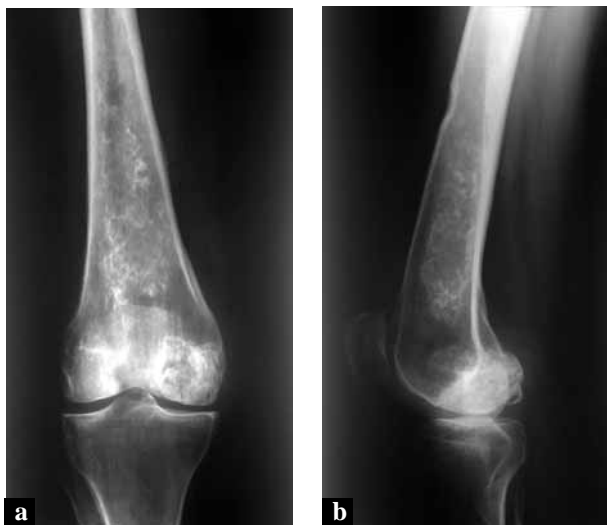


Fig. 1a & b. — AP and lateral radiographs of knee and distal femur.

Subsequently, generalised aches and pains became more prevalent, localised especially to both the hips and ankles and the back. Radiographs remained normal and therefore a bone scan was performed. This demonstrated non-specific increased activity in both acetabuli, a degenerative pattern affecting the lumbar spine and carpometacarpal joint of the dominant thumb as well as changes of the right talar dome consistent with avascular necrosis. The femoral and humeral heads were normal.

At present the knee replacements are satisfactory at two years and treatment of the remaining areas is symptomatic with a plan for regular radiographic review. Alcohol abstinence has also been successfully achieved.

DISCUSSION

Avascular osteonecrosis is a distinct entity, the majority of cases being idiopathic or secondary to steroids or alcohol intake (2, 4). There are numerous less common associations, all resulting in a final common pathway via a fat cell or increased intraosseous pressure hypotheses. These include coagulopathies, dysbaria, trauma, inborn errors of

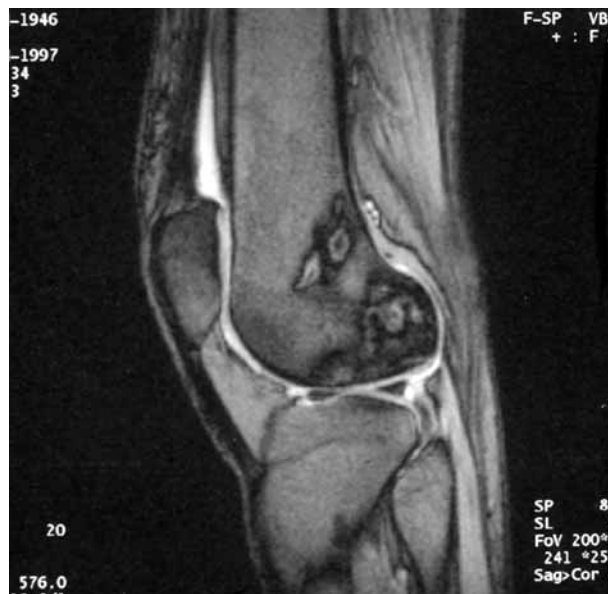

Fig. 2. — T2 weighted MRI demonstrating endosteal and epiphyseal osteonecrosis.

metabolism, connective tissue disorders and chronic pulmonary or renal disease (8, 10). The focus of necrosis is usually distinct, being either medullary with the typical chimney smoke appearance, or osteochondral.

Multifocal osteonecrosis occurs when three or more sites are affected (3, 9). The Collaborative Osteonecrosis Group confirmed that steroids are the primary cause in 91% (1, 5). Excessive alcohol ingestion however is surprisingly not well reported. Gold and Cangemi (2) in 1979 prospectively collated data on cases of known alcohol dependence attending for support. Sixteen percent had visible changes on single AP hip radiographs. This was consistent with earlier work by most other authors. They also questioned the direct correlation to alcohol. Orlic *et al* (7) in 1990 reported an incidence of osteonecrosis in 5.3% of alcoholics, with 6.1% of these being multifocal.

The exact levels of alcohol and its intake characteristics have not been defined. Recent work uses the Japanese Orthopaedic Association threshold for osteonecrosis of 400 ml of 100% alcohol per week (6). This level is used by all coworkers involved in the collaborative multicentre study of symptomatic multifocal osteonecrosis which

published its main work in 1999 (5). This involved 21 centres in a retrospective review of 101 cases during 1980-1996. Overall 3% of cases of osteonecrosis were deemed to be multifocal, with steroid usage prevalent in 91%, unrelated to dose, and 12% with a coagulopathy. Systemic Lupus Erythematosus (SLE) was the top comorbidity (38%). All cases involved the femoral heads with the knee in 96%, the shoulder in 80% and the ankle in 44% being the next most common. Seven other sites were reported with an average of 6.2 sites per person. Only 10% met the alcohol threshold. Unfortunately cases due solely to alcohol in this study are not clarified further. Recommendations included a high index of suspicion and screening of the most common areas due to a high level of sub-clinical early pathology.

Our case had definite osteonecrosis affecting three sites with negative bone scan for the femoral and humeral heads, which is atypical. It is also unusual to have medullary infarction combined with such extensive osteochondral degeneration. There was no suggestion of a neuropathy. As the symptoms remain tolerable, regular review is based on plain radiographs with a plan for an MRI if any deterioration occurs, in view of its improved sensitivity.

With improved imaging and experience, this condition will be elucidated further. This will also help clarify speculation in the literature as to whether cases previously thought to be osteoarthritic in nature are actually osteonecrotic. Improved data collection and imaging will also

enable further stratification of the disorder. The definite link to alcohol remains to be clearly proven. At present the prognosis is guarded and the mainstay of treatment is symptomatic with education and lifestyle modification.

REFERENCES

1. **Collaborative Osteonecrosis Group** : Symptomatic multifocal osteonecrosis. *Clin Orthop* 1999 ; 369 : 312-326.
2. **Gold EW, Cangemi PJ**. Incidence and pathogenesis of alcohol-induced osteonecrosis of the femoral head. *Clin Orthop* 1979 ; 143 : 222-226.
3. **Jacobs B**. Epidemiology of traumatic and nontraumatic osteonecrosis. *Clin Orthop* 1978 ; 130 : 51-67.
4. **Koch CA, Tsigos C, Patronas NJ, Papanicolaou**. Cushing's disease presenting with avascular necrosis of the hip : An orthopaedic emergency. *JCEM* 1999 ; 84 : 3010-3012.
5. **LaPorte DM, Mont MA, Mohan V et al**. Multifocal osteonecrosis. *J Rheumatol* 1998 ; 10 : 1968-1973.
6. **Matsuo K, Hirohata T, Sugioka Y et al**. Influence of alcohol intake, cigarette smoking, and occupational status on idiopathic osteonecrosis of the femoral head. *Clin Orthop* 1988 ; 234 : 116-123.
7. **Orlić D, Jovanović S, Antičević D, Zešević J**. Frequency of idiopathic aseptic necrosis in medically treated alcoholics. *Int Orthop* 1990 ; 14 : 383-386.
8. **Rodrigue SW, Rosenthal DI, Barton NW et al**. Risk factors for osteonecrosis in patients with Type 1 Gaucher's disease. *Clin Orthop* 1999 ; 362 : 201-207.
9. **Taylor LJ**. Multifocal avascular necrosis after short-term high-dose steroid therapy. A report of three cases. *J Bone Joint Surg* 1984 ; 66-B : 431-433.
10. **Zhang LD, Kang JF, Xue HL**. Distribution of lesions in the head and neck of the humerus and femur in dysbaric osteonecrosis. *Undersea Biomed Res* 1990 ; 17 : 353-358.