



Is percutaneous repair of the Achilles tendon a safe technique ? A study of 124 cases

Renaud MAES, Gerard COPIN, Christophe AVEROUS

*From the Clinique Louis Caty, Baudour, Belgium
and the Centre de Traumatologie et d'Orthopédie de Strasbourg, Strasbourg, France*

Ma and Griffith first described in 1977 a percutaneous technique for the repair of acute Achilles tendon rupture. In 1992, Delponte popularised a new percutaneous technique with Tenolig®.

The authors report a series of 124 cases of Achilles tendon rupture treated with Tenolig® in their institution from 1993 to 1998. There were 79 men and 45 women. The mean age was 41.5 years, with a peak from 30 to 39 years. The rupture occurred during sports activities in 69 cases. The mean duration of follow-up was 1.9 years.

Surgical complications noted were : unbending of one of the harpoon wires in 5 cases, rupture of the harpoon wire in one case and tendon re-rupture in 12 cases. The rate of re-rupture was similar to the rate noted with conservative treatment (10%). Skin necrosis at the entrance wound was noted in 10 cases, and injury of the sural nerve in 8 cases. Full weight-bearing without crutches was regained for 95% of patients within 3 months.

In conclusion, this report shows a high rate of re-rupture and sural nerve entrapment with percutaneous surgery (Tenolig®). The high rate of re-rupture can be due to the progressive but immediate weight-bearing allowed without an orthosis, or to inadequate apposition of the tendon ends, or to delay before repair. The high rate of sural nerve entrapment is due to its proximity to the Achilles tendon. We believe that a limited open technique is more reliable and has the advantage of allowing direct visualisation of the repair site and controlling adequate apposition of the tendon ends.

Keywords : Achilles tendon rupture ; percutaneous repair ; Tenolig.

INTRODUCTION

Controversy persists regarding the ideal surgical technique for repair of a ruptured Achilles tendon (27). Many surgeons favour an open operative approach to secure the best possible repair with the lowest rate of re-rupture (5, 8, 9, 18, 20-22, 25, 26, 27, 32, 33).

Others prefer a percutaneous procedure, as first described by Ma and Griffith in 1977 (19), because it allows for a quicker return to professional and sports activities (5, 11, 14, 19).

Delponte *et al* (12), in 1992, published a new technique of percutaneous tendon repair derived from their experience with the barbwire used in hand surgery.

We report our experience with this technique in a series of 124 cases of Achilles tendon rupture.

■ Renaud Maes, MD, Orthopaedic resident.
*Department of Orthopaedic Surgery and Traumatology,
R.H.M.S. Baudour, Baudour, Belgium.*

■ Gerard Copin, MD, Orthopaedic resident.
■ Christophe Averous, MD, Orthopaedic resident.
*Centre de Traumatologie et d'Orthopédie de Strasbourg,
Strasbourg, France.*

Correspondence : Renaud Maes, 321 Chaussée de
Bruxelles, B-6042 Lodelinsart, Belgique.

E-mail : maesrenaud@hotmail.com.

© 2006, Acta Orthopædica Belgica.

Table I. — Cause of rupture

Type of activity	Number of cases
Sports activities (tennis, football)	69
Daily activities	19
Work activities	6
Unknown	30

Table II. — Patients distribution in relation to delay of surgery

Time before operation	Percentage of cases	Number of re-ruptures
< 2 days	56% (n = 69)	0
2-3 days	28% (n = 35)	0
7-12 days	12% (n = 15)	8
> 3 weeks	4% (n = 5)	4

MATERIALS AND METHODS

One hundred and twenty four patients with rupture of the Achilles tendon were surgically treated using the Tenolig® technique in our institution, between August 1993 and October 1998. There were 79 men and 45 women. Their mean age was 41.5 years with a peak between 30 to 39 years. Fifty six percent of the ruptures were due to sports activity (table I).

Half of the patients were operated within two days after the injury (table II).

The operation was most often performed under sciatic block with the patient lying in the prone position. The extremities of the ruptured tendon were identified by finger palpation and marked with a skin marker (fig 1). The needle of the first harpoon wire was entered into the proximal tendon end through a small incision, and pushed distally through the distal tendon to finally perforate the skin covering the heel. A second harpoon wire was introduced in a similar way (fig 2). Both wires were simultaneously put under tension with the ankle held in maximal plantar flexion. A lead block crushed over a washer on the wires blocked the suture (fig 3). The suture was tested using Thompson's test.

An early functional rehabilitation program, carefully supervised by a physical therapist was started. At the second week gentle unloaded active motion of the ankle was initiated (flexion-extension avoiding dorsiflexion beyond neutral). Partial weight-bearing was allowed from the 15th post-operative day with a heel lift of 2-3 centimetres. After three weeks, full weight-bearing was allowed with a decreasing heel lift, following Delponte *et al* (12).

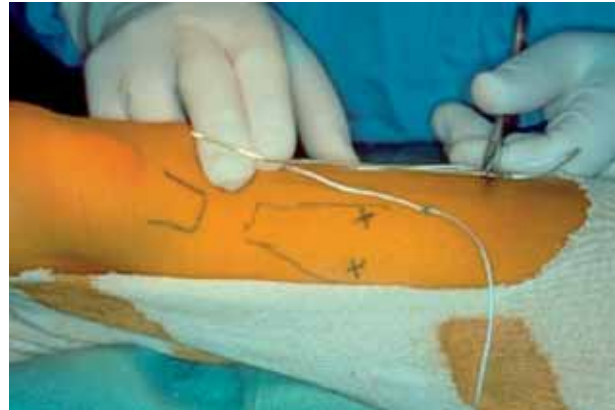


Fig. 1. — The extremities of the ruptured tendon are localised and their position is marked on the skin.

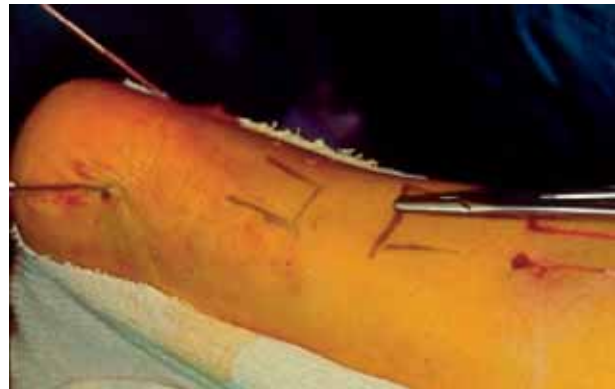

Fig. 2. — The two harpoons are introduced downwards in the proximal tendon end through two small incisions.

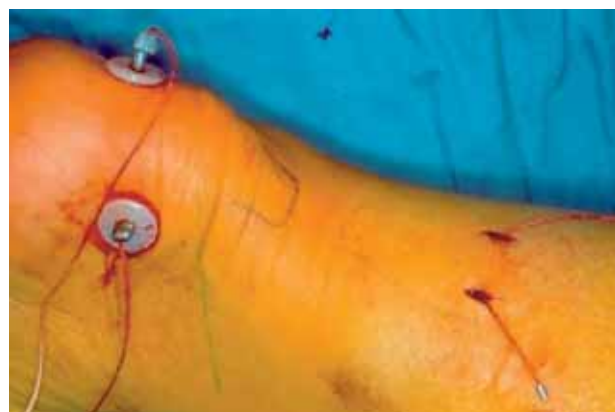

Fig. 3. — With the ankle in maximal plantar flexion both wires are brought under tension simultaneously and blocked by crushed lead balls over a washer.

The Tenolig® wire was removed six weeks after operation.

Patients were instructed to use two crutches during the first six weeks after surgery and one crutch for an additional four weeks.

Jogging was allowed after three months, and more demanding sports activities (tennis, football ...) after six months.

RESULTS

All patients were followed in the outpatient clinic. The mean duration of follow-up was 1.9 years (range : 1 to 5.2). The average hospital stay was 2.5 days.

Suture material failure was a problem : the harpoon unbended and the wire became loose in 5 cases (4%), and the harpoon wire broke in 1 case (1%). Twelve patients (10%) presented re-rupture of the tendon : eight of them had had their repair between the seventh and twelfth day after the injury and four after three weeks (table II). Cutaneous necrosis at the wire entrance occurred in 10 (8.1%) and dysaesthesia of the sural nerve was noted in 8 cases (5.2%).

Full weight-bearing without crutches was regained within 3 months in 95% of cases. Standing on tip-toe was possible between the 3rd and 5th month in most cases.

Most patients returned to their previous occupation about the 3rd post-operative month (84% of cases).

DISCUSSION

Recent reports in the literature have favoured operative treatment for acute ruptures of the Achilles tendon (5, 8, 9, 10, 18, 20-22, 24, 25, 26, 27, 32, 33). The rate of re-rupture in the literature varies from 8% to 29% with conservative treatment (13, 16, 23) and from 0% to 6.5% with open procedures (3, 4, 16, 27). However, skin and nerve complications are more frequent with an open procedure, respectively 4% to 26% and 0% to 18% (3, 4, 16, 35).

The choice of a specific operative procedure as well as the postoperative regimen remain controversial. Most reports discuss either open or percutaneous surgical techniques.

Open procedures have frequently been associated with a high rate of complications related to wound necrosis and infection (7, 15, 17, 23, 29). These complications may be secondary to the extended longitudinal incision, commonly used and the difficult skin closure due to tendon augmentation in the repair technique, even when the anterior tendon sheath is split longitudinally to facilitate closure following de la Caffinière *et al* (11).

Because of these wound healing problems, Ma and Griffith (22) advocated a percutaneous technique for acute ruptures of the Achilles tendon. In 1992, Delponte *et al* (12) popularised a percutaneous approach with the Tenolig® wire. The percutaneous approach was believed to avoid the soft-tissue problems associated with an open repair.

In a review of the literature, Khan *et al* (17), in 2005, found only two randomised studies that compared percutaneous repair and open operative repair : the percutaneous repair was associated with a shorter operation duration and lower risk of infection.

However, some authors have had less favourable results after percutaneous repair (1, 5, 6, 13, 18, 28, 31, 34). Sural nerve entrapment in the suture is a frequent complication, owing to its close relation with the Achilles tendon. We had a total of eight sural nerve entrapments (5.2%). Re-rupture following percutaneous surgery is another major problem. Our series also showed a high rate of re-rupture (10%). Failure of the suture material occurred in 6 cases with unbending of the harpoon or rupture of one of the harpoon wires (5%). The high rate of re-rupture can be due to the progressive, but immediate weight-bearing allowed without an orthosis, or to inadequate apposition of the tendon ends, or to delay before repair. Beyond the first week, it is safe to avoid percutaneous repair, because of the fibrous organisation of the haematoma and retraction of the tendon ; the results are indeed poor (table II). However, delayed suture was successful in three cases in this series.

In 1999, Sutherland *et al* (36) reported a 16% rate of sural nerve injuries. In 1990, Bradley *et al* (5) reported 2 re-ruptures in a group of 12 patients treated with the percutaneous technique and none in a group treated with open repair. Aracil *et al* (1),

in 1992, reported 2 re-ruptures in 6 patients who had undergone repair with the original percutaneous technique used by Ma and Griffith (22). Sutherland *et al* (36), in 1999, found 2 re-ruptures in 31 patients treated with a modified percutaneous technique.

The rate of skin necrosis under the lead wire blocks, in this study, was 8.1%. It was probably due to pressure on the poorly vascularised skin in this area.

For all these reasons we now prefer a limited open technique for acute Achilles tendon rupture.

The limited open technique was first described by Kakiuchi (16) in 1995 and popularised by Assal *et al* (2) in 2002. They use a suture guide to lead the percutaneous sutures in a proximal to distal direction with a limited incision over the rupture site. This limited technique allows direct visualisation of the repair site. It combines the advantages of the open technique (anatomic approximation of the tendon stumps) and of the percutaneous technique (minimal damage to blood supply and gliding structures of the tendon) (30). It allows a control over the apposition of the tendon ends not possible with percutaneous technique.

CONCLUSIONS

This report shows a high rate of re-rupture (10%) and sural nerve injury (5.2%) with percutaneous surgery (Tenolig®). The high rate of re-rupture, comparable to the rate with conservative treatment, can be due to the immediate progressive weight-bearing allowed without an orthosis, or to inadequate apposition of the tendon ends, or to delay before repair. The high rate of sural nerve injury is due to its proximity to the Achilles tendon. We now believe that a limited open technique is more reliable as it allows direct visualisation of the repair site and adequate apposition of the tendon ends.

REFERENCES

1. Aracil J, Pina A, Lozano JA *et al*. Percutaneous suture of Achilles tendon ruptures. *Foot Ankle* 1992 ; 13 : 350-351.
2. Assal M, Jung M, Stern R *et al*. Limited open repair of Achilles tendon ruptures. *J Bone Joint Surg* 2002 ; 84-A : 161-170.
3. Bedaucha JS, Lecestre P, Pelle B *et al*. Ruptures du tendon d'Achille : étude multicentrique de 282 cas revus. *Med Chir Pied* 1989 ; 5, 189-190.
4. Borghi R, Oberlin P, Faure Cl. La rupture du tendon d'Achille - traitement orthopédique ou traitement chirurgical. *Rev Chir Orthop* 1978, 44 : 460-566.
5. Bradley JP, Tibone JE. Percutaneous and open surgical repairs of Achilles tendon rupture. A comparative study. *Am J Sports Med* 1990 ; 18 : 188-195.
6. Buchgraber A, Passler HH. Percutaneous repair of Achilles tendon rupture. Immobilization versus functional postoperative treatment. *Clin Orthop* 1997 ; 341 : 113-122.
7. Carden DG, Noble J, Chalmers J *et al*. Rupture of the calcaneal tendon. The early and late management. *J Bone Joint Surg* 1987 ; 69-B : 416-420.
8. Carter TR, Fowler PJ, Blokker C. Functional postoperative treatment of Achilles tendon repair. *Am J Sports Med* 1992 ; 20 : 459-462.
9. Cretnik A, Kosanovic M, Smrkolj V. Percutaneous versus open repair of the ruptured Achilles tendon. *Am J Sports Med* 2005 ; 33 : 1369-1379.
10. Cetti R, Christensen SE, Ejsted R *et al*. Operative versus nonoperative treatment of Achilles tendon rupture. A prospective randomized study and review of the literature. *Am J Sports Med* 1993 ; 21 : 791-799.
11. De La Caffinière JY, Bene B. Un artifice technique pour éviter les ennuis cutanés dans la réparation chirurgicale des ruptures de tendon d'Achille. *Rev Chir Orthop* 1984 ; 70 : 343-345.
12. Delponte P, Potier L, De Poulpique P, Buisson P. Traitement des ruptures sous-cutanées du tendon d'Achille par ténonraphie percutanée. *Rev Chir Orthop* 1992 ; 78 : 404-407.
13. Fizzgibbons RE, Hefferon J, Hill J. Percutaneous Achilles tendon repair. *Am J Sports Med* 1993 ; 21 : 724-727.
14. Haji A, Sahai A, Symes A, Vyas JK. Percutaneous versus open tendo Achillis repair. *Foot Ankle Int* 2004 ; 25 : 215-218.
15. Inglis AE, Scott WN, Sculco TP, Patterson AH. Ruptures of the tendo Achillis : an objective assessment of surgical and nonsurgical treatment. *J Bone Joint Surg* 1976 ; 58-A : 990-993.
16. Kakiuchi M. A combined open and percutaneous technique for repair of tendo Achillis. *J Bone Joint Surg* 1995 ; 77-B : 60-63.
17. Khan RJ, Fick D, Brammar TJ *et al*. Interventions for treating acute Achilles tendon ruptures. *Cochrane Database Syst Rev* 2004 ; 3 : CD003674.
18. Klein W, Lang DM, Saleh M. The use of the Ma-Griffith technique for percutaneous repair of fresh ruptured tendo Achillis. *Chir Organi Mov* 1991 ; 76 : 223-228.
19. Kouvalchouk JF, Rodineau J, Watin L, Augouard L. Les ruptures du tendon d'Achille. Comparaison des résultats du traitement opératoire et non opératoire. *Rev Chir Orthop* 1984 ; 70 : 473-478.

20. **Lea RB, Smith L.** Non surgical treatment of tendo achillis rupture. *J Bone Joint Surg* 1972 ; 54-A : 1398-1407.
21. **Leppilahti J, Orava S.** Total Achilles tendon rupture. A review. *Sports Med* 1998 ; 25 : 79-100.
22. **Ma GW, Griffith TG.** Percutaneous repair of acute closed ruptured Achilles tendon : a new technique. *Clin Orthop* 1977 ; 128 : 247-255.
23. **Maffuli N.** Rupture of the Achilles tendon. *J Bone Joint Surg* 1999 ; 81-A : 1019-1036.
24. **Mandelbaum BR, Myerson MS, Forster R.** Achilles tendon ruptures. A new method of repair, early range of motion, and functional rehabilitation. *Am J Sports Med* 1995 ; 23 : 392-395.
25. **Mortensen HM, Skov O, Jensen PE.** Early motion of the ankle after operative treatment of a rupture of the Achilles tendon. A prospective randomized clinical and radiographic study. *J Bone Joint Surg* 1999 ; 81-A : 983-990.
26. **Nistor L.** Surgical and nonsurgical treatment of Achilles tendon rupture : a prospective randomized study. *J Bone Joint Surg* 1981 ; 63-A : 394-399.
27. **Popovic N., Lemaire R.** Diagnosis and treatment of acute ruptures of the Achilles tendon. Current concepts review. *Acta Orthop Belg* 1999 ; 65-4 : 458-471.
28. **Rebecato A, Santini S, Salmaso G, Nogarini L.** Repair of the Achilles tendon ruptures : a functional comparison of three surgical techniques. *Foot Ankle Surg* 2001 ; 40 : 188-194.
29. **Riedl S, Sandberger L, Nitschmann K, Meeder PJ.** Suture of fresh Achilles tendon rupture. Comparison of open with percutaneous suture technique. *Chirurg* 2002 ; 73 : 607-614.
30. **Rippstein PF, Jung M, Assal M.** Surgical repair of acute Achilles tendon rupture using a "mini-open" technique. *Foot Ankle Clin N Am* 2002 ; 7 : 611-619.
31. **Rowley DI, Scotland TR.** Rupture of the Achilles tendon treated by a simple operative procedure. *Injury* 1982 ; 14 : 252-254.
32. **Soldatis JJ, Goodfellow DB, Wilber JH.** End-to-end operative repair of Achilles tendon rupture. *Am J Sports Med* 1997 ; 25 : 90-95.
33. **Solveborn SA, Moberg A.** Immediate free ankle motion after surgical repair of acute Achilles tendon ruptures. *Am J Sports Med* 1994 ; 22 : 607-610.
34. **Steele GJ, Harter RA, Ting AJ.** Comparison of functional ability following percutaneous and open surgical repairs of acutely ruptured Achilles tendons. *J Sport Rehab* 1993 ; 2 : 115-127.
35. **Stein SR, Luekens CA Jr.** Closed treatment of Achilles tendon ruptures. *Orthop Clin North Am* 1976 ; 7 : 241-246.
36. **Sutterland A, Maffuli N.** A modified technique of percutaneous repair of ruptured Achilles tendon. *Oper Orthop Traumat* 1999 ; 7 : 288-295.