

Acquired flatfoot deformity secondary to dysfunction of the tibialis posterior tendon

Nebojsa POPOVIC, Roger LEMAIRE

The authors present an overview of currently available data relating to acquired dysfunction of the tibialis posterior tendon (TPT). This condition has only gained wide recognition over the past twenty years, although isolated cases had been reported much earlier.

They describe the anatomy of the tendon and its complex distal insertions, together with particular features of the vascularisation and histology of the retromalleolar portion of the tendon. They analyse the biomechanical role of the TPT under normal conditions and the mechanism of the foot deformities that occur secondary to acquired dysfunction of the tendon.

A number of theories have been suggested to explain the occurrence of acquired TPT dysfunction, such as degenerative tendinosis, chronic inflammation, retromalleolar impingement, hypovascularity. Most cases are not linked to any specific aetiological factor and are therefore termed “idiopathic”.

Several classification schemes have been proposed, based on MRI findings or clinical presentation.

In the latter classification, stage I is characterised by medial pain without any clinical or radiological deformities; in stage II, with elongation of the TPT, pain is present medially and/or laterally, with a pes planovalgus deformity that remains flexible; the deformity becomes fixed and irreducible in stage III and stage IV is the end stage, with osteoarthritis of the ankle.

The diagnosis is essentially clinical, with the “too many toes” sign, a positive single-heel rise test together with medial pain and swelling and weakness of ankle inversion. Plain radiographs are useful to rule out any concomitant abnormalities; various methods have been proposed to quantify the flatfoot deformities on weight-bearing radiographs. Ultrasound and MRI may be useful to assess tendon pathology.

Conservative treatment (rest, orthoses, shoe modifications, NSAIDs) may alleviate symptoms in patients with minimal deformity but is not effective in cases with advanced pathological changes. Surgical treatment is therefore often necessary but controversy persists with regard to which technique or combination of techniques is preferable. Stage I is an indication for synovectomy, possibly combined with repair of the deltoid ligament and augmentation of the TPT with soft tissue transfer from the flexor digitorum longus, the flexor hallucis longus or the anterior tibialis tendon. Treatment of stage II is controversial; the current trend is to combine tendon transfer with a joint-sparing bony operation such as a lateral column lengthening procedure or a medial translational osteotomy of the calcaneus. Subtalar, double or triple arthrodesis are the procedures of choice for stage III TPT dysfunction whereas tibio-calcaneal arthrodesis or pantalar fusion is the only remaining option in stage IV.

INTRODUCTION

Dysfunction of the tibialis posterior tendon (TPT) represents a challenging problem for the orthopaedic surgeon, often resulting in significant disability for the patient and progressive loss of

From the University Hospital (C.H.U. du Sart-Tilman), Liège, Belgium.

Nebojsa Popovic, Consultant Orthopaedic Surgeon.

Roger Lemaire, Honorary Chairman, Consultant Orthopaedic Surgeon.

Correspondence and reprints : Nebojsa Popovic, Orthopaedic Department, University Hospital (CHU du Sart-Tilman), 4000 Liège, Belgium.

function. Typified by progressive, unilateral acquired flatfoot, this problem is often overlooked or misdiagnosed. Kulowski, in 1936, reported for the first time on three patients with effusion into the tendon sheath of the tibialis posterior tendon (31). In 1950, Lapidus and Seidenstein reported two cases of tenosynovitis of the tibialis posterior tendon (32): in both cases, incision and excision of the tendon sheath (in one case total excision and in the other partial excision) reportedly cured the condition. Rupture of the tibialis posterior tendon was first identified during surgery in a patient whose case was reported by Key in 1953 (26). In 1969, Kettelkamp and Alexander (27) published the results of surgical exploration in four patients with typical combination of painful flatfoot deformity with tenderness and swelling along the sheath of the tibialis posterior tendon. At surgical exploration, they found that in two patients the tendon had ruptured in the mid-portion and in one patient it had avulsed from its insertion into the navicular. In the fourth patient, the tendon was intact. In 1974, Goldner *et al* (14) used either the flexor digitorum longus or the flexor hallucis longus to replace the tibialis posterior tendon with some degree of plication of the spring ligament. It was not until 1982 that reports of spontaneous rupture of the tibialis posterior tendon again appeared in the literature. Mann and Specht (34) reviewed the cases of eight patients who were treated surgically for rupture of the tendon. In 1982, Jahss (22) described the cases of ten patients with suspected rupture. In 1983, Johnson (23) discussed the signs and symptoms of rupture of the tibialis posterior tendon. Until 1985, only fifty cases have been reported in the orthopedic literature, in which the deformity was treated operatively. Many different methods of treatment have been utilised (4, 7, 17, 19, 24, 35, 38, 43, 45).

The various lesions of the tibialis posterior tendon — avulsion, attenuation or frank rupture — that are found at surgery make it evident that the clinical symptoms of this disorder may result from several different types of pathology and various treatment options could thus be considered. There are different stages of development, with some clinically distinct aetiologic mechanisms that should be recognised prior to attempting any type of treat-

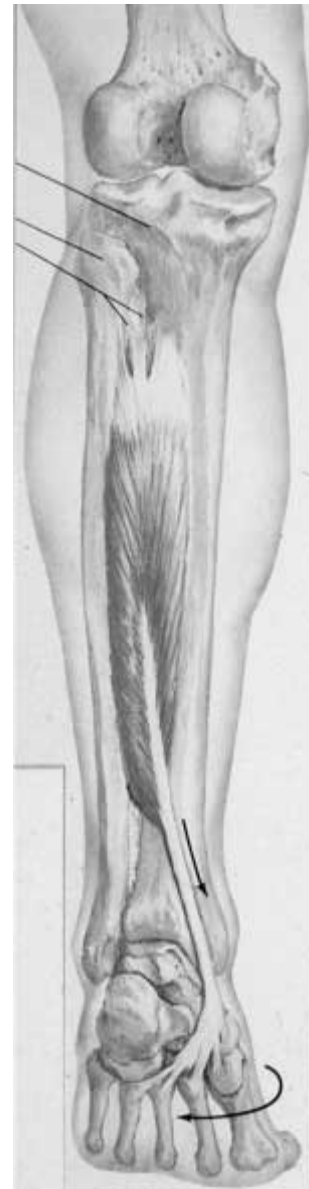

Fig. 1. — Anatomy of the tibialis posterior tendon

ment. The purpose of this paper is to review special anatomic considerations and special concepts of the tendon and ligament relevant to TPT dysfunction, aetiology, diagnosis and treatment of this condition.

ANATOMY

Arising from the proximal one-third of the interosseous membrane and adjacent to the posterior

surface of the tibia and fibula, the large muscle units of the tibialis posterior (TP) converge onto its tendon in the distal third of the leg. The tendon courses just posterior to the medial malleolus and terminates in multiple insertions (fig 1). The distal insertions of the TP tendon, although variable, are important to consider from a functional point of view. The multiple distal insertions of the TP tendon have been well described previously. They include attachments at the navicular (the main insertion), first cuneiform joint, sustentaculum tali, 2nd and 3rd cuneiforms, cuboid and bases of 2nd, 3rd and 4th metatarsals. There are also soft tissue attachments into the naviculocuneiform capsule, inferior band of the extensor retinaculum, long and short plantar ligaments, spring ligament, and dorsal ligamentous complexes. This ligamentous network provides the possibility for an equally complex group of functions involving the tibialis posterior tendon. Mueller (40) notes that the tendon does not seem to glide at the secondary insertions and thus probably acts as a bony stabiliser.

Some variations in this tendon have been reported, such as anomalous or bifid tendons (13) and the presence of an intratendinous ossicle or fibrocartilaginous plate (7). More commonly, an accessory navicular bone can provide an abnormal insertion point for the tibialis posterior tendon, altering its action (13). There are two types of accessory bones found in the region of the tuberosity of the navicular (2). One is a sesamoid bone that is located in the tibialis posterior tendon before its division and the other is an independent ossicle, the *os tibiale externum*. Since the recent study of Bareither *et al* (2) establishes that there is a sesamoid bone as well as the *os tibiale externum*, it would be of clinical interest to study foot shape, arch structure and mechanics of the tibialis posterior related to each.

VASCULARISATION

Frey *et al* studied the vascularity of the posterior tibial tendon in 28 anatomic specimens (11). The injection technique allowed them to visualise a hypovascular zone posterior and distal to the medial malleolus in all 28 specimens. The vascularity

of the tibialis posterior tendon was noted to be abundant at the osseous insertion and the musculotendinous junction.

HISTOLOGY

The proximal region of the human tibialis posterior tendon appears histologically distinct from the more distal region of the same tendon. In the proximal region, collagen bundles are organised in a strictly linear manner, with elongated cells between the fiber bundles. In contrast, the collagen arrangement in the more distal region, the region that passes under the medial malleolus, shows rounded rather than elongate cellular morphology, an increased amount of glucosaminoglycan (GAG) and the presence of a significant amount of large as well as small proteoglycan. The study of Vogel *et al* (48) has demonstrated that alteration in this region of the tendon was present in all specimens examined and did not show any consistent differences with increasing age after puberty. It can be concluded that development of a fibrocartilaginous morphology and proteoglycan composition is a normal adaptive response of tissue at this location.

However, poor vascularity and hydrostatic compression, when combined with tensional deformations, may encourage fibrocartilage development in the tibialis posterior tendon in this region.

BIOMECHANICAL ASPECT OF TP FUNCTION

The tibialis posterior tendon supinates the foot in an open kinetic chain and acts as a stabiliser and adductor of the midtarsal joint. However, its primary function appears to be as an adductor at the midtarsal joint. Thus, it directly opposes the action of the peroneus brevis on the foot. The tibialis posterior muscle functions during the stance phase of gait, beginning shortly after heel contact. It aids in shock absorption at the subtalar joint by minimising and controlling the amount of rear foot eversion by eccentric contraction. At the midstance phase of gait, the lesser tarsus is being stabilised and readied for propulsion. During this phase of gait, there is not much gliding of the tibialis posterior tendon.

Thus, it acts to stabilise the midtarsus. During the propulsive phase of gait, the TP muscle functions to accelerate subtalar joint supination and assists in heel lift. Although it becomes inactive shortly after heel lift, the residual effect of TP function on the swing phase of gait is that of acceleration (40).

Another controversial area concerns the function of the tibialis posterior muscle in support of the medial longitudinal arch. Kapandji's view of the effect of the TP tendon on arch support provides a reasonable explanation (25). As the tibialis posterior adducts and plantarflexes the navicular on the talar head, the medial longitudinal arch is buttressed. As the navicular is medially displaced by the tibialis posterior action, so is the cuboid medially pulled by tension on the lateral band of the bifurcate (Y) ligament. This, in turn, adducts the anterior aspect of the calcaneus, by tension on the calcaneocuboidal ligaments. As a consequence, the sinus tarsi is opened, the lateral arch is diminished, and peroneus brevis action is directly opposed. Additionally, the Y ligament is seen to have a tethering effect on the talonavicular and calcaneocuboidal joints, forming the "keystone" of the midtarsal joint, as described by Kapandji (25).

Experimental models have suggested that the contour of the medial longitudinal arch is maintained passively under most cases of static loading with muscle response occurring when excessive non-physiologic loads are reached. Clinical experience with chronic ruptures of the posterior tibial tendon suggests that it is an important dynamic stabiliser of the arch and loss of function of the posterior tibial muscle has clearly deleterious effects on normal gait.

The pathogenesis of PTT dysfunction leading to adult acquired flatfoot deformity is insufficiently understood. Presumably the deformity develops as two support mechanisms fail. First the posterior tibial tendon is assumed to have a direct arch supporting function ; the loss of this function leads to a flatfoot deformity. Second, the posterior tibial tendon normally inverts the hindfoot during the stance phase of gait (locking the hindfoot in a rigid position for push-off) ; the lack of inversion resulting from TPT dysfunction leaves the foot in a relatively unstable valgus position and allows the gast-

rosoleus complex to act through the ankle joint and through the talonavicular joint. Eventually, this abnormal force leads to a flatfoot abduction deformity.

Unfortunately, the existing biomechanical data from the literature about the dynamic function of the various tendons of the foot are insufficient to allow for conclusions on the importance of these two potential mechanisms in the pathogenesis of the flatfoot.

AETIOLOGY

Several factors are of consideration in the aetiology of tibialis posterior dysfunction. A number of theories have been suggested. Mc Master (37) suggested that degenerative changes of the tendon predispose it to rupture. Banks and Mc Glamry (1) stated that the most common cause of PT rupture arises from inflammation that results in an already-stressed tendon that is trying to stabilise a hypermobile foot. Jahss (22) hypothesised that there is an impingement mechanism at the level of the fibroosseous groove, posterior to the medial malleolus, where the tendon has an acute angulation. Frey *et al* (11) suggested that the hypovascular region of the TP tendon noted behind the medial malleolus may be a common site of rupture. However, a large percentage of abnormalities of the TPT occurs distal to this area. Hall (16) feels that obesity, pes planus and hypovascularity of the TP tendon are predisposing factors towards TP tendon dysfunction. Inman (21) has stated that TP tendon rupture was a possible consequence of rheumatoid arthritis. Tachdjian (46) discussed the role of the accessory navicular bone in altered tibialis posterior function. Mosier *et al* (39) clearly showed that the underlying pathological mechanism in chronic dysfunction of the posterior tibial tendon is degenerative tendinosis with no evidence of inflammation.

Mueller (40) categorises TP dysfunction into four aetiological categories, including direct injury, pathological rupture, idiopathic rupture and functional rupture (table I). Patients in the latter category may have varying degrees of rupture or dysfunction of the tendon of tibialis posterior, and may well be on their way to complete rupture.

Table I. — Aetiologic classification of tibialis posterior dysfunction

Type I	Direct : injury to the tendon resulting in dysfunction of the tibialis posterior tendon.
Type II	Pathologic rupture : e.g., tendon degeneration associated with rheumatoid arthritis.
Type III	Idiopathic rupture : aetiology unknown.
Type IV	Functional rupture : the tibialis posterior tendon is intact but not functioning well.

CLASSIFICATION OF TP DYSFUNCTION

The aetiologic classification divides TP dysfunction into four aetiologic categories : direct injury, pathologic rupture, idiopathic and functional ruptures. Several authors have attempted to categorise TP dysfunction into stages based on the duration of the lesion, presenting symptoms and condition of the tendon when examined surgically or with MRI.

Conti *et al* (6) have proposed a classification scheme of posterior tibial tendon tears based on magnetic resonance imaging (MRI) which takes into account gross structural features and abnormal signal within the substance of the tendon.

Type I : MRI shows one or two fine longitudinal splits, usually on the undersurface of the tendon without evidence of intrasubstance tendon degeneration.

Type II : The tibialis posterior tendon is narrowed on the MRI with wider longitudinal splits and evidence of intramural degeneration.

Type III : This type is notable for more diffuse swelling of the tendon with uniform degeneration becoming prominent. A few strands of tendon may remain intact, or the tendon may be completely replaced by scar tissue.

Johnson and Ström (24) described four stages in the clinical presentation of TP dysfunction.

Stage I is characterised by medial pain and mild weakness. The hind foot inverters are normal and the clinical and radiographic deformities on the ankle are absent.

Stage II is characterised by elongation and deformation of the posterior tibial tendon. The pain is present medially or laterally or both. The clinical

tests (“too many toes” and single limb heel rise) are positive but the pes planovalgus deformity remains flexible with the hindfoot held in equinus.

Stage III is characterised by some findings as in Stage II ; in addition the pes planovalgus deformity is fixed and irreducible.

Stage IV in the development of TP dysfunction is the end stage, characterised by fixed irreducible pes planovalgus deformity and osteoarthritis of the ankle which severely limits the ability to walk.

DIAGNOSIS

Demographic analysis has shown dysfunction of posterior tibial tendon to be three times more common in women than in men and patients frequently are older than 40 years of age. There is an increased incidence of rupture of the PTT in obese middle-aged women and in patients with hypertension and diabetes. Local injection or oral intake of steroids have also been associated with tendon rupture (22).

The diagnosis of posterior tibial tendon insufficiency is primarily a clinical one. Clinically, the patients usually present with a unilateral progressive hindfoot valgus deformity associated with mild to moderate pain medially around the ankle. All the patients report swelling over the medial aspect of the ankle. Pain is exacerbated by activity, and the ability to walk distances decreases. Later in the disease process, some patients complain of pain on the lateral aspect of the foot because the deformity causes impingement of the lateral structures of the foot (calcaneus on the lateral malleolus), due to an excessive valgus position of the hindfoot.

CLINICAL EVALUATION

Physical examination

When observing the patient in a standing position from behind, asymmetrical pes planovalgus will be indicated by the so-called “too many toes” sign. In this test, the patient is asked to assume a comfortable knee-leg alignment toward a wall. From a direct posterior midline vantage, the examiner counts the number of toes on each foot that are

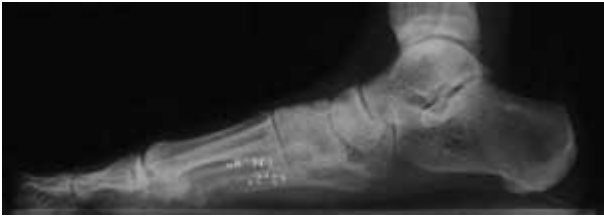

Fig. 2a. — Standing lateral radiograph showing collapse of the longitudinal arch.

visible laterally. As the heel goes into increased resting eversion and the forefoot goes into abduction, too many toes are seen on the affected side.

Another helpful diagnostic test is the single-heel-rise test. The patient is asked to lift the uninjured foot off the ground, then to rise up on the toes of the affected side (the patient may use one finger of each hand for balance). The examiner observes for heel elevation accompanied by inversion. With elongation of the TPT, however, the initial heel inversion is weak and the patient either rises up incompletely without locking the heel or does not get up on the ball of the foot at all.

Although some authors dismiss its utility, manual testing of muscle units is helpful for both diagnosis and determination of treatment options. True inversion weakness is tested manually by applying resistance with the foot in a plantarflexed and everted position to recruit accessory invertors such as the tibialis anterior muscle.

Imaging modalities

Plain radiographs should include anteroposterior view of both ankles, anteroposterior view of both feet, lateral foot and ankle radiographs of each side while bearing weight. These films are important first to evaluate concomitant abnormalities that may cause flat foot deformity, such as Charcot arthropathy, previous injury, degenerative or inflammatory arthritis or tarsal coalition. Second, these radiographs are particularly helpful to quantify the extent of the flatfoot deformity.

There are many different approaches to the measurement of flatfoot deformity on plain radiographs. Chadha *et al* (5) described a method utilizing linear measurements on the anteroposterior

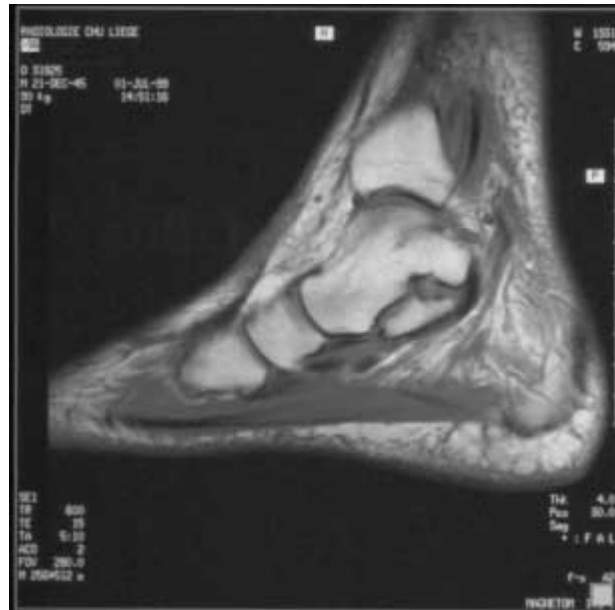


Fig. 2b. — MRI showing the ruptured tibialis posterior tendon in the same patient.

radiographs of the foot. The degree of abduction of the forefoot is quantified by measuring the degree to which the talar head is not covered by the navicular.

Anteroposterior foot radiographs typically demonstrate lateral peritalar subluxation of the navicular and associated abduction of the midfoot in comparison to the contralateral side. On the weight-bearing lateral radiographs, the inclination of the talus is plantarward in comparison to normal, with the collapse typically through the talonavicular joint. Comparison of the inferior portion of the medial cuneiform to the inferior portion of the fifth metatarsal can be helpful to allow objective measurement of the degree of collapse (fig 2).

The bilateral anteroposterior radiograph of the ankle is used to measure the total height of the ankle, from the superior margin of the talar body to the base of the radiograph. Asymmetrical flatfoot can be documented on the basis of a shorter height on one side.

If the diagnosis is in question, use of ultrasonography, injection tenography, computed tomography and magnetic resonance imaging has been advocated by some authors. Ultrasound can be used

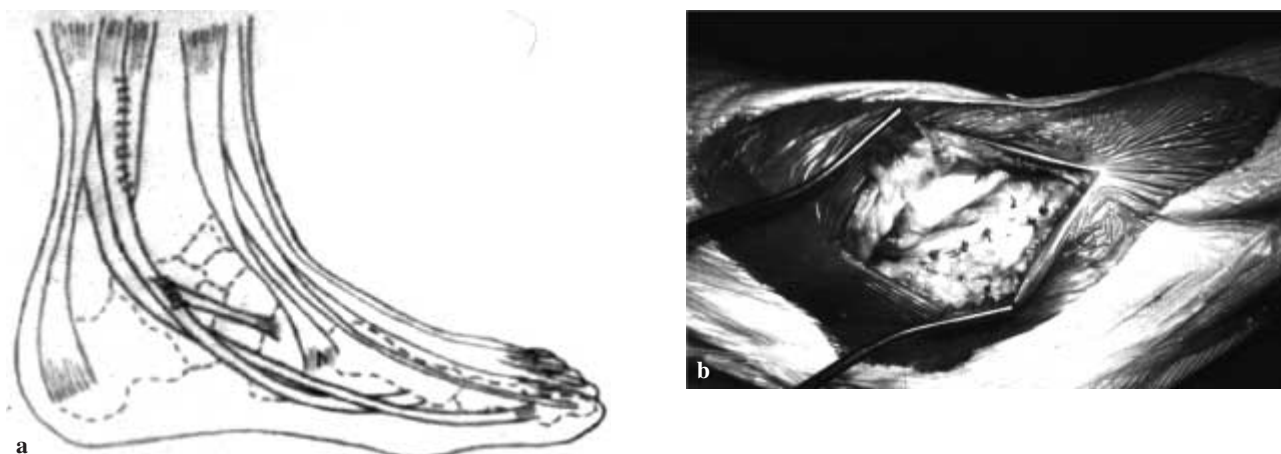


Fig. 3. — Jahss technique, consisting of a side-to-side anastomosis of both proximal and distal portions of the ruptured tibialis posterior tendon to the adjacent flexor digitorum longus tendon. Drawing (a) and operative view (b).

as an accurate diagnostic modality to assess tendon pathology : depending upon the stage of the lesion, it may reveal a swollen tendon with a large amount of fluid surrounding it, irregularity in its contour, longitudinal splits within the tendon, heterogenous echogenicity and, in cases with tendon rupture, an empty groove behind the medial malleolus. Magnetic resonance imaging may help to confirm the presence of tenosynovitis or intrasubstance tears of the tendon ; It has excellent sensitivity and specificity. This also applies to sonography, which appears highly cost-effective. It has been suggested that sonography should be used as a routine screening method, which might help in diagnosing stage-I tendon dysfunction.

CONSERVATIVE TREATMENT

The initial treatment of patients who present in any stage of posterior tibial tendon insufficiency is non-operative, unless there is already a significant fixed deformity. This includes rest provided by crutches or cast immobilisation, orthoses, shoe modifications, non-steroidal anti-inflammatory medications and local corticosteroid injection. The latter is however controversial, and injection of corticosteroid into the tendon itself should definitely be avoided. Iontophoresis with dexamethasone also has an effective anti-inflammatory effect and does not seem to increase the risk for tendon rupture.

Controversy exists about benefits of nonoperative treatment. For some authors, operative treatment should be considered only after a three-to-six months trial of non-operative care has failed. Jahss notes that conservative treatment generally gives no relief or may even allow the condition to worsen (22). Some success has been achieved with conservative treatment in patients who have acute tenosynovitis of TP with or without deformity. Although there are no published studies documenting the efficacy of orthotic devices in the treatment of various stages of this condition, there is certainly a population of patients who report a decreased level of symptoms associated with the use of such a device (3).

It is generally agreed that conservative treatment of TP dysfunction has a limited success rate. For that reason, most authors agree that these non-invasive means should be reserved only for patients who present with minimal initial deformity and symptoms and for patients with major deformities who are not amenable to surgery.

SURGICAL TREATMENT

Most authors believe that surgical treatment is preferable when dealing with TP dysfunction. It is generally agreed that surgical treatment is more successful the earlier it is instated. The procedure selected should address the specific problem pre-

sented. Currently, there is much controversy with regard to which technique or combination of techniques is preferable.

Available procedures

Overall, surgical procedures can be grouped into three categories. The first involves soft tissue procedures alone, the second involves joint fusion or osteotomy alone and the third involves soft tissue procedures combined with either osteotomy or arthrodesis.

1. *Soft tissue procedures* include primary repair of the tendon, reattachment of the tendon, debridement, tenosynovectomy and soft tissue transfer. The most frequently used repair was described by Jahss (22) in 1982 in which flexor digitorum longus anastomosis to an injured TP was used for soft tissue reconstruction. Other authors utilised the flexor hallucis longus or part of the tibialis anterior tendon (12). The deltoid ligament should be carefully explored, and it may have to be repaired, reattached, reefed or augmented with a plantaris tendon graft during the tendon repair or augmentation procedure. The tendon transfer operation has the potential advantage of preserving motion of the hindfoot but it has limitations in consistently correcting deformity. Some authors believe that the transferred tendon will function effectively in place of the posterior tibialis tendon ; however, in their study, Kitaoka *et al* noted disappointing clinical results for flexor digitorum longus transfer and assumed that the TPT was nonfunctional (29). Overall, it appears that soft tissue transfer does not correct the underlying deformity and has been acceptable only in terms of pain relief (fig 3).

Synovectomy is routinely performed during repair or augmentation of the tibialis posterior tendon ; synovectomy alone may be indicated for isolated tenosynovitis with persistent symptoms refractory to conservative management.

2. The second category involves operations that attempt to compensate for underlying deformities with *arthrodeses or osteotomies*.

Single (subtalar, talonavicular or calcaneocuboid), double (subtalar and talonavicular or talona-

vicular and calcaneocuboid) and triple (subtalar, talonavicular and calcaneocuboid) arthrodeses have been proposed in the literature for the treatment of the acquired flatfoot from posterior tibialis tendon dysfunction (39, 43). There are no definite guidelines in the literature as to when to perform an arthrodesis. In general, factors to consider in selecting a given arthrodesis procedure include the following : the operation should completely correct the deformity, the calcaneus should always be placed under the talus in 3° to 5° of valgus and the arthrodesis should preserve as much mobility in the foot as possible.

2.1. *Limited arthrodeses* of either the subtalar or talonavicular joint have been described in the literature. These arthrodeses result in less stiffness in the foot than any of the others and theoretically protect the ankle and the midfoot joint from long-term arthritic changes.

The advantages of *subtalar fusion* are well known. The procedure is easy to perform and has a fusion rate of more than 95% ; it also allows a more flexible foot and protects the more proximal ankle joint. Kitaoka *et al* (29) showed that subtalar fusion improved foot alignment substantially and can lead to long-term maintenance of hindfoot alignment. Isolated subtalar fusion is indicated only in cases with fixed deformity of the subtalar joint with preservation of a mobile and painless mid-tarsal joint. It causes minimal alteration of gait on flat surfaces.

Correction of flatfoot deformity with *fusion of the talonavicular joint* alone was preferred by some authors. This arthrodesis can successfully restore the height of the medial longitudinal arch and appears to provide lasting correction. There are also disadvantages with this procedure : the non-union rate is from 8% to 24% and it may result in a nearly complete loss of motion in the subtalar and transverse tarsal joints. Besides, the long-term outcome following isolated talonavicular fusion for acquired flat-foot deformity in the adult has not been established by specific clinical studies. Good short-term results have been reported (17), but degenerative changes were noted in the adjacent joints in some patients and it has therefore been suggested to also fuse the calcaneocuboid joint (36).

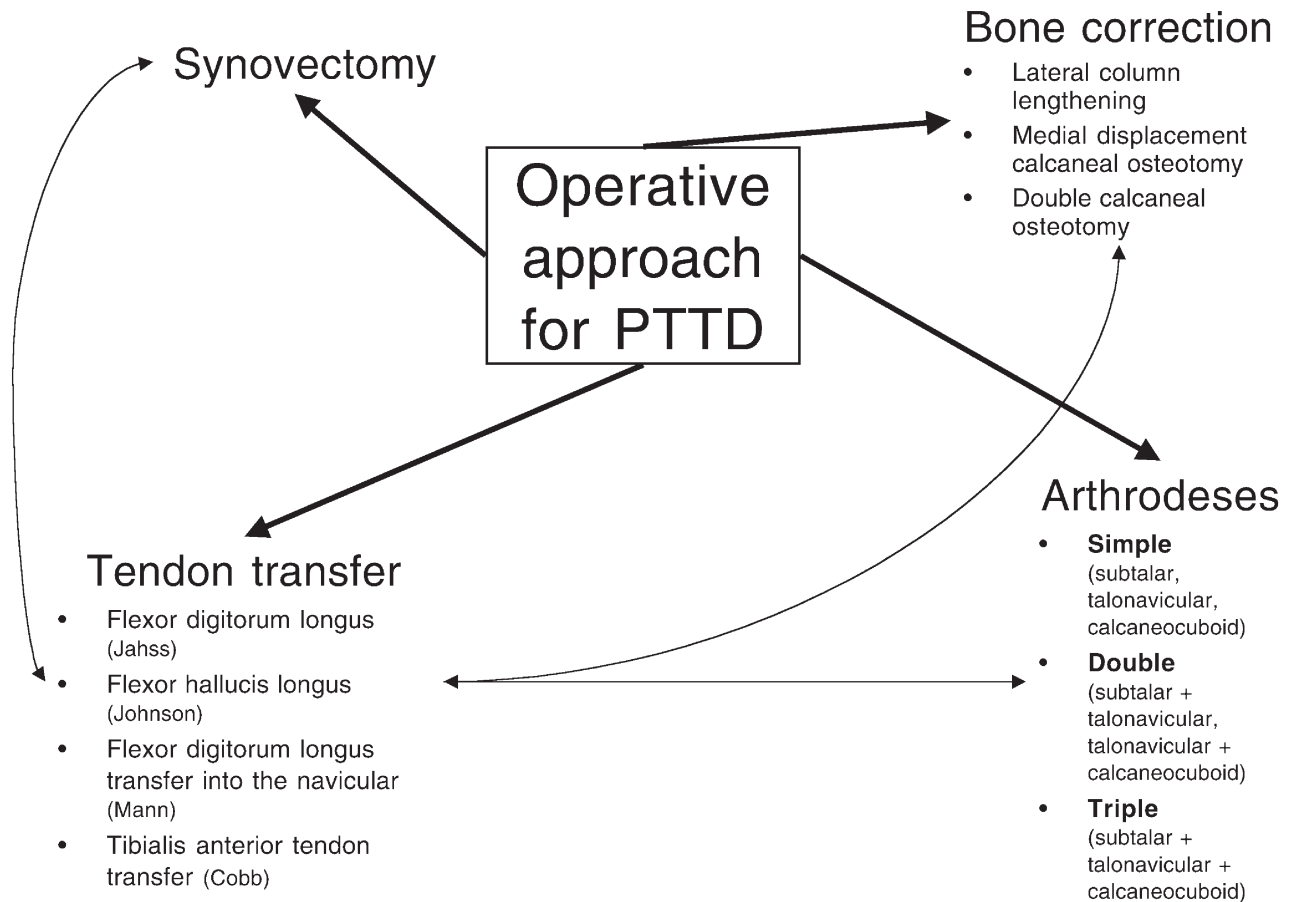


Fig. 4. — An overview of the operative procedures which may be used in the treatment of posterior tibial tendon dysfunction. Possible combinations of individual procedures are indicated by double-headed arrows.

2.2. *Triple arthrodesis* remains as a gold standard for the treatment of severe deformity of the hindfoot in patients with posterior tibialis tendon dysfunction. Banks and Mc Glamry (1) feel that triple arthrodesis should be the fusion procedure of choice to realign properly the forefoot as well as the hindfoot. Long-term studies of triple arthrodesis have however demonstrated progressive degenerative changes in the ankle as time passes.

Severe deformity of both the hindfoot and forefoot can be corrected with this arthrodesis while leaving the foot in a plantigrade position. The arch is restored and a well-performed triple arthrodesis also leaves the foot with a more normal appearance.

2.3. *Lateral column lengthening procedures* have been utilised in the treatment of TP dysfunction.

The rationale is to restore the medial longitudinal arch by correcting the relative shortening of the lateral column which occurs as the foot assumes a pes planovalgus deformity. These procedures are performed in an attempt to correct both frontal and transverse plane foot deformities and when soft tissue procedures would provide less-than-desirable results. Evans devised an *opening wedge osteotomy of the calcaneus*, 15 mm proximal to the calcaneocuboid joint, followed by insertion of a bone graft from the iliac crest or from a femoral head allograft (8). Alternatively, lengthening of the lateral column can be achieved with a *calcaneocuboid distraction arthrodesis*, again using a wedge of autologous or allogeneic bone (18). Thomas *et al* found in a comparative study that similar patient satisfaction was achieved with both techniques,

with high complication rates in both cases, particularly in terms of nonunion and delayed union for the calcaneocuboid distraction arthrodesis (47).

2.4. Alternatively, some correction of the arch can be achieved without fusion, with a *medial translational osteotomy of the calcaneus* (19, 20, 30, 41, 42). This displaces medially the ground contact point of the heel as well as the insertion of the Achilles tendon, thus decreasing its effect as a possible evolver (19). It may however be insufficient to achieve full correction of the arch and it has therefore been suggested to combine medial slide osteotomy of the calcaneus with a lateral column lengthening procedure (42). Frankel *et al* (10) have used double calcaneal osteotomy in the treatment of TP dysfunction. They believe that this procedure reduces transverse plane deformity and realigns the talonavicular joint as well as assists in increasing calcaneal inclination by stabilisation of the lateral column. It seems that this procedure addresses a specific patient group : one of relatively young age and active life style with recent onset of PT dysfunction, absence of degenerative joint disease and of fixed deformities. Short term follow-up studies have shown that the early results are promising in selected patients.

3. Recently, there has been growing interest in operations that attempt to compensate for the underlying deformities and deforming forces with *osteotomies or limited arthrodeses combined with dynamic tendon transfer* to replace or augment the insufficient posterior tibial tendon.

Myerson *et al* (41) and Pomeroy *et al* (42) reported the early successful results of joint-sparing operations, such as a medialising osteotomy of the calcaneal tuberosity in addition to tendon transfer, and a procedure that combines a medialising calcaneal osteotomy, a lateral column lengthening osteotomy through the anterior calcaneus, a flexor digitorum longus tendon transfer to the medial cuneiform, and heel-cord lengthening.

The joint-sparing operations and limited fusions combined with soft tissue reconstruction allow for optimism, as it may be possible to treat some patients with procedures that do not result into a major loss of foot motion and adaptability.

However, the long-term outcome of patients treated with these techniques remains to be established.

Indications

- From the literature review, it appears that **Stage I** posterior tibial tendon insufficiency is generally treated with debridement and *tenosynovectomy*. When important changes in the substance of the tendon are present, augmentation of the posterior tibial tendon with *soft tissue transfer* may be considered.
- Currently, there is much controversy with regard to which technique or combination of techniques is preferable in treatment of **Stage II** TPT dysfunction. Short-term follow-up studies have shown that the early results of *tendon transfer in conjunction with a joint-sparing bony operation* are promising.
- *Subtalar, double, or triple arthrodesis* are the procedures of choice for **Stage III** TPT dysfunction, frequently combined with heel-cord lengthening.
- The patients with **Stage IV** TPT dysfunction are the most difficult to treat. Operative treatment should be considered after non-operative treatment has failed. Most commonly, tibiocalcaneal arthrodesis or *pantalar arthrodesis* is used.

REFERENCES

1. Banks AS, McGlamry ED. Tibialis posterior tendon rupture. *J APMA* 1987 ; 77 : 170-176
2. Bareither DJ, Muehleman CM, Feldman NJ. Os tibiale externum or sesamoid in the tendon of tibialis posterior. *J Foot Ankle* 1995 ; 34 : 429-434
3. Beals TC, Pomeroy GC, Manoli A. Posterior tibial tendon insufficiency : Diagnosis and treatment. *J Am Acad Orthop Surg* 1999 ; 7 : 112-118
4. Bennett GL, Graham CE, Mauldin DM. Triple arthrodesis in adults. *Foot Ankle* 1991 ; 12 : 138-143
5. Chadha H, Pomeroy GC, Manoli A. Radiologic signs of unilateral pes planus. *Foot Ankle Int* 1997 ; 18 : 603-604
6. Conti S, Michelson J, Jahss M. Clinical significance of magnetic resonance imaging in preoperative planning for reconstruction of posterior tibial tendon ruptures. *Foot Ankle* 1992 ; 13 : 208-214
7. Draves D. *Anatomy of the Lower Extremity*. Williams & Wilkins, Baltimore, 1986, pp 270-271

8. **Evans D.** Calcaneo-valgus deformity. *J Bone Joint Surg* 1975 ; 57-B : 270-278
9. **Fayazi AH, Nguyen HV, Juliano PJ.** Intermediate-term follow-up of calcaneal osteotomy and flexor digitorum longus transfer for treatment of posterior tibial tendon dysfunction. *Foot Ankle Int* 2002 ; 23 : 1107-1111
10. **Frankel JP, Turf RM, Kuzmicki M.** Double calcaneal osteotomy in the treatment of posterior tibial tendon dysfunction. *J Foot Ankle* 1995 ; 34 : 254-261
11. **Frey C, Shereff M, Greenidge N.** Vascularity of the posterior tibial tendon. *J Bone Joint Surg* 1990 ; 72-A : 884-888
12. **Funk DA, Cass JR, Johnson KA.** Acquired adult flatfoot secondary to posterior tibial-tendon pathology. *J Bone Joint Surg* 1986 ; 68-A : 95-102
13. **Ghormley R, Spear I.** Anomalies of the posterior tibial tendon : A cause of persistent pain about the ankle. *Arch Surg* 1953 ; 66 : 512-515
14. **Goldner JL, Keats PK, Bassett FH, Clippinger FW.** Progressive talipes equinovagum due to trauma or degeneration of the posterior tibial tendon and medial plantar ligaments. *Orthop Clin North Am* 1974 ; 5 : 39-51
15. **Graves SC, Mann RA, Graves KO.** Triple arthrodesis in older adults. Results after long-term follow-up. *J Bone Joint Surg* 1993 ; 75-A : 355-362
16. **Hall RL.** Injuries of the posterior tibial tendon. In : Pfeffer GB, Frey CC (eds). *Current Practice in Foot and Ankle Surgery*, McGraw-Hill, New York, 1994, vol 2, pp 124-156
17. **Harper MC.** Talonavicular arthrodesis for the acquired flatfoot in the adult. *Clin Orthop* 1999 ; 365 : 65-68
18. **Hintermann B, Valderrabano V, Kundert HP.** Lengthening of the lateral column and reconstruction of the medial soft tissue for treatment of acquired flatfoot deformity associated with insufficiency of the posterior tibial tendon. *Foot Ankle Int* 1999 ; 20 : 622-629
19. **Hintermann B.** Flat foot deformity due to posterior tibial tendon insufficiency : osteotomy and reconstruction. In : Duparc J (ed). *EFORT Surgical Techniques in Orthopaedics and Traumatology*, Editions Scientifiques et Médicales Elsevier (Paris), 55-660-B-10, 2000.
20. **Hockenbury RT, Sammarco GJ.** Medial sliding osteotomy with flexor hallucis longus transfer for the treatment of posterior tibial tendon insufficiency. *Foot Ankle Clin* 2001 ; 6 : 569-581
21. **Inman V.** *Du Vries Surgery of the Foot*, C.V. Mosby, St. Louis, 1973, 31st ed, p 283
22. **Jahss MH.** Spontaneous rupture of the tibialis posterior tendon : Clinical findings, tenographic studies, and a new technique of repair. *Foot Ankle* 1982 ; 3 : 158-166
23. **Johnson KA.** Tibialis posterior tendon rupture. *Clin Orthop* 1983 ; 177 : 140-147
24. **Johnson KA, Strom DE.** Tibialis posterior tendon dysfunction. *Clin Orthop* 1989 ; 239 : 196-206
25. **Kapandji I.** *The Physiology of the Joints*. Churchill Livingstone, New York, 1970, 2nd ed, pp 170-194
26. **Key JA.** Partial rupture of the tendon of the posterior tibial muscle. *J Bone Joint Surg* 1953 ; 35-A : 1006-1008
27. **Kettelkamp DB, Alexander HH.** Spontaneous rupture of the posterior tibial tendon. *J Bone Joint Surg* 1969 ; 51-A : 759-764
28. **Kitaoka HB, Lundberg A, Luo ZP, An KN.** Kinematics of the normal arch of the foot and ankle under physiologic loading. *Foot Ankle Int* 1995 ; 16 : 492-499
29. **Kitaoka HB, Luo ZP, An KN.** Subtalar arthrodesis versus flexor digitorum longus tendon transfer for severe flatfoot deformity : An in vitro biomechanical analysis. *Foot Ankle Int* 1997 ; 18 : 710-715
30. **Koutsogiannis E.** Treatment of mobile flat foot by displacement osteotomy of the calcaneus. *J Bone Joint Surg* 1971 ; 53-B : 96-100
31. **Kulowski J.** Tendovaginitis (tenosynovitis). General discussion and report of one case involving the posterior tibial tendon. *J Wis State Med Assn* 1936 ; 33 : 135-137
32. **Lapidus PW, Seidenstein H.** Chronic non-specific tenosynovitis with effusion about ankle. *J Bone Joint Surg* 1950 ; 32-A : 175-177
33. **Lewis OJ.** The tibialis posterior tendon in the primate foot. *J Anat (Lond)* 1964 ; 98 : 209-218
34. **Mann RA, Specht LH.** Posterior tibial tendon ruptures : Analysis of eight cases. *J Foot Ankle* 1982 ; 2 : 350-353
35. **Mann RA, Thompson FM.** Rupture of the posterior tibial tendon causing flatfoot : Surgical treatment. *J Bone Joint Surg* 1985 ; 67-A : 556-561
36. **Mann RA, Bieman DN.** Double arthrodesis in the adult. *Clin Orthop* 1999 ; 365 : 74-80
37. **Mc Master P.** Tendon and muscle ruptures. *J Bone Joint Surg* 1933 ; 15 : 705-722
38. **Miller GR.** The operative treatment of hypermobile flat-foot in the young child. *Clin Orthop* 1977 ; 122 : 95-101
39. **Mosier SM, Lucas DR, Pomeroy GC, Manoli A.** Pathology of the posterior tibial tendon in posterior tibial tendon insufficiency. *Foot Ankle Int* 1998 ; 19 : 520-524
40. **Mueller TJ.** Acquired flatfoot secondary to tibialis posterior dysfunction : Biomechanical aspects. *J Foot Surg* 1991 ; 30 : 2-12
41. **Myerson MS, Corrigan J, Thompson F et al.** Tendon transfer combined with calcaneal osteotomy as treatment for posterior tibial tendon insufficiency. A radiological investigation. *Foot Ankle Int* 1995 ; 16 : 712-718
42. **Pomeroy GC, Manoli A.** A new operative approach for flatfoot secondary to posterior tibial tendon insufficiency : A preliminary report. *Foot Ankle Int* 1997 ; 18 : 206-212
43. **Pomeroy GC, Pike RH, Beals TC, Manoli A.** Acquired flatfoot in adults due to dysfunction of the posterior tibial tendon. *J Bone Joint Surg* 1999 ; 81-A : 1173-1182
44. **Shereff MJ.** Treatment of ruptured posterior tibial tendon with direct repair and FDL tenodesis. *Foot Ankle Clin* 1997 ; 2 : 281-296

45. **Speck M, Klaue K.** Medial flexor digitorum longus tendon augmentation and lateral foot column lengthening or reorienting triple arthrodesis as surgical therapy of posterior tibial tendon dysfunction. *Z Orthop Ihre Grenzgeb* 2001 ; 139 : 332-339
46. **Tachdjian M.** *Pediatric Orthopaedics*. W.B. Saunders, Philadelphia, 1972, pp 1266-1268
47. **Thomas RL, Wells BC, Garrison RL, Prada SA.** Preliminary results comparing two methods of lateral column lengthening. *Foot Ankle Int* 2001 ; 22 : 107-119
48. **Vogel KG, Ördög A, Pogany G et al.** Proteoglycans in the compressed region of human tibialis posterior tendon and in ligaments. *J Orthop Res* 1993 ; 11 : 68-77