



Fifteen years follow-up of hip arthroplasties with a cemented monoblock femoral stem and a flanged acetabular component

Michiel MULIER, Attah ESLAMI

From UZ Pellenberg, Lubbeek, Belgium

Our study evaluated the survival and complication rate of 147 total hip arthroplasties at least fifteen years after index surgery. All patients treated in our institution in 1986 with a cemented monoblock prosthesis and a flanged acetabular component were identified and a phone interview could be conducted with 144 (147 hips). No revisions for aseptic loosening were required and only 3 revisions of the index arthroplasty took place: one for infection (after 2 years), one for recurrent dislocation (after 13 years) and one for trochanteric bursitis where the wire was removed after 6 years and revision because of septic loosening was done after 14 years. Heterotopic ossification (HO) graded by means of the last follow-up radiograph showed that more than 50 % of the hips had grade I HO. These results indicate that the technique used for total hip replacement in this study is durable.

INTRODUCTION

Total hip arthroplasty (THA) is a commonly used treatment for end-stage arthritis. Since Gluck performed the first total hip replacement using an ivory prosthesis, the materials and the technique have continuously been improved. In 1960, Charnley used methacrylate cement for total hip prosthesis, a technique which is still in use today (3). Cemented fixation of the femoral stem is considered the gold standard for patients older than 60 years (9). The goal remains to minimise aseptic

loosening of the cemented femoral stems. Considering the life expectancy, long-term evaluation is imperative.

Because of the diversity in designs of implantable devices and of the influence of the technical skills of the surgeons applying the cement, there are limited long-term data available on the survival rates of THA done in the same centre, using the same devices and following a standardised procedure. However the need for revision and the time interval between index surgery and revision is indicative for the value of the technique, the prosthesis and the cost of surgical management of arthritis of the hip.

We reviewed the charts of 215 patients, who underwent 219 cemented THA's, performed in our centre in 1986. Attempts were made to contact all those patients 15 years after the intervention. We present the results of 144 patients (147 hips) who could be reached.

■ Michiel Mulier, MD, PhD, Associate Head of Department.

■ Attah Eslami, MD, Senior Assistant.

Department of Orthopaedic Surgery, UZ Pellenberg, Lubbeek, Belgium.

Correspondence: Michiel Mulier, Department of Orthopaedic Surgery, U.Z. Pellenberg, Weligerveld 1, 3212 Lubbeek (Pellenberg), Belgium.

E-mail: michiel.mulier@uz.kuleuven.ac.be.

© 2005, Acta Orthopædica Belgica.

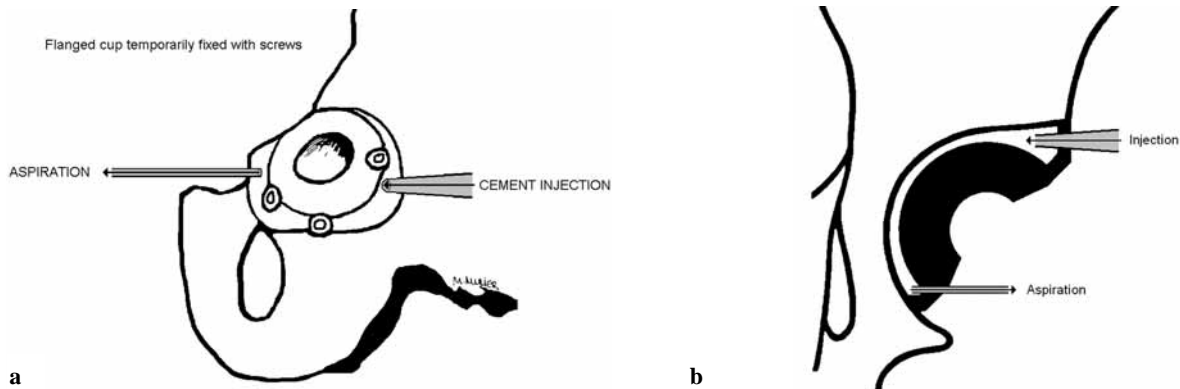


Fig. 1. — a) Schematic representation of the hydraulic pressurisation cementing technique. Low-viscosity cement is injected through one side of a closed-off acetabular cavity with the use of a flanged cup. On the other side continuous suction-vacuum is applied to aspirate the debris and fluids used for rinsing the cavity before injecting the cement ; b) Cross sectional drawing of the same hydraulic pressurisation cementing technique.

MATERIALS AND METHODS

Surgical technique

All patients were treated with a cemented monoblock prosthesis (Charnley or Müller, both with 22 mm heads) and a flanged acetabular component. In all patients surgery was performed through a lateral trans-trochanteric osteotomy. The acetabular component was fixed with the hydraulic cementing technique i.e. with the use of screws and pressurisation of the cement behind the acetabular component. In this original technique, a flanged cup is fixed with screws in the flange. The cavity between the cup and the acetabulum is rinsed with a waterjet gun with its nozzle through an injection hole of the flange. The water, blood and debris are removed by 2 suction devices through 2 outlet holes in the flange. After rinsing with 4 to 6 litres of saline, the nozzle of the waterjet gun is replaced by the nozzle of a cement gun and under increasing pressure liquid cement, less than 6 minutes after the start of mixing, is steadily injected behind the cup until the cement reaches the two "outlet" holes and suction tubes (fig 1 a, b). These holes are blocked once clear cement without blood and debris is pressurised out of the acetabular cavity. The cement gun is then removed and the injection hole blocked with a cement plug.

Peroperatively, all hips had a lavage with H₂O₂. The greater trochanter was reattached with the use of either Dall-cable and hook or stainless steel wires. Antibiotics were used prophylactically for all patients. Post-operatively all patients received anticoagulation therapy

(acenocoumarol Novartis, Belgium) and indomethacine twice daily for six weeks.

Patients

Out of the 215 patients who underwent 219 cemented THA, we could conduct a phone interview with 144 patients (147 hips) at least 15 years after surgery. Fifty-three patients (54 hips) had died and 18 were lost to follow-up.

Medically trained staff members who were not involved with the initial patient treatment conducted the survey.

We were unable to have the surviving patients return to our centre for clinical and radiographic evaluation. Heterotopic bone was graded according to the classification of Brooker on the last available follow-up radiograph, which was taken at least one year after the intervention.

Patient demographics

The 144 patients (40 men, 104 women) available for follow-up were on average 59.8 years old (range : 17.1 to 86.1) at the time of the index arthroplasty. In total 147 THAs were performed in these patients : 76 left sided, 63 right sided and 4 bilateral interventions ; 63 patients had already undergone a contralateral hip arthroplasty. One hundred forty-four were primary hip replacements and three were revisions for aseptic loosening of

Table I. — Preoperative diagnoses

Diagnosis	Number of hips (%) Total n = 147
Osteoarthritis	84 (59.2)
Hip dysplasia	23 (15.6)
Degenerative arthritis secondary to congenital hip dysplasia	11 (7.5)
Rheumatoid arthritis	6 (4.1)
Avascular necrosis	5 (3.4)
Revision THA	3 (2)
Ankylosis	3 (2)
Coxitis	3 (2)
Post traumatic arthritis	2 (1.4)
Slipped capital femoral epiphysis	2 (1.4)
Legg-Calvé-Perthes disease	1 (0.7)
Septic arthritis	1 (0.7)

previous arthroplasties of the hip performed for aseptic loosening. Acetabulum reconstruction had been performed in 38 hips. The preoperative diagnoses are listed in table I.

A previous operation had been done on 12 hips before the index arthroplasty; these procedures included fixation of a femoral neck fracture, varisation osteotomy and acetabuloplasty.

RESULTS

Fifteen-year results

Of the 144 patients (147 hips) who were still alive at least 15 years after surgery, 3 had revision surgery, indicating a 97.9% survival rate. Two revisions were performed because of septic loosening and one because of recurrent dislocation.

During the 15 years after the index arthroplasty, 36 patients underwent a contralateral intervention. All surgical interventions were initially considered as successful, one patient developed complication due to the trochanter cerclage wiring, which ultimately lead to revision.

No revisions for aseptic loosening were required. In total 3 revisions of the index arthroplasty were required. Three patients developed infections (less than five years postoperatively): one had a positive haemoculture (*Pseudomonas aeruginosa*), a second patient had a positive hip joint aspiration (coagulase

negative *staphylococcus*), and a third patient developed a sinus with a positive culture (*Acinetobacter*) on exploration of the sinus. They were treated with antibiotics. One of them underwent a revision arthroplasty two years after the index intervention. The other two patients were kept on a lifetime antibiotic treatment.

Thirty of the surviving patients developed trochanteric bursitis. In 13 patients the trochanteric wire and Dall cable were removed because of invalidating trochanteric bursitis and breakage of the trochanteric wire. In one patient the trochanteric wire was removed 6 years after the index arthroplasty, and he developed a septic loosening after 14 years, requiring a revision.

One patient had a revision for recurrent dislocation, 13 years after the index arthroplasty.

Two hips dislocated more than 10 years after the index arthroplasty and were treated by closed reduction with no recurrence.

Radiographs made at the last clinical follow-up, minimum one year after the intervention, were used to assess heterotopic bone formation, which was graded according to Brooker. Figure 2 shows the post-operative radiographs and those after more than 15 years. Heterotopic ossifications become visible within 6 months after surgery and remain unchanged. No hips were grade IV (ankylosis), 8 hips were grade III, 53 hips grade II and 80 hips grade I. The average Harris functional score for the surviving patients was 72.50 (range : 33 to 100).

DISCUSSION

Long-term evaluation of total hip arthroplasty is an accurate manner to judge the durability of the prosthesis and the acetabular cup fixation. The number of required revisions may be an indicator for the validity of the technique. Moreover, revisions are directly linked to increased costs for materials, medication, hospitalisation and rehabilitation.

Aseptic loosening of the acetabular component appears to be the major problem associated with total hip arthroplasty. Mulroy *et al* (7) reported 8% to 10% acetabular revision, while Madey *et al* (5)

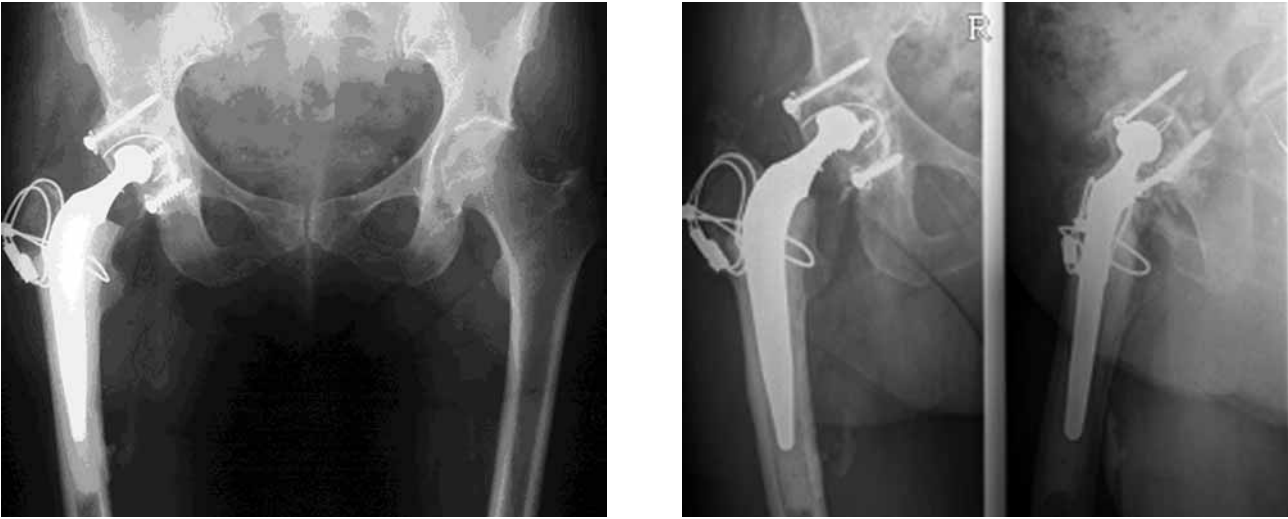

Fig. 2. — Initial postoperative radiograph (left) and follow-up radiograph more than 15 years after surgery (right) of a flanged cup fixed with hydraulic pressurisation cementing technique.

noted 22% acetabular loosening with 12% revision at 15 years. Recently Callaghan *et al* (2) described the thirty years follow-up results of 27 patients and 34 hips, representing 10.3% of the initial study group, still alive at least 30 years after THA. Twenty-three hips or 7.3% of the initial study group had revision because of aseptic loosening of the acetabular component. In our series we had not one hip revised because of aseptic loosening. The hydraulic pressurisation cementing technique may well be responsible for an improved cement interdigitation with the subchondral trabecular bone.

The 1.36% revision rate because of infection is in line with the incidence mentioned in the literature, which ranges from 0.4% to 1.5% when prophylactic antibiotics are used (1).

The incidence of dislocation in our study is 2%, which compares favourably with the incidence of approximately 3% (range : 0.6 to 5.8) mentioned in reference works (4).

Greater trochanter bursitis and heterotopic ossifications were major problems in our study. Thirteen patients had a second operation because of invalidating trochanter bursitis or breakage of the trochanteric wire. Trochanter osteotomy is no longer used in our institution. The reported incidence of heterotopic ossification after THA has

ranged from 0.6% to 61.7% with the highest incidence in patients with ankylosing spondylitis (8, 10). Heterotopic ossification or ectopic bone formation after total hip arthroplasty may compromise the postoperative result by limiting the range of motion. The functional capacity was significantly reduced when grade III heterotopic ossification was associated with revision surgery, previous HO, ankylosing spondylitis, DISH (diffuse idiopathic skeletal hyperostosis), neuropathic conditions, Paget's disease and extensive surgical dissection. According to some studies (6), the lateral transtrochanteric approach was associated with more ectopic bone formation than other approaches, but the differences lack statistical significance.

Most primary THAs and many revisions are currently done without osteotomy of the greater trochanter in our institution. Greater trochanteric osteotomy is essential in certain situations and advantageous in others like revisions or primary THA for congenital dislocation of the hip. Trochanteric osteotomy is mandatory when wide exposure is necessary for complex acetabular or femoral reconstruction.

The endpoint for the failure of a THA is not always a revision, for instance if the patient is completely immobilised and not in need of a revision,

which was mainly the case for elderly patients who were cared for by their families.

CONCLUSION

Our data indicate that the cemented monoblock prosthesis (Charnley or Müller with a 22-mm head) with a flanged acetabular component is durable, and no revisions for aseptic loosening were required. The improved cement interdigitation with the subchondral trabecular bone, can probably be attributed to the hydraulic pressurisation cementing technique. The lateral transtrochanteric osteotomy may be responsible for the relatively high rate of bursitis, indicating that the patient selection for this approach needs to be carefully done.

REFERENCES

1. **Brause B.** Infections with prostheses in bones and joints. In : Mandell, ed. *Principles and Practice of Infectious Diseases*. 5th ed. Churchill Livingstone, Inc, 2000 : pp 1196-1200.
2. **Callaghan JJ, Templeton JE, Liu SS et al.** Results of Charnley total hip arthroplasty at a minimum of thirty years. A concise follow-up of a previous report. *J Bone Joint Surg* 2004 ; 86-A : 690-695.
3. **Fischer LP, Planchamp W, Fischer B, Chauvin F.** The first total hip prostheses in man (1890 - 1960)). *Hist Sci Med* 2000 ; 34 : 57-70.
4. **Harkess J.** Arthroplasty of Hip. In : Canale, ed. *Campbell's Operative Orthopaedics*. 10th ed. Mosby, Inc, 2003 : pp 315-482.
5. **Madey SM, Callaghan JJ, Olejniczak JP et al.** Charnley total hip arthroplasty with use of improved techniques of cementing. The results after a minimum of fifteen years of follow-up. *J Bone Joint Surg* 1997 ; 79-A : 53-64.
6. **Morrey BF, Adams RA, Cabanela ME.** Comparison of heterotopic bone after anterolateral, transtrochanteric, and posterior approaches for total hip arthroplasty. *Clin Orthop* 1984 ; 188 : 160-167.
7. **Mulroy WF, Estok DM, Harris WH.** Total hip arthroplasty with use of so-called second-generation cementing techniques. A fifteen-year-average follow-up study. *J Bone Joint Surg* 1995 ; 77-A : 1845-1852.
8. **Pagnani MJ, Pellicci PM, Salvati EA.** Effect of aspirin on heterotopic ossification after total hip arthroplasty in men who have osteoarthritis. *J Bone Joint Surg* 1991 ; 73-A : 924-929.
9. **Valdivia GG, Dunbar MJ, Parker DA et al.** The John Charnley Award : Three-dimensional analysis of the cement mantle in total hip arthroplasty. *Clin Orthop* 2001 ; 393 : 38-51.
10. **Yoon TR, Rowe SM, Jung ST et al.** Osteolysis in association with a total hip arthroplasty with ceramic bearing surfaces. *J Bone Joint Surg* 1998 ; 80-A : 1459-1468.