



A radiological study of the intraprosthetic movements of the bipolar shoulder replacement in rheumatoid arthritis

Caroline HING, Alex BODDY, Damian GRIFFIN, Philip EDWARDS, Paul GALLAGHER

Study performed at The Institute of Orthopaedics, The Norfolk & Norwich University Hospital, Norwich, Norfolk, UK

A radiological study of the intraprosthetic movements of a bipolar shoulder replacement was undertaken in 25 shoulders in 20 patients with rheumatoid arthritis and rotator cuff arthropathy. No significant difference was found between intraprosthetic movement and shell - glenoid movement. Some shoulders were found to exhibit paradoxical movement at the intraprosthetic interface. Repeating the measurements after an interval of three years in a subgroup of 12 shoulders showed a significant reduction in intraprosthetic movement over this time interval. In conclusion, movement of the bipolar shoulder prosthesis in shoulders affected by rheumatoid arthritis was preserved up to eight years from operation. Intraprosthetic movement was independent from shell - glenoid movement and paradoxical to glenohumeral movement.

INTRODUCTION

Rheumatoid arthritis results in pain and loss of function due to progressive destruction of the articular cartilage and soft tissue involvement. It frequently affects the shoulder joint and when coupled with rotator cuff arthropathy results in superior migration of the humeral head due to the unopposed action of the deltoid (10). Although prosthetic replacement of the humeral head can restore function and relieve pain, superior migration in the absence of a fully functioning rotator cuff can result in glenoid loosening, instability and subacromial wear (10, 12).

Bipolar shoulder replacement, first described by Swanson *et al* in 1975 (10), has been used in the treatment of rheumatoid arthritis, primary osteoarthritis, painful rotator cuff arthropathy, avascular necrosis, revisions and fractures (2, 6, 9, 10, 12, 13). The birotational feature of the bipolar replacement provides two 'joints' at which movement can occur, the intraprosthetic interface (between the head and shell) and the shell - glenoid interface (fig 1). It has the theoretical advantages of (1) providing a smooth concentric total contact area, thereby reducing the force over any one contact area and (2) lengthening the moment arm, thus preventing abutment of the greater tuberosity against the

■ Caroline B. Hing, BSc., MSc., MD, FRCS(Tr & Orth),
Research Fellow in Trauma & Orthopaedics.

■ Alex Boddy, MA, MRCS, Senior House Officer.

■ Paul Gallagher, FRCS, Consultant in Trauma & Orthopaedics.

Norfolk & Norwich University Hospital, Norwich, UK.

■ Damian Griffin, MA, MPhil(Epid), FRCS(Tr & Orth),
Professor of Trauma & Orthopaedic Surgery.

University of Warwick, Warwick, UK.

■ Philip Edwards, MA, AFOM, FRCS, FRCR, Honorary
Consultant Radiologist.

Royal Free Hospital, London, UK.

Correspondence : Caroline B. Hing, The Institute of
Orthopaedics, The Norfolk & Norwich University Hospital,
Colney Lane, Norwich, Norfolk. NR4 7UY, UK.

E-mail : CaroH2712@aol.com.

© 2005, Acta Orthopædica Belgica.

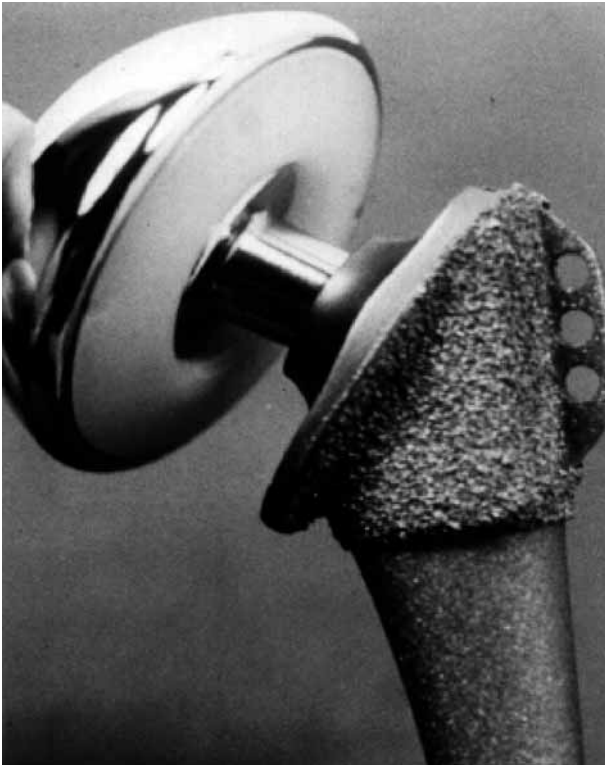

Fig. 1. — The Biomet bipolar shoulder replacement consists of a birotational head that allows movement at the intraprostatic interface and also between the shell and glenoid.

acromion and allowing the cup to align itself within the glenoid (10).

Longevity of movement at the intraprostatic interface of the bipolar shoulder prosthesis is debatable and has not previously been studied with long-term follow-up in rheumatoid arthritis (6, 10, 12). Studies of preservation of birotational movement in hips have provided conflicting results (3, 5, 7, 11). The purpose of this study was (1) to perform a radiographic evaluation of the motion at the intraprostatic and shell - glenoid interfaces in patients with rheumatoid arthritis and (2) to determine whether motion at these interfaces is preserved.

MATERIALS AND METHODS

Subject Demographics

Between 1992 and 1997, 36 shoulders in 30 patients with a diagnosis of rheumatoid arthritis (as defined by

the American Rheumatism Association (1)) with rotator cuff arthropathy were replaced with a bipolar shoulder arthroplasty by the senior author. All patients were invited to participate in the study, ten declined. Twenty-five shoulders in 20 patients formed the prospective cohort study group, and were recalled for radiographic examination. The mean age was 66 years with a standard deviation of 10 years. Seventeen of these patients were female and three were male. Of the 25 shoulders, 13 were right and 12 were left. The mean time from operation was six years, with a range of three to eight years.

As a feasibility trial, a subgroup of twelve shoulders (seven right, five left) in eight of the same patients had previously undergone radiographic evaluation. Of these eight patients, seven were female and one male. These patients were recalled and included in the full study.

Surgical technique

Patients were positioned in a modified 'deck chair' position. All surgery was performed by the senior author. A standard Neer deltopectoral approach was used. The glenoid was not reamed. The humerus was prepared and the implant inserted without cement fixation. Correct tissue tensioning was achieved by varying the neck length and outer shell diameter as performed by the senior author to allow acceptable stability whilst still preserving mobility and avoiding oversizing of the prosthesis ('over-stuffing'). A Biomet bipolar prosthesis was used in all cases with a 22.2-mm diameter head and an external shell diameter varying between 40 and 48 mm. The rotator cuff was found to be significantly affected in all cases, no attempt at reconstruction was made other than to achieve the correct tissue tensioning during closure.

Selection

Patients with a Biomet bipolar shoulder prosthesis implanted for rheumatoid arthritis uncomplicated by infection or loosening were invited to participate in the study which was prospective. Patients unable to comply or consent were excluded from the study, as were any with significant concomitant pathology. Patients who met the selection criteria were included in the study. The study was approved by the Norfolk and Norwich District Ethics Committee (NDEC Ref No : 98/064) and Norfolk & Norwich Research and Development Committee (98OR04).

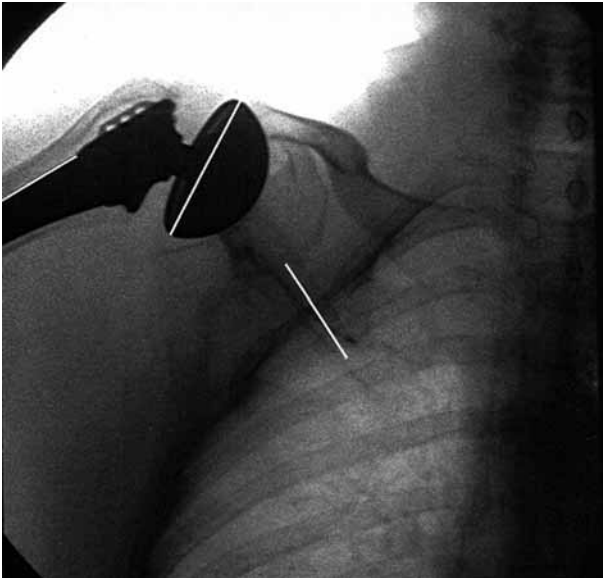


Fig. 2. — Radiograph of the shoulder in the scapular plane with the arm in full active abduction. The base of the shell, the lateral border of the stem and the scapular spine were used as landmarks.

Methods

Each patient stood in front of an image intensifier, with the shoulder to be studied positioned in the scapular plane. A radiograph was taken with the shoulder in neutral and another radiograph was taken with the shoulder in full active abduction. The effective dose of radiation administered to each patient was 0.1-1 mSv, with an anticipated dose of 0.4 mSv for the study.

Measurements were made from the shoulder radiographs by two observers on two separate occasions. The spine of the scapula and lateral border of the scapula were used as landmarks to determine abduction range with respect to the scapula. The lateral border of the humeral stem and the base of the shell were used as landmarks of the bipolar prosthesis to determine the angle between the stem and shell in neutral and full active abduction. The lateral border of the stem and the scapular landmarks were used to determine the extent of glenohumeral range in neutral and full active abduction. Thus the shell - glenoid range could be determined by subtraction (fig 2).

Statistical analysis

Measurements were repeated by the two observers on two separate occasions. The resultant mean of the four measurements taken was used in the statistical analysis. An SPSS version 9.0 statistical package was used to analyse the results. Movements at the intraprosthetic interface and shell - glenoid interface were compared using a paired t-test to determine if there was a significant difference between the movements in each shoulder. A Pearson Correlation Coefficient was used to determine if the movements at the interfaces correlated.

A paired t-test was used to compare the measurements of movement at the intraprosthetic interface in the subgroup of twelve shoulders where measurements had been repeated three years later, in order to determine if movement changed significantly. The movement at the shell - glenoid interface was also analysed in a similar manner using a paired t-test.

The reliability of measurement was determined by repeating the measurements of intraprosthetic movement and total glenohumeral movement by two observers on two separate occasions. An Intraclass Correlation Coefficient was used to determine inter-observer and intra-observer reliability.

RESULTS

Movement in all shoulders at a range of three to eight years from surgery was preserved. In the majority of shoulders, the range of abduction was paradoxical at either surface, with a negative value for abduction range. The range of movement for mean measurements taken by both observers on two occasions is shown in table I. The mean values for the four observations taken of each measurement are summarised in table II. The mean intraprosthetic abduction was $+3.41^\circ$ (SD 9.47°), mean shell - glenoid abduction was $+7.75^\circ$ (SD 14.30°) and mean total glenohumeral abduction was $+11.85^\circ$ (SD 15.92°). A paired t-test comparing the movement at the intraprosthetic interface with that at the shell - glenoid showed that there was no significant difference between the two movements ($p = 0.275$). A Pearson Correlation Coefficient test showed no correlation between intraprosthetic movement and shell - glenoid movement (table III). Both intraprosthetic movement and shell - glenoid movement did show

Table I. — Range of movement for mean values of intraprosthetic and shell - glenoid movement

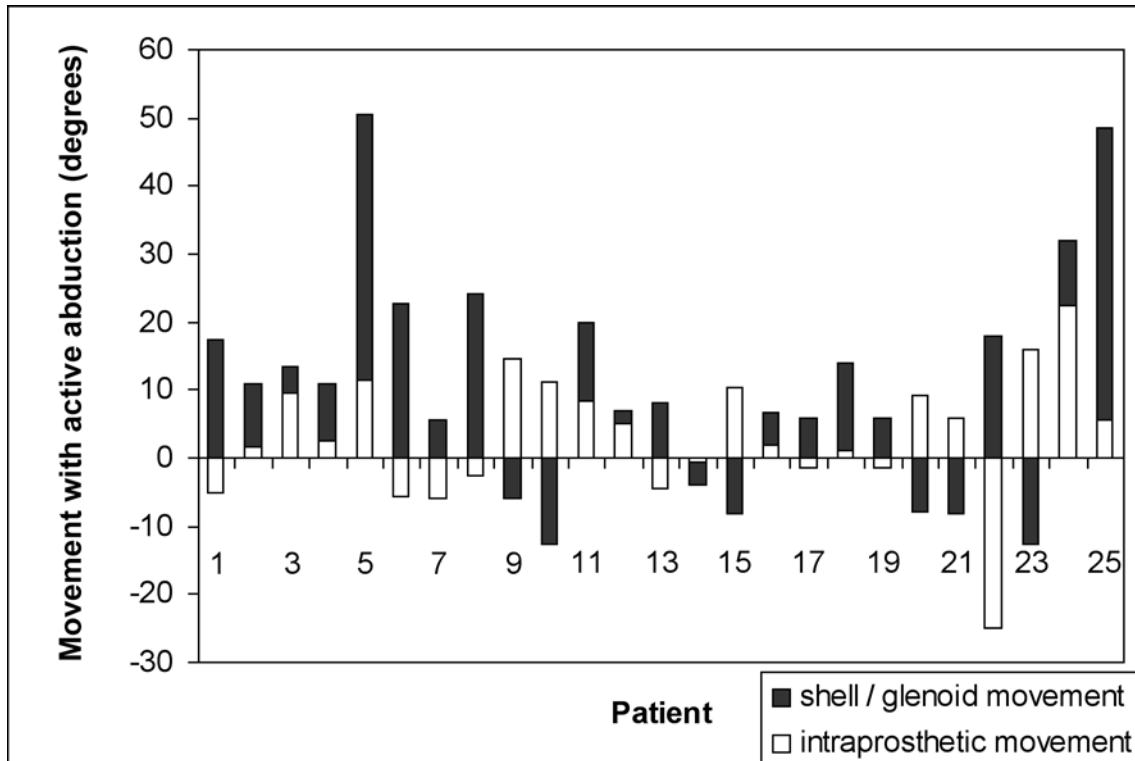


Table II. — Descriptive statistics of intraprosthetic, shell - glenoid and total glenohumeral movement

	N	Minimum	Maximum	Mean	SD
Intraprosthetic	25	-25.00	22.50	3.41	9.47
Shell - glenoid	25	-12.75	43.00	7.75	14.30
Glenohumeral	25	-7.00	53.00	11.85	15.92

a positive correlation with total glenohumeral movement.

A comparison of values obtained for intraprosthetic and shell - glenoid movements taken three years apart is summarised in table IV. A paired t-test performed to compare the movements showed a significant ($p = 0.010$) reduction in movement at the intraprosthetic interface with time. Movement at the shell - glenoid interface showed no significant change with time.

Both intra-observer and inter-observer measurement reliability was determined using an Intraclass Correlation Coefficient. The measurement reliability is summarised in table V. Measurements

showed substantial agreement, thus showing that the methods used were reliable.

DISCUSSION

Rheumatoid arthritis of the shoulder is always concomitant with rotator cuff pathology and frequently results in superior subluxation of the humeral head. A bipolar shoulder arthroplasty has the advantage of a large head, moving the centre of rotation laterally and allowing improved efficiency of the deltoid in abduction (10). Restoration of the humeral lateral offset following bipolar shoulder arthroplasty has been shown to occur in previous

Table III. — Pearson correlation coefficients comparing mean movements in the bipolar shoulder arthroplasty with active abduction

	Intraprosthetic	Shell - glenoid	Glenohumeral
Intraprosthetic			
Pearson correlation	1.000	-0.307	0.403*
Sig. (2-tailed)		0.135	0.046
N	25	25	25
Shell - glenoid			
Pearson correlation	-0.307	1.000	0.733**
Sig. (2-tailed)	0.135		0.000
N	25	25	25
Glenohumeral			
Pearson correlation	0.403*	0.733**	1.000
Sig. (2-tailed)	0.046	0.000	
N	25	25	25

* Correlation is significant at the 0.05 level (2-tailed).

** Correlation is significant at the 0.01 level (2-tailed).

Table IV. — Results of mean measurements taken after 3 years

	1998		2002		p value
Intraprosthetic	8.75	(SD 13.67)	2.60	(SD 7.00)	0.010
Shell - glenoid	5.23	(SD 9.84)	5.40	(SD 9.99)	0.307
Glenohumeral	13.27	(SD 12.69)	8.00	(SD 8.12)	0.164

Table V. — Measurement reliability tested using an Intraclass Correlation Coefficient.

	Intraprosthetic	Glenohumeral
Interobserver	0.92 (excellent)	0.65 (substantial)
Intraobserver	0.94 (excellent)	0.93 (excellent)

studies, with some reporting an increase in offset and superior migration (2, 10, 12).

Previous radiographic studies of movement in osteoarthritic patients with a functioning rotator cuff have shown that movement is preserved between the head and shell as well as between the shell and natural glenoid (2) but no association was seen between the number of years of follow-up and the motion between the head and the shell. In patients with painful rotator cuff arthropathy, movement between the head and shell has been shown to persist at five years from surgery (13) but the relationship between number of years of fol-

low-up and degree of motion was not investigated. Studies of bipolar shoulder arthroplasty for painful conditions of the shoulder have included a small subgroup of patients with rheumatoid arthritis (two) and shown that intraprosthetic motion persists up to six years from surgery (12). There is no previous study of intraprosthetic movement of the bipolar shoulder exclusively in rheumatoid arthritis.

We agree with previous studies that movement in the bipolar shoulder arthroplasty occurs at both the intraprosthetic interface and the shell - glenoid interface (8). However, we found no correlation or significant difference between the different inter-

faces and found that in a subgroup of patients, there was a significant reduction in movement at the intraprosthesis interface with time. Unlike other studies, we found that the movements at the interfaces were paradoxical, with a variation in the direction of movement with abduction. The magnitude of movement at each interface in abduction was found to be small compared to other studies, with a total glenohumeral abduction of only 11.85°. However, the variation in range of movement between the patients was large (SD 15.92).

Our radiographic findings confirm the theoretical advantages of the bipolar shoulder arthroplasty, with range of movement maintained at eight years from surgery. The effect of alteration of shoulder biomechanics on movement and postoperative symptoms is not known. The state of the soft tissues and the severity of the disease process is also significant. Significant deficiency of the rotator cuff was found in all cases with no repair attempted at the time of surgery. The combination of rheumatoid arthritis and deficient rotator cuff may explain the lower range of active abduction compared to other studies.

Whilst other studies have shown preservation of movement at the intraprosthesis interface with time (9), our study showed that movement at the intraprosthesis interface, although present was significantly reduced at three years and may reduce further with time.

The degree of scapulo-thoracic movement that contributes to the arc of total active abduction also needs further investigation. Radiographic evaluation of scapulo-thoracic movement using the clavicle or cervical spine as landmarks showed poor interobserver and intraobserver agreement and was therefore not included in the present study. Previous studies of the biomechanics of the shoulder joint have shown that the contributions of gleno-humeral and scapulo-thoracic motion to scapular plane abduction are altered by pathology and arthroplasty. The ratio of glenohumeral to scapulothoracic movement can vary from a ratio of 2:1 in normal individuals to 1:2 in osteoarthritis or rheumatoid arthritis (4). Insertion of a prosthesis may alter this ratio and the degree of variation in movement will depend on a number of factors,

including the lateral offset, shell size and tissue tensions involved. 'Overstuffing' the shoulder joint may well result in a reduction of movement at the shell – glenoid interface. A comparison of movement in patients with rotator cuff arthropathy in rheumatoid arthritis documented intraoperatively and those with osteoarthritis with an unaffected rotator cuff is needed.

In conclusion, our study has shown that the bipolar shoulder prosthesis continues to move at both the intraprosthesis interface and shell glenoid interface with paradoxical movement present at both. These findings have relevance on future treatment strategies of patients with a combination of rheumatoid arthritis and a deficient rotator cuff. In these patients a bipolar arthroplasty will allow preservation of active abduction by allowing movement at both the intraprosthesis interface and shell-glenoid interface. However a wide variation of possible direction of movement (at times paradoxical) occurs at the intraprosthesis interface resulting in a small range of combined active abduction at the glenohumeral joint. In these cases patients should be warned that their range of active abduction is likely to be poor and may decrease significantly over time.

Further studies are needed to determine the effect of rotator cuff pathology on movement of shoulder prostheses in general and the bipolar prosthesis in particular in shoulders affected by rheumatoid arthritis where erosion of the glenoid and acromial arch may also have a correlation to movement of the prosthesis.

REFERENCES

1. **Arnett FC, Edworthy SM, Bloch DA et al.** The American Rheumatism Association 1987 revised criteria for the classification of rheumatoid arthritis. *Arthritis & Rheumatism* 1988 ; 31 : 3 : 315-324.
2. **Arrendondo J, Worland RL.** Bipolar shoulder arthroplasty in patients with osteoarthritis : short-term clinical results and evaluation of birotational head motion. *J Shoulder Elbow Surg* 1999 ; 8 : 425-429.
3. **Chen SC, Badrinath K, Pell LH, Mitchell K.** The movements of the components of the Hastings bipolar prosthesis. A radiographic study in 65 patients. *J Bone Joint Surg* 1989 ; 71-B : 186-188.

4. **Friedman RJ.** Prospective analysis of total shoulder arthroplasty biomechanics. *Am J Orthop* 1997 ; 26 : 265-270.
5. **Izumi H, Torisu T, Itonaga I, Masumi S.** Joint motion of bipolar femoral prostheses. *J Arthroplasty* 1995 ; 10 : 237-243.
6. **Lee DH, Niemann KMW.** Bipolar shoulder arthroplasty. *Clin Orthop* 1994 ; 304 : 97-107.
7. **Mess D, Barmada R.** Clinical and motion studies of the Bateman bipolar prosthesis in osteonecrosis of the hip. *Clin Orthop* 1990 ; 251 : 44-47.
8. **Petroff E, Mestdagh H, Maynou C, Delobelle JM.** Arthroplasty with a mobile cup for shoulder arthrosis with irreparable rotator cuff rupture : preliminary results and cineradiographic study. *Rev Chir Orthop* 1999 ; 85 : 245-256.
9. **Sarris IK, Papadimitriou NG, Sotereanos DG.** Bipolar hemiarthroplasty for chronic rotator cuff tear arthropathy. *J Arthroplasty* 2003 ; 18 : 169-173.
10. **Swanson AB, De Groot Swanson G, Sattel AB, Cendo RD, Hynes D, Jar-Ning W.** Bipolar implant shoulder arthroplasty, long-term results. *Clin Orthop* 1989 ; 249 : 227-247.
11. **Verbene GHM.** A femoral head prosthesis with built in joint. A radiological study of the movements of the two components. *J Bone Joint Surg* 1983 ; 65-B : 544-547.
12. **Worland RL, Arredondo J.** Bipolar shoulder arthroplasty for painful conditions of the shoulder. *J Arthroplasty* 1998 ; 13 : 631-637.
13. **Worland RL, Jessup DE, Arredondo J, Warbuton KJ.** Bipolar shoulder arthroplasty for rotator cuff arthropathy. *J Shoulder Elbow Surg* 1997 ; 6 : 512-515.