



## Complications following resection of the olecranon bursa

Ilse DEGREEF, Luc DE SMET

*From the University Hospital Pellenberg, Pellenberg, Belgium*

**We retrospectively reviewed 37 cases of resection of the olecranon bursa and noted wound healing problems in 10 (27%) and recurrence in 8 (22%). A lateral arm flap was necessary in one patient. Conservative treatment remains the treatment of choice for olecranon bursitis. Differentiation between septic and non-septic cases is challenging. The risk of wound healing problems and recurrence should be taken into account when planning surgical resection.**

**Keywords :** olecranon bursa ; resection ; complications.

### INTRODUCTION

In patients presenting with an acute olecranon bursitis, a distinction must be made between septic and non-septic conditions. It is sometimes necessary to drain and excise the bursa in cases with fulminating inflammation. However in chronic bursitis, the complaints are often less severe and a decision to excise the bursa has to be weighted against the operative risks. Although it is technically simple surgery, wound healing may be problematic. We retrospectively studied 40 patients who underwent surgical excision of the olecranon bursa because of chronic bursitis.

### MATERIAL AND METHODS

The medical records of all cases of olecranon bursa resection performed between February 1999 and May 2005 were retrospectively analysed, excluding all patients operated elsewhere. We retrieved 40 operations

in 38 patients with chronic olecranon bursitis. Surgery consisted of open resection of the bursa under regional or general anaesthesia in day care conditions. Gout (one patient, two elbows) and rheumatoid arthritis (one elbow) were excluded. Of the remaining 37 operations, the bursitis appeared posttraumatic in 12. Septic bursitis with sinus formation was seen in three cases. An underlying bony spur was present in three. The mean age of the patients at the time of surgery was 52 years (range : 21 to 78). There were 35 males and 1 female ; 31 patients had no significant medical history, 1 patient (two elbows) with lupus erythematosus received coumarines (temporarily replaced by low molecular weight heparin) for a history of deep venous thrombosis ; 1 had insulin dependent diabetes, 1 had poliomyelitis with heart and lung disease and 1 had supraventricular fibrillation. In all patients, a longitudinal posteromedial incision was made over the olecranon. After excision of the bursa, thorough haemostasis was done. Postoperatively the arm was immobilised in a collar and cuff splint for ten days. After this, normal mobilisation of the elbow was allowed. Patients were invited for a follow-up evaluation

---

■ Ilse Degreef, MD, Orthopaedic Surgeon, Assistant Surgeon-in-Chief.

■ Luc De Smet, MD, PhD, Orthopaedic Surgeon, Surgeon-in-Chief.

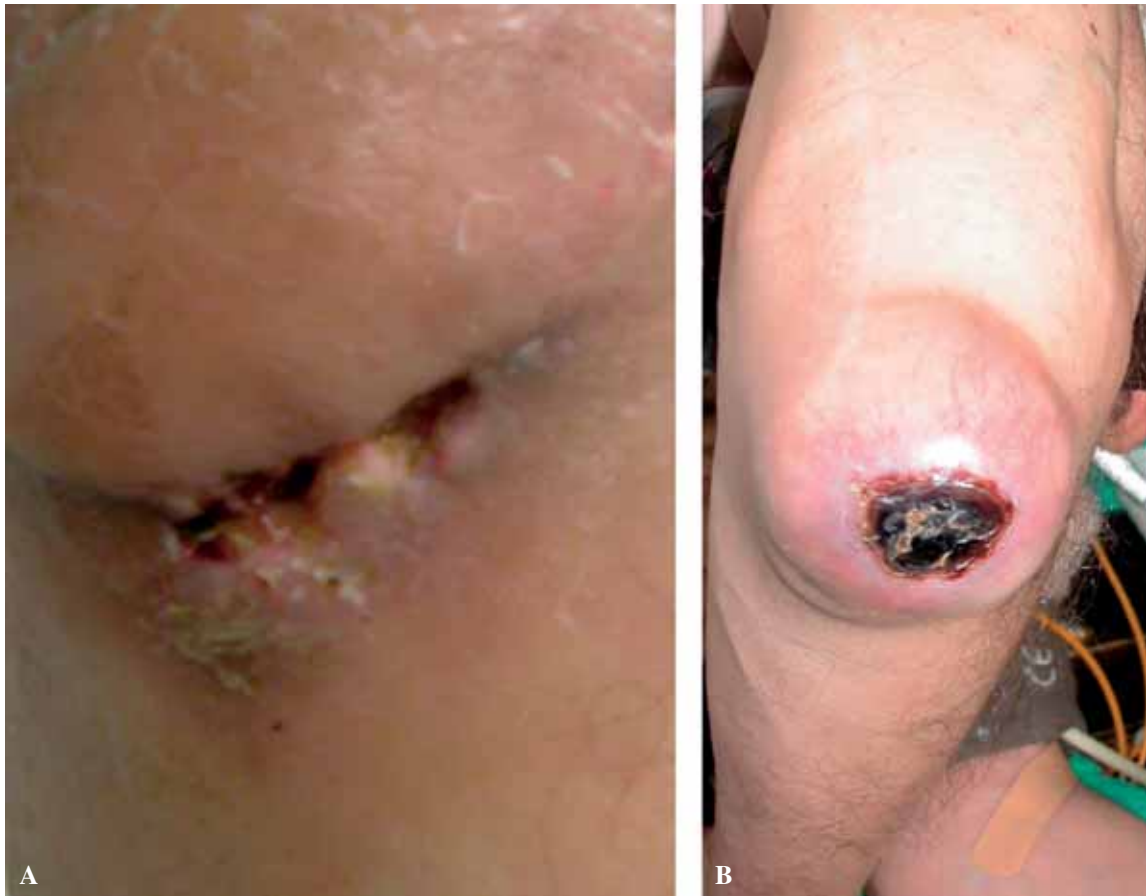*Department of Orthopaedic Surgery, University Hospital Pellenberg, Pellenberg, Belgium.*

Correspondence : Ilse Degreef, Department of Orthopaedic Surgery, University Hospital Pellenberg, Weligerveld 1, B-3212 Pellenberg, Belgium.

E-mail : ilse.degreef@uz.kuleuven.ac.be.

© 2006, Acta Orthopædica Belgica.

---



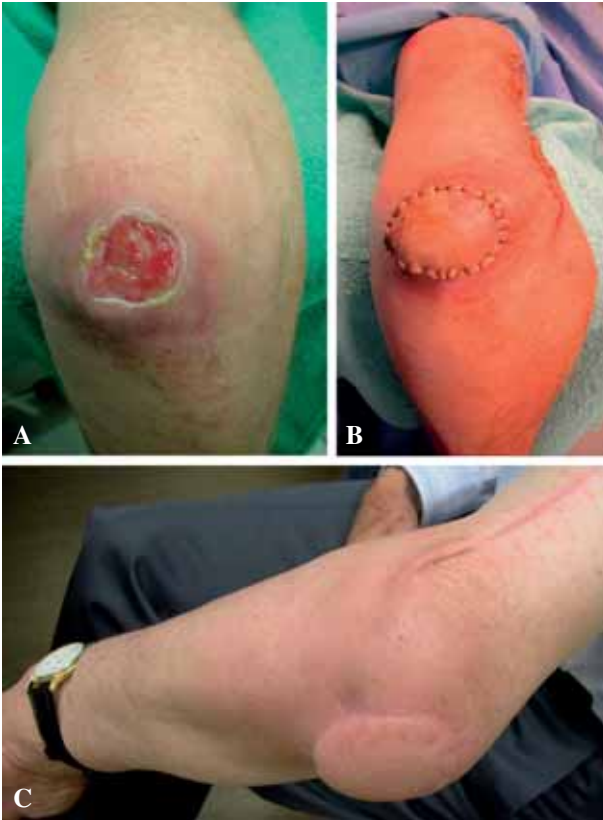
*Fig. 1.* — Examples of prolonged wound draining (A) and skin necrosis (B) after olecranon bursectomy

at 2, 4 and 12 weeks postoperatively. Attention was set on wound healing problems (haematoma, prolonged exudation, skin necrosis) and recurrence.

## RESULTS

In 16 (43%) of the 37 operations, the wound healed uneventfully and the patient could start exercises after ten days and after stitch removal. In 10 patients (27%) there was a prolonged exudation lasting for an average of 31 days (range : 14 to 92). In 8 patients (22%) a recurrence was seen after a mean of 51 days (range : 21 to 84). Of these cases, 4 were treated by one or more aspirations. One patient refused further treatment. In three cases a further resection of the bursa was performed, but in

two of them the bursitis recurred again and a lateral arm flap was done to replace the bursa and the overlying attenuated skin. In the third case the revision surgery ended in an infection, requiring debridement. In the 3 patients with a preoperative draining sinus and in an additional 5 (3 idiopathic, 2 posttraumatic), an infection was diagnosed and antibiotics were associated with the surgery for 7 days. There was an uneventful healing in these 8 cases. One elbow wound in the patient on anticoagulation showed prolonged oozing and the other developed an important haematoma. An important haematoma was seen in 5 patients, was aspirated in 2 and ended up in fistula formation in one. One of these patients showed a prolonged exudation for 6 weeks and in 2 cases spontaneous resorption occurred.



**Fig. 2.** — Skin necrosis after recurrent bursitis (A), requiring flap surgery (here a reversed lateral arm flap) (B) with a good final result (C).

## DISCUSSION

Chronic olecranon bursitis is a common condition often originating from a traumatic event. Because of its subcutaneous localisation, the bursa is vulnerable to persisting pressure, trauma and infection. Often the bursitis arises without a clear cause. The bursa is a subcutaneous space, lined with a fluid-secreting synovial membrane. It secures low-friction mobility between skin and olecranon and is susceptible to inflammation. Conservative treatment using anti-inflammatory drugs, rest, physiotherapy and splinting usually resolves this condition. Pyogenic infection has to

be excluded when suspected, because osteomyelitis of the underlying ulna may occur. The differentiation of septic and aseptic olecranon bursitis can be challenging (1, 8). Fatal septicaemia was even reported in 1928, before antibiotics were discovered (7). The most common pathogen is *Staphylococcus aureus* (2, 4). If infection is apparent, oral or intravenous antibiotics have to be associated and sometimes surgical intervention with abscess evacuation and extensive local debridement is necessary (4). Aseptic aspiration and corticosteroid injection of the bursa can be attempted, but is risky if infection is not ruled out, and skin atrophy can be disastrous, making flap surgery necessary (8, 11).

Although skin complications are feared, resection of the bursa is often attempted if swelling and complaints persist after conservative treatment. Standard open resection or endoscopic bursa resection can be considered (6, 9). If present, a bony spur on the olecranon can be removed (7). In this study we demonstrated that wound healing after simple olecranon bursectomy is not easily achieved. Prolonged exudation occurred in more than 25% of the patients, and rest (arm sling or even plaster splint) was necessary. There was recurrence of the bursitis in more than 1 in 5 patients, necessitating further treatment. When resection of the bursa fails or when the skin coverage undergoes necrosis, a lateral arm flap can be the ultimate solution, as was done in one of the patients in this study (3, 5, 10).

Because complications after bursectomy and recurrence are relatively frequent, conservative treatment with immobilisation in a well-padded cast is the first option. If surgery is inevitable, careful postoperative management is necessary and three to four weeks of cast immobilisation should also be considered.

## CONCLUSION

Surgical resection of a chronic olecranon bursitis should not be considered lightly. Wound healing is often slow with prolonged draining and recurrence is not exceptional, making flap surgery necessary in some cases. Conservative treatment, including immobilisation of the elbow, should be offered a full trial.

## REFERENCES

1. **Floemer F, Morrison WB, Bongartz G, Ledermann HP.** MRI Characteristics of olecranon bursitis. *Am J Roentgenol* 2004 ; 183 : 29-34.
2. **Garcia-Porrúa C, Gonzalez-Gay MA, Ibanez D, Garcia-Pais MJ.** The clinical spectrum of severe septic bursitis in Northwestern Spain : a 10 year study. *J Rheumatol* 1999 ; 26 : 663-667.
3. **Lai CS, Tsai CC, Liao KB, Lin SD.** The reverse lateral arm adipofascial flap for elbow coverage. *Ann Plast Surg* 1997 ; 39 : 196-200.
4. **Laupland KB, Davies HD.** Olecranon septic bursitis managed in an ambulatory setting. *Clin Invest Med* 2001 ; 24 : 171-178.
5. **Maruyama Y, Takeuchi S.** The radial recurrent fasciocutaneous flap : reverse upper arm flap. *Br J Plast Surg* 1986 ; 39 : 458-461.
6. **Olgivie-Harris DJ, Gilbert M.** Endoscopic bursal resection : the olecranon bursa and prepatellar bursa. *Arthroscopy* 2000 ; 16 : 249-253.
7. **Quayle JB, Robinson MP.** A useful procedure in the treatment of chronic olecranon bursitis. *Injury* 1978 ; 9 : 299-302.
8. **Smith DL, McAfee J, Lucas LM et al.** Septic and non-septic olecranon bursitis. Utility of the surface temperature probe in the early differentiation of septic and nonseptic cases. *Arch Intern Med* 1989 ; 149 : 1581-1585.
9. **Steward NJ, Manzanares JB, Morrey BF.** Surgical treatment of aseptic olecranon bursitis. *J Shoulder Elbow Surg* 1997 ; 6 : 49-54.
10. **Tung TC, Wang KC, Fang CM, Lee C.** Reverse pedicled lateral arm flap for reconstruction of posterior soft-tissue defects of the elbow. *Ann Plast Surg* 1997 ; 38 : 635-641.
11. **Weinstein PS, Canoso JJ, Wohlgethan JR.** Long-term follow-up of corticosteroid injection for traumatic olecranon bursitis. *Ann Rheum Dis* 1984 ; 43 : 44-46.